



Indian J Ophthalmol. 2017 Oct; 65(10): 1025–1027.  
doi: 10.4103/ijo.IJO\_89\_17: 10.4103/ijo.IJO\_89\_17

PMCID: PMC5678305  
PMID: [29044077](https://pubmed.ncbi.nlm.nih.gov/29044077/)

## Ophthalmic manifestations in Rothmund–Thomson syndrome: Case report and review of literature

[J T Chinmayee](#), [G R Meghana](#), [R K Prathiba](#), and [T K Ramesh](#)

Department of Ophthalmology, Regional Institute of Ophthalmology, Bangalore Medical College and Research Institute, Minto Eye Hospital, Bengaluru, Karnataka, India

**Correspondence to:** Dr. G R Meghana, 225, A-1 Krishna Block, National Games Village, Koramangala, Bengaluru - 560 047, Karnataka, India. E-mail: [meghanagr23@gmail.com](mailto:meghanagr23@gmail.com)

Received 2017 Mar 22; Accepted 2017 Sep 14.

[Copyright](#) : © 2017 Indian Journal of Ophthalmology

This is an open access article distributed under the terms of the Creative Commons Attribution-NonCommercial-ShareAlike 3.0 License, which allows others to remix, tweak, and build upon the work non-commercially, as long as the author is credited and the new creations are licensed under the identical terms.

### Abstract

A 24-year-old male patient presented to us with diminution of vision in both eyes with watering and photophobia for the past 8 years. General physical examination showed short stature and poikiloderma. Ocular findings include photophobia with reflex tearing, dry eye, cicatricial ectropion, symblepharon approaching pupillary area of cornea, and multiple superficial punctate erosions on the cornea. Both eyelids showed scanty meibomian glands on infrared meibography. The rest of the anterior and posterior segment was normal. The patient was treated with topical lubricants which reduced photophobia and corneal erosions. He then underwent symblepharon release with buccal mucosal grafting, which improved ectropion. Patient improved symptomatically with reduction of photophobia and improvement in vision as well.

**Keywords:** Dry eye, meibography, meibomian gland dysfunction, Rothmund–Thomson syndrome

Rothmund–Thomson syndrome is a genodermatosis presenting with characteristic facial rash (poikiloderma) associated with short stature, sparse scalp hair, eyelashes and eyebrows, juvenile cataracts, skeletal abnormalities, premature aging, and predisposition to cancer. Till date, only 300 cases have been reported.[1] Facial erythema spreading to extremities but sparing the trunk is the diagnostic hallmark. Ocular manifestations include juvenile cataracts, but secondary effects due to skin cicatrization and meibomian gland atrophy-like dry eye cannot be neglected. Prompt and timely management can help restore vision and also reduce disturbing symptoms such as photophobia, thus significantly improving the patient's quality of life.

### Case Report

A 24-year-old male presented to the ophthalmology department with complaints of diminution of vision and photophobia. General physical examination showed short stature with a height of 148 cm, few hypopigmented and hyperpigmented atrophic skin patches, and intolerance to light [Fig. 1]. On ocular examination, best-corrected visual acuity in the right eye was 6/12 and left eye 6/9. Eyelid skin of both eyes showed hyperpigmented atrophy. Eyelid margin of right lower eyelid was everted due to the scarring of skin, leading to cicatricial ectropion. There was no loss of lashes. Conjunctiva of both eyes showed symblepharon [Fig. 2a]. On fluorescein staining of cornea, both eyes showed multiple staining superficial

punctuate erosions. Schirmer's test showed reduced tears in both eyes with strips wetting 8 mm in the right eye and 6 mm in the left eye [Fig. 3]. Lacrimal syringing was patent in both sides. On imaging eyelids for meibomian photography, both eyes showed nearly absent meibomian glands [Fig. 4].

Patient was treated with topical lubricants. Right eye symblepharon was released, and buccal mucosal graft was sutured. Skin contracture leading to ectropion was released with full-thickness skin graft taken from arm. Two weeks postoperatively, the patient had relief from photophobia. Vision improved to 6/9 parts in both eyes. The residual diminution of vision was probably due to irregular astigmatism which could not be corrected with spectacles. Corneas in both eyes were clear. Ectropion was corrected, and puncta were better approximated to the globe to drain the tear film [Fig. 2b]. Postoperative Schirmer's test results were 16 mm in the right eye and 14 mm in the left eye. Tear breakup time was 9 s in the right eye and 8 s in the left eye.

## Discussion

---

Rothmund–Thomson syndrome is a very rare genetic disease with no reliable data on its prevalence. To date, approximately 300 patients have been recorded in the medical literature.[1] Inheritance pattern is variable. A few studies show autosomal recessive inheritance,[2] mutations in RECQL4 gene,[3,4] and DNA repair disorders.[5] Clinical spectrum[6,7] is highly variable, which brings together patients with shared and unique developmental defects; thus those who display an atypical or borderline clinical presentation may be overlooked. The diagnostic hallmark is facial erythema, which spreads to the extremities but spares the trunk, which then develops poikiloderma, a skin condition with hypopigmentation, hyperpigmentation, telangiectasias, and atrophy. Two clinical subforms have been defined: RTSI, which has poikiloderma, ectodermal dysplasia, and juvenile cataracts; and RTSII which is characterized by poikiloderma, congenital bone defects, and an increased risk of cancers such as osteosarcoma and skin cancer.[8] Skeletal abnormalities include frontal bossing, saddle nose, and congenital radial ray defects. Gastrointestinal, respiratory, and hematological disorders have also been reported in a few patients.

Ocular manifestations have not been established completely. A few cases commonly have shown juvenile cataracts. There are case reports showing bilateral ocular hypertension,[9] bilateral iris dysgenesis,[10] retinal and corneal atrophies, and corneal opacities.[9,10] Another case report shows the involvement of ocular surface such as inflammatory conjunctival disease with fornix shortening, symblepharon, with sparse eyelashes.[11] Here it is a case presenting with severe meibomian gland dysfunction (MGD) associated with this syndrome leading to dry eye. Infrared (IR) meibography helps in diagnosing the cause for dry eye and photophobia in these cases, apart from cicatricial ectropion due to pathology of skin.

MGD is a chronic, diffuse abnormality of the meibomian glands, commonly characterized by terminal duct obstruction or changes in the glandular secretion. This may result in evaporative dry eye due to alteration in tear film, symptoms of eye irritation with apparent inflammation, and ocular surface disease. MGD results in stasis of meibum inside the glands, dilatation of the ductal system, and loss of glandular tissue (gland dropout). Meibography[12] is an *in vivo* technique used to visualize meibomian glands morphology. The structure of the meibomian glands, including the ducts and acini, are observed in the images generated using meibography. There are two principles. One is the transillumination of the everted eyelid which uses IR light; the other is direct illumination using slit lamp, called noncontact meibography. On IR meibography,[13] normal meibomian glands are hypoilluminant grape-like clusters while ducts and underlying tarsus are hyperilluminant. Ductal obstruction can be visualized as hyperkeratinized plugs at the orifices, stasis, and dilatation of glands. Gland atrophy can be seen as dropout areas. Abnormal meibomian glands show features consistent with histopathologic studies where ducts appear dilated and glands become enlarged, tortuous, and eventually dropout. IR meibography thus remains the mainstay of meibomian gland imaging studies because of its reliability and feasibility in producing high-quality gross images of the meibomian glands and enabling easy clinical analysis of gland function.

## Conclusion

---

Rothmund–Thomson syndrome is a rare genetic disorder presenting mainly with skin atrophic changes and systemic involvement. Ocular findings include juvenile cataract. Here is a rare case of syndrome showing MGD. Patient presented with photophobia and diminution of vision along with other features such as

poikiloderma and short stature. On thorough ocular evaluation, he was seen to have bilateral atrophy of meibomian glands, leading to dry eyes. Patient's symptoms improved on treatment with lubricants, further managed with symblepharon release and ectropion correction. Although rare, early diagnosis and prompt management of dry eye in this case significantly improved the patient's quality of life. A simple, noninvasive analysis of meibomian glands using IR meibography helped in diagnosing the cause for dry eye in this patient. Further management with buccal mucosal grafting after symblepharon release helped in maintaining tear film stability.

#### Declaration of patient consent

The authors certify that they have obtained all appropriate patient consent forms. In the form the patient(s) has/have given his/her/their consent for his/her/their images and other clinical information to be reported in the journal. The patients understand that their names and initials will not be published and due efforts will be made to conceal their identity, but anonymity cannot be guaranteed.

#### Financial support and sponsorship

Nil.

#### Conflicts of interest

There are no conflicts of interest.

#### References

---

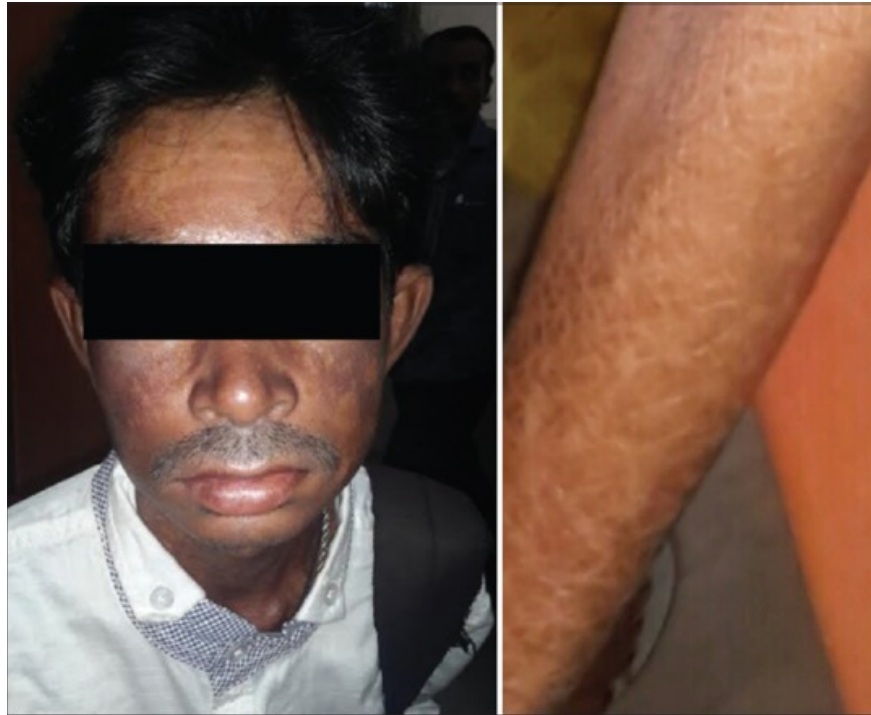1. Vennos EM, Collins M, James WD. Rothmund-thomson syndrome: Review of the world literature. *J Am Acad Dermatol.* 1992;27:750–62. [PubMed: 1430398]
2. Grant SG, Wenger SL, Latimer JJ, Thull D, Burke LW. Analysis of genomic instability using multiple assays in a patient with Rothmund-Thomson syndrome. *Clin Genet.* 2000;58:209–15. [PMCID: PMC4712958] [PubMed: 11076043]
3. Larizza L, Magnani I, Roversi G. Rothmund-thomson syndrome and RECQL4 defect: Splitting and lumping. *Cancer Lett.* 2006;232:107–20. [PubMed: 16271439]
4. Kitao S, Shimamoto A, Goto M, Miller RW, Smithson WA, Lindor NM, et al. Mutations in RECQL4 cause a subset of cases of Rothmund-Thomson syndrome. *Nat Genet.* 1999;22:82–4. [PubMed: 10319867]
5. Dollfus H, Porto F, Caussade P, Speeg-Schatz C, Sahel J, Grosshans E, et al. Ocular manifestations in the inherited DNA repair disorders. *Surv Ophthalmol.* 2003;48:107–22. [PubMed: 12559331]
6. Wang LL, Levy ML, Lewis RA, Chintagumpala MM, Lev D, Rogers M, et al. Clinical manifestations in a cohort of 41 Rothmund-Thomson syndrome patients. *Am J Med Genet.* 2001;102:11–7. [PubMed: 11471165]
7. Manavi S, Mahajan VK. Rothmund-Thomson syndrome. *Indian Dermatol Online J.* 2014;5:518–9. [PMCID: PMC4228658] [PubMed: 25396146]
8. Stinco G, Governatori G, Mattighello P, Patrone P. Multiple cutaneous neoplasms in a patient with Rothmund-Thomson syndrome: Case report and published work review. *J Dermatol.* 2008;35:154–61. [PubMed: 18346259]
9. Nathanson M, Dandine M, Gaudelus J, Mousset S, Lasry D, Perelman R, et al. Rothmund-Thomson syndrome with glaucoma. An endocrinologic study. *Ann Pediatr (Paris)* 1983;30:520–5. [PubMed: 6638800]
10. Mak RK, Griffiths WA, Mellerio JE. An unusual patient with Rothmund-Thomson syndrome, porokeratosis and bilateral iris dysgenesis. *Clin Exp Dermatol.* 2006;31:401–3. [PubMed: 16681588]
11. Miranda AF, Rivera-Monge MD, Farias CC. Rothmund-Thomson syndrome and ocular surface findings: Case reports and review of the literature. *Arq Bras Oftalmol.* 2016;79:186–8. [PubMed: 27463631]

12. Pult H, Nichols JJ. A review of meibography. *Optom Vis Sci.* 2012;89:E760–9. [PubMed: 22488268]
13. Robin JB, Jester JV, Nobe J, Nicolaidis N, Smith RE. *In vivo* transillumination biomicroscopy and photography of meibomian gland dysfunction. A clinical study. *Ophthalmology.* 1985;92:1423–6. [PubMed: 4069605]

### **Figures and Tables**

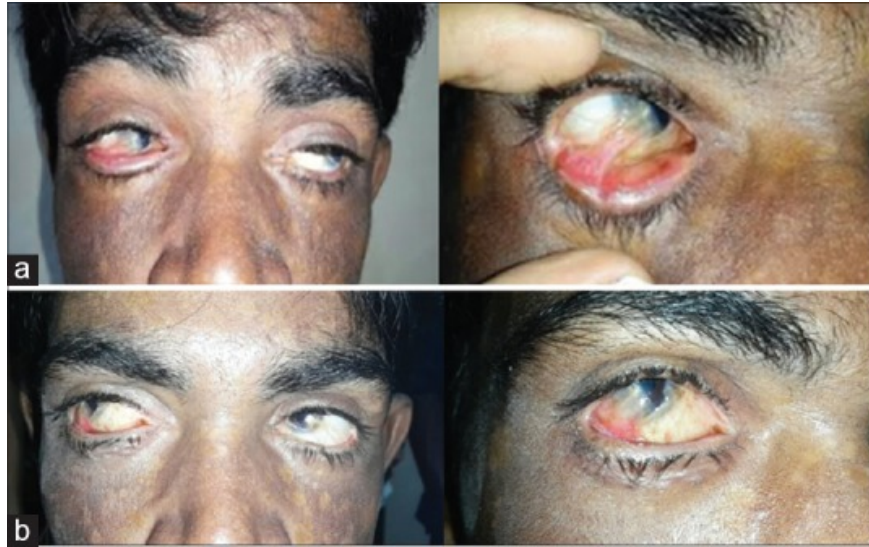---

**Figure 1**



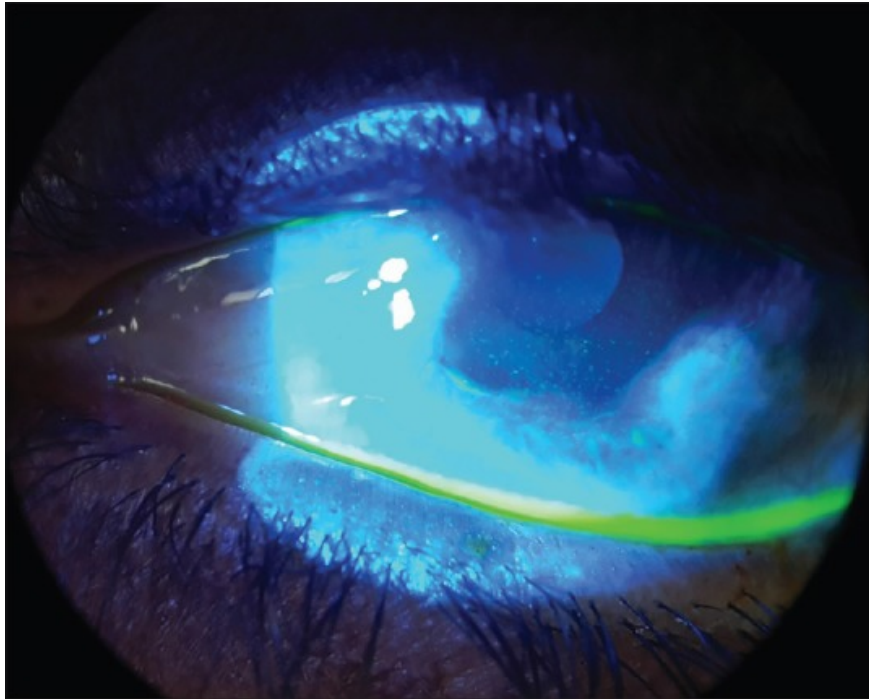
Hyperpigmented and hypopigmented skin lesions on patient's face and forearm

**Figure 2**



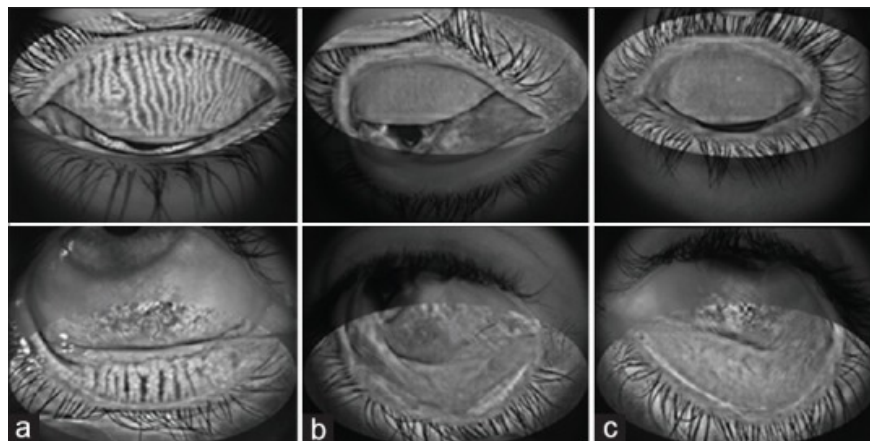
(a) Preoperative picture showing right eye lower eyelid ectropion and symblepharon. (b) Postoperative picture showing correction of ectropion and release of symblepharon

**Figure 3**



Fluorescein staining erosions on cornea of the left eyeInheritance

**Figure 4**



(a) Meibography of upper and lower eyelid of a normal patient showing meibomian glands. (b) Meibography of upper and lower eyelid of right eye of this patient showing absent meibomian glands. (c) Meibography of upper and lower eyelid of left eye of this patient showing absent meibomian glands

---

Articles from Indian Journal of Ophthalmology are provided here courtesy of **Wolters Kluwer -- Medknow Publications**