

# Plastic Surgery Considerations for Holoprosencephaly Patients

Jennifer M. Hendi, MPH\* Robert Nemerofsky, MD\* Cynthia Stolman, PhD† Mark S. Granick, MD\*

Newark, New Jersey

**Holoprosencephaly (HPE) is considered the leading abnormality of the brain and face in humans and is frequently associated with a wide spectrum of specific craniofacial anomalies including midline facial clefts, cyclopia and nasal irregularities. A standard course of treatment has not been developed and management is symptomatic and supportive. In this work, the authors discuss the wide-ranging spectrum of HPE and propose surgical guidelines to provide more uniform and appropriate care to patients suffering from holoprosencephaly. Assessment of the patient's brain abnormality is essential in determining the extent and benefit of surgical intervention. The authors discuss a median straight-line repair of the lip and repair of the anterior palate in a one-year old female and review the risks and benefits of surgery. Consistent with the ethical approach of surgical beneficence, the authors recommend intervention at the earliest possible time.**

*Key Words:* Holoprosencephaly, median oral facial cleft, surgical risks, beneficence, cleft lip repair

**H**oloprosencephaly was first described in 1963 and is considered the foremost abnormality of the brain and face in human beings, with an estimated birth prevalence of 5 to 12 per 100,000 live births.<sup>1</sup> Most cases are associated with severe brain malformations that are incompatible with life and often cause spontaneous intrauterine death. Less severely affected babies demonstrate a spectrum of defects and malformations of the brain and face. Holoprosencephaly is frequently associated with specific craniofacial anomalies, including midline facial clefts, cyclopia, and nasal irregularities.<sup>2</sup> Less severe malformations include facial defects that may affect the eyes, nose,

and upper lip, with normal or near-normal brain development. Some data indicate that patients with less severe manifestations of holoprosencephaly (i.e., semilobar and lobar) have survived into adulthood.<sup>3</sup> A standard course of treatment of holoprosencephaly has not been developed, and treatment is symptomatic and supportive.

Few guidelines have been described for surgical candidates, resulting in conflicting recommendations as well as ethical and practical dilemmas for surgeons. Given the prevalence and the wide-ranging manifestations of this disease, surgical guidelines should be established to provide more uniform and appropriate care to patients suffering from holoprosencephaly. Assessment of the patient's brain abnormality is essential in determining the extent and benefit of surgical intervention.

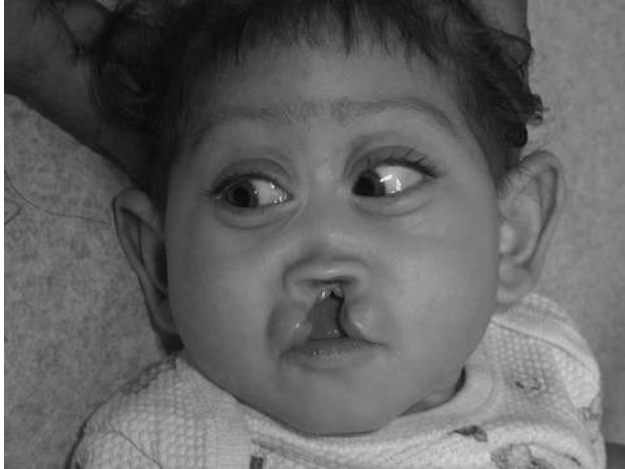## CASE REPORT

**A** primary pediatrician referred a 1-year-old female infant with semilobar holoprosencephaly to plastic surgery for cleft lip and palate repair (Fig 1). The patient was born at 32 weeks with semilobar holoprosencephaly (Fig 2), an absent septum pellucidum, a monoventricle, fused thalami, premaxillary agenesis with a midline cleft lip, bilateral optic nerve hypoplasia, and chromosome 8 deletion. The patient suffered from bilateral hearing loss, bilateral vision loss, dysphagia, hypotelorism, cerebral palsy, and seizures. Developmentally, the patient exhibited no verbal output, an inability to sit up, and difficulty in feeding. The mother was anxious to proceed with corrective surgery to make the child look more normal.

The patient was missing the prolabium and the anterior prolabial segment of the primary palate. The columella and nasal septum were also absent. It was elected to do a repair consisting of a median straight-line repair of the lip and repair of the anterior palate by sealing off the nasal floor and upper palate (Fig 3). The procedure used a simple straight-line repair. The columella and septal deficiencies were not addressed. There were no surgical complications of the surgery, and blood loss was minimal. The patient's hospital course was prolonged to deal with feeding problems, social issues, and seizure control. For 1

From the \*Division of Plastic Surgery, Department of Surgery, and †Division of Medical Ethics, Department of Pediatrics, New Jersey Medical School-University of Medicine and Dentistry of New Jersey, Newark, New Jersey.

Address correspondence to Dr Granick, 90 Bergen Street, DOC 7200, Newark, NJ 07103; e-mail: mgranickmd@umdnj.edu.

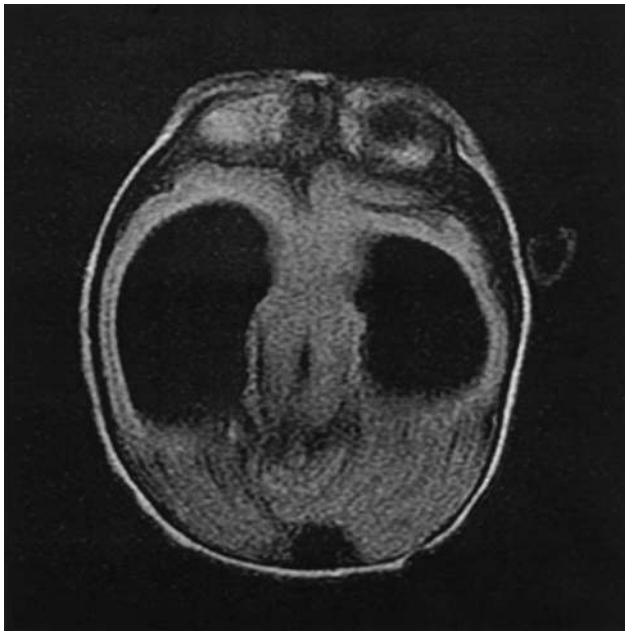


**Fig 1** A patient with semilobar holoprosencephaly and median oro-facial clefting.

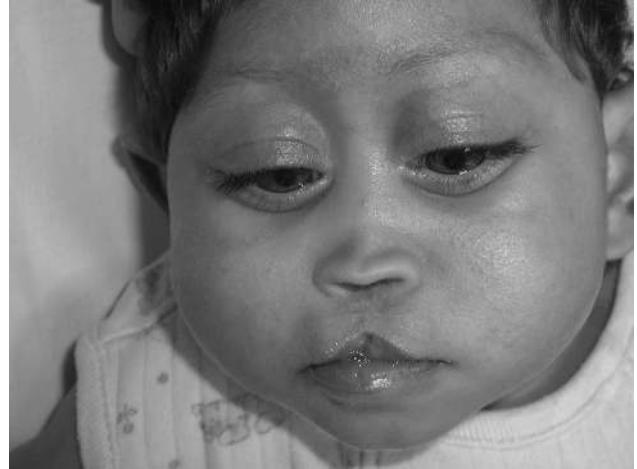year after surgery, the patient had a satisfactory esthetic appearance and was independently feeding but had made little additional functional gain. The mother was pleased with the outcome. The patient died 13 months after surgery.

#### DISCUSSION

**H**oloprosencephaly has been described as the most common major malformation of the brain and face in human beings. Various gradations of facial dysmorphism are commonly associated with holoprosencephaly, including cyclopia; ethmocephaly;



**Fig 2** CT scan demonstrating semilobar holoprosencephaly.



**Fig 3** The patient seen 12 months post-operatively.

cebocephaly; median cleft lip; and less severe facial dysmorphism such as hypotelorism or hypertelorism, lateral cleft lip, and/or iris coloboma. Associated anomalies include a single maxillary central incisor, absence of nasal septal cartilage, stenosis of the pyriform aperture, absence of the labial frenum, and absence of the philtral ridges.<sup>4</sup>

Holoprosencephaly is caused by teratogens and genetic factors. Maternal diabetes, alcohol, and retinoic acid are teratogens associated with holoprosencephaly; however, their significance has not been determined.<sup>5</sup> Evidence for genetic causes of holoprosencephaly comes from nonrandom chromosomal anomalies in regions that have been theorized to contain genes essential for normal forebrain development.<sup>5</sup> As many as 12 chromosomal regions have been implicated in the pathogenesis of holoprosencephaly.<sup>5</sup>

Three classifications of the disease currently exist. Alobar is considered the most severe manifestation, with patients exhibiting premaxillary agenesis and unilateral or bilateral cleft lip. Approximately half of the infants born with this form of the disease die before the age of 4 to 5 months, and 20% to 30% live for at least 1 year.<sup>3</sup> Semilobar holoprosencephaly results from less development of the anterior brain structures, with only partial separation into two hemispheres. In this form of the disease, the facial anomalies are mild or absent. Patients with lobar holoprosencephaly, considered the least severe expression of the disease, are less clinically abnormal than patients with alobar or semilobar holoprosencephaly. These patients may exhibit mild or moderate developmental delay, hypothalamic-pituitary dysfunction, or visual problems.<sup>6</sup>

Computed tomography findings of the brain

coupled with a period of observation can help to distinguish patients who will benefit from surgical intervention from those who are unlikely to thrive. The degree of treatment performed may be determined by the extent of the malformation. For instance, patients suffering from mild retardation may benefit most from repair of the false median cleft lip and palate, whereas a patient exhibiting normal or near-normal mentality with hypotelorism and nasomaxillary hypoplasia can be treated with simultaneous midface advancement, facial bipartition expansion, and nasal reconstruction.<sup>7</sup> A classification system proposed by Elias et al. identifies patient anomalies, with greater emphasis on the wide spectrum of midface hypoplasia and false median clefts that can exist in the absence of brain malformation.<sup>7</sup> The differentiation of these cases from true median clefts addresses the embryological origin of the deficit and, ultimately, more precise guidelines for the surgical management of these patients.

Among the dilemmas faced by treating physicians are the decision to operate, the timing, and the extent of surgery. Given the patient's limited likelihood of long-term survival, is it ethical to proceed with surgery at all? Ethical considerations in support of surgery are based on the principle of beneficence, "the physician's primary obligation to provide medical benefits."<sup>8</sup>

Beneficence places a positive duty on the part of the surgeon to intervene actively to further the patient's best interests. When parents indicate a desire for surgical repair, even with limited life expectancy and anesthesia obstacles, the physician is obligated to consider on balance the benefits of successful treatment against the risks of anesthesia and patient care without treatment. For a child with semilobar holoprosencephaly and limited survival beyond infancy, perhaps surgical intervention should be considered as soon as is practical. Sadvov et al. suggest that single-stage repair of the median cleft lip is appropriate in cases where there is some developmental progress shown, the patient is 1 year old, and/or the procedure will contribute to the infant's social acceptance.<sup>9</sup> Early surgical intervention offers an increased quality of life for a longer period, thereby enabling improved infant care (e.g., easier feeding, less frequent suctioning, hydration of the oral cavity) and socialization (e.g., bonding with the mother or caregiver, earlier discharge from the hospital, acceptance into the family and society). Surgery should be tailored to meet these limited objectives.

The child described lived for 25 months. If the surgery had been performed earlier, she would have enjoyed an improved appearance and enhanced fam-

ily interaction for a significant additional portion of her life. The surgical procedure was basic and addressed limited but important goals. Had the patient survived and the family requested repair of the columella, this could have been accomplished with local flaps.<sup>10</sup> Holoprosencephaly patients have a greater anesthesia risk because of their altered thermoregulatory ability, depressed seizure threshold, and alteration of upper airway anatomy as a result of median orofacial clefting.<sup>11</sup> Nevertheless, in a stable patient, anesthesia can be performed safely.

In summary, a holoprosencephaly patient presented with multiple congenital defects and physiological derangements. The decision to undertake reconstructive surgery requires an assessment of the patient's needs and specific anomalies. An assessment of altered respiratory, cardiac, and central nervous system function is required to ensure that patient health is not compromised. Although few guidelines have been established for selecting surgical candidates, we believe that surgery is warranted for patients with semilobar and lobar holoprosencephaly as soon as is practical. The goals of surgery are limited to improving function (i.e., feeding) and appearance to facilitate the integration of the patient into the family and society. Because the life expectancy of these patients may be short, surgical intervention performed as early as possible will provide the patients with improved quality of life for a significantly longer portion of their lives.

## REFERENCES

1. Kinsman SL, Plawner LL, Hahn JS. Holoprosencephaly: recent advances and new insights. *Curr Opin Neurol* 2000;13:127-132
2. Golden JA. Holoprosencephaly: a defect in brain patterning. *J Neuropathol Exp Neurol* 1998;57:991-997
3. Barr M, Jr, Cohen MM, Jr. Holoprosencephaly survival and performance. *Am J Med Genet (Semin Med Genet)* 1999;89:116-120
4. Muenke M, Cohen MM, Jr. Genetic approaches to understanding brain development: holoprosencephaly as a model. *Ment Retard Dev Disabil Res Rev* 2000;6:15-21
5. Roessler E, Muenke M. Holoprosencephaly: a paradigm for the complex genetics of brain development. *J Inherit Metab Dis* 1998;21:481-497
6. Simon EM, Barkovich AJ. Holoprosencephaly: new concepts. *Pediatr MR Neuroimaging* 2001;9:149-164
7. Elias DL, Kawamoto H, Jr, Wilson LF. Holoprosencephaly and midline facial anomalies: redefining classification and management. *Plast Reconstr Surg* 1992;90:951-958
8. Beauchamp TL, Childress JF. *Principles of Biomedical Ethics*. 3rd ed. New York: Oxford University Press, 1989:195, 210
9. Sadvov AM, Eppley BL, DeMyer W. Single stage repair of the median cleft lip deformity in holoprosencephaly. *J Craniomaxillofac Surg* 1989;17:363-366
10. Taub PJ, Bradley JP, Markowitz BL. Single-stage lip and nasal reconstruction in holoprosencephaly. *Plast Reconstr Surg* 2003;111:2324-2327
11. Katende RS, Herlich A. Anesthetic considerations in holoprosencephaly. *Anesth Analg* 1987;66:908-910