



Health Supervision for People With Achondroplasia

Julie Hoover-Fong, MD, PhD, FACMG,^a Charles I. Scott, MD, FAAP,^b Marilyn C. Jones, MD, FAAP,^c COMMITTEE ON GENETICS

Achondroplasia is the most common short-stature skeletal dysplasia, additionally marked by rhizomelia, macrocephaly, midface hypoplasia, and normal cognition. Potential medical complications associated with achondroplasia include lower extremity long bone bowing, middle-ear dysfunction, obstructive sleep apnea, and, more rarely, cervicomedullary compression, hydrocephalus, thoracolumbar kyphosis, and central sleep apnea. This is the second revision to the original 1995 health supervision guidance from the American Academy of Pediatrics for caring for patients with achondroplasia. Although many of the previously published recommendations remain appropriate for contemporary medical care, this document highlights interval advancements in the clinical methods available to monitor for complications associated with achondroplasia. This document is intended to provide guidance for health care providers to help identify individual patients at high risk of developing serious sequelae and to enable intervention before complications develop.

The original "Health Supervision for Children with Achondroplasia" policy from the American Academy of Pediatrics (AAP) in 1995 provided useful management recommendations to pediatricians caring for children with achondroplasia from birth through early adulthood.¹ The first revision in 2005 expanded the scope of the document to include new information about the molecular genetics of achondroplasia and improvements in anticipatory guidance in terms of prevention and treatment of complications of the condition.² The majority of the information provided in those documents remains pertinent and accurate in the current care of patients with achondroplasia. This revision highlights additional interval advancements in the clinical methods available to monitor for complications associated with achondroplasia, including adult health complications that may be rooted in childhood and should, therefore, be monitored and managed from birth. This document also incorporates a few of the more recent treatment options for achondroplasia to provide an informational core from which the general pediatrician can explore

abstract

^aGreenberg Center for Skeletal Dysplasias, McKusick-Nathans Department of Genetic Medicine, Johns Hopkins University School of Medicine, Baltimore, Maryland; ^bNemours/Alfred I. duPont Hospital for Children and Sidney Kimmel Medical College, Thomas Jefferson University, Wilmington, Delaware; and ^cDepartment of Pediatrics, University of California, San Diego and Rady Children's Hospital, San Diego, California

Drs Hoover-Fong and Scott wrote new content and edited content from the previous AAP statement and responded to reviews; Dr Jones provided editorial and content review, shepherded the document through multiple stakeholders review, and addressed specific concerns; and all authors approved the final manuscript as submitted.

Clinical reports from the American Academy of Pediatrics benefit from expertise and resources of liaisons and internal (AAP) and external reviewers. However, clinical reports from the American Academy of Pediatrics may not reflect the views of the liaisons or the organizations or government agencies that they represent.

The guidance in this report does not indicate an exclusive course of treatment or serve as a standard of medical care. Variations, taking into account individual circumstances, may be appropriate.

All clinical reports from the American Academy of Pediatrics automatically expire 5 years after publication unless reaffirmed, revised, or retired at or before that time.

This document is copyrighted and is property of the American Academy of Pediatrics and its Board of Directors. All authors have filed conflict of interest statements with the American Academy of Pediatrics. Any conflicts have been resolved through a process approved by the Board of Directors. The American Academy of Pediatrics has neither solicited nor accepted any commercial involvement in the development of the content of this publication.

DOI: <https://doi.org/10.1542/peds.2020-1010>

Address correspondence to Julie Hoover-Fong, MD, PhD. E-mail: jhoover2@jhmi.edu

PEDIATRICS (ISSN Numbers: Print, 0031-4005; Online, 1098-4275).

Copyright © 2020 by the American Academy of Pediatrics

To cite: Hoover-Fong J, Scott CI, Jones MC, AAP COMMITTEE ON GENETICS. Health Supervision for People With Achondroplasia. *Pediatrics*. 2020;145(6):e20201010

additional resources with patients. The authors recognize the audience for this document may have variable medical resources at their disposal to monitor and treat patients with achondroplasia. The intent of this consensus document is to provide guidance that may be adapted to each individual patient in his or her unique environment. Children and adolescents with achondroplasia should have care coordinated through a medical home; however, some of the surveillance and counseling suggested in this document will be provided by a number of specialists with expertise in the management of achondroplasia, if these individuals are available.

Achondroplasia is the most common condition associated with severe, disproportionate short stature, with an estimated birth incidence of 1 in 10 000 to 1 in 30 000.^{3,4} There is no recognized ethnic or sex predisposition. The diagnosis can usually be made on the basis of clinical characteristics and specific features on radiographs, including a square shape of the pelvis with a small sacroscliotic notch, short pedicles of the vertebrae with interpedicular narrowing from the lower thoracic through lumbar region, rhizomelic (proximal) shortening of the long bones, proximal femoral radiolucency, and a characteristic chevron shape of the distal femoral epiphyses. Other clinical features include short stature, macrocephaly (absolute and relative), trident configuration of the hands, and long, near-normal-length trunk.

Achondroplasia is an autosomal dominant disorder, meaning a person with achondroplasia has a 50% chance of passing the condition on to each of his or her offspring regardless of the sex of the parent or child, provided the other parent is unaffected. Approximately 75% to 80% of patients with achondroplasia are born to average-stature parents, representing a new dominant

mutation in the fibroblast growth factor receptor type 3 (*FGFR3*) gene in that affected individual.^{3,5,6} Because virtually all of the causal mutations occur at exactly the same nucleotide within the gene,⁶ genetic testing for achondroplasia is straightforward. It is not necessary to perform molecular testing in every child with a clinical diagnosis of achondroplasia. However, *FGFR3* testing should be considered when a confirmed achondroplasia diagnosis is needed. For example, infants or children with an atypical achondroplasia presentation may have a second genetic condition.⁷ Such children also should be referred for clinical genetics evaluation. Different mutations in the *FGFR3* gene can also cause 2 other short stature dysplasias: hypochondroplasia and thanatophoric dysplasia. A child with hypochondroplasia has the same clinical features as one with achondroplasia, as listed above, but milder overall. Growth hormone therapy may be considered as a treatment option for those with hypochondroplasia, but it has not been shown to be effective in patients with achondroplasia.^{8–11} Thanatophoric dysplasia usually can be distinguished from achondroplasia and hypochondroplasia because severe thoracic and lung hypoplasia are expected to be lethal in the pre- or early postnatal period in the former.¹² Rare exceptions of a patient with thanatophoric dysplasia surviving are reported but only with aggressive measures of resuscitation at delivery and significant respiratory support thereafter.^{13,14} Age-specific recommendations pertaining to genetic counseling and testing are also included in each age category discussed later in this report.

A great deal is known about the natural history of achondroplasia that can be shared with the family.^{4,15} The average adult height in achondroplasia is approximately 120

to 135 cm (4–4.5 ft) (Fig 1).¹⁶ The most common complication, occurring in adulthood, is related to lumbosacral spinal stenosis with compression of the spinal cord or nerve roots.^{17–19} This complication is usually treatable by surgical decompression, with less sequelae if treated at an early stage. Most children with achondroplasia do well. However, children affected with achondroplasia commonly have delayed motor milestones (Fig 2),^{20–22} otitis media, and bowing of the lower legs.²³ Less commonly, infants and children may have serious health consequences related to craniocervical junction compression because of a relatively small foramen magnum, hydrocephalus, upper-airway obstruction, or thoracolumbar kyphosis. Although they are less common, anticipatory care should include identifying children at highest risk and intervening to prevent potentially serious sequelae. Most individuals with achondroplasia are of normal intelligence and are able to lead independent and productive lives.²⁴ Because of their disproportionate short stature, however, a number of psychosocial problems can arise.²⁵ Chronic pain, a problem that may begin in childhood and magnify into adulthood without intervention, may be playing a larger role in overall life satisfaction and coping than has been previously appreciated.²⁶ Further investigation is needed to better understand the temporal relationship among pain, function, and medical or surgical treatment to allow for the highest quality of life possible. Families can benefit from anticipatory guidance and the opportunity to learn from other families with children of disproportionate short stature. The consensus-based guidance in this report is designed to help the pediatrician care for children with achondroplasia and their families. Issues that need to be addressed at various ages are outlined in Table 1.

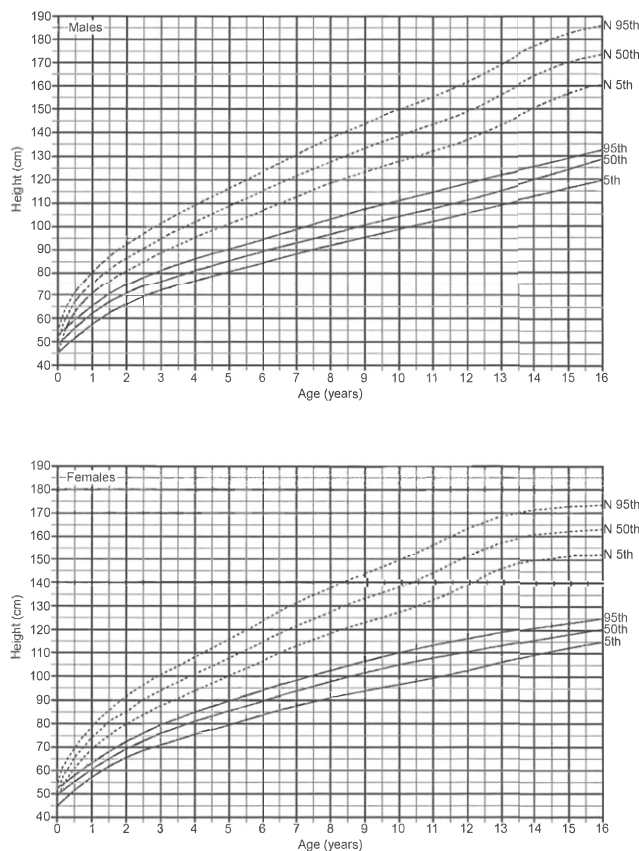


FIGURE 1

Fifth, 50th, and 95th percentiles for height for children with achondroplasia (solid lines) compared with height growth curves for the general population (dotted lines), based on 1955 observations from 162 boys and 131 girls with achondroplasia. Adapted from Hoover-Fong JE, Schulze KJ, McGready J, Barnes H, Scott CI. Age-appropriate body mass index in children with achondroplasia: interpretation in relation to indexes of height. *Am J Clin Nutr*. 2008;88(2):364–371. Curves for the US population are from Kuczmarski RJ, Ogden CL, Guo SS, et al. 2000 *CDC Growth Charts for the United States: Methods and Development*. Hyattsville, MD: National Center for Health Statistics; 2002. Illustration is from *Growth References*. Third edition. 2011. Permission for use was granted by the Greenwood Genetic Center.

It should be noted that these suggestions are not appropriate for other skeletal dysplasia diagnoses because each type has its own natural history, complications, and specific management recommendations. The most recent nosology of genetic skeletal disorders includes 436 different disorders with primary bone manifestations, and more than half of these are considered to be skeletal dysplasias.²⁷ Because of the vast range of medical considerations for patients with these diagnoses, it is important that pediatricians and their

patients partner with a physician with special experience and expertise concerning skeletal dysplasias, particularly achondroplasia, early in the child's life. This report provides generally applicable suggestions that must be tailored to a particular child's condition and needs. For reference, the American Board of Medical Genetics and Genomics has an online resource to search for a certified geneticist throughout the United States and in several countries around the world (<http://www.abmg.org/pages/searchmem.shtml>).²⁸

Similarly, the Little People of America, Inc, the largest US patient support group for short-stature skeletal dysplasia patients and their families, may be a suitable resource for information for medical providers and families (<http://www.lpaonline.org/>).²⁹

In addition to the age group-specific guidance presented in this report, 3 topics often arise in early discussions with families about potential treatment of achondroplasia: growth hormone therapy, surgical limb lengthening, and, more recently, drug trials for new medications to alter bone morphology and growth. The following is not meant to be an exhaustive review of these issues but rather a brief foundation on which further discussions can be built.

First, in reference to supplemental growth hormone treatment, there have been longitudinal studies of relatively small groups of patients with achondroplasia treated with growth hormone of various doses and durations.^{8–11} A recent meta-analysis of 12 trials showed a clinically insignificant increase of -5 to -4 SD below the mean when children with achondroplasia were treated with growth hormone.¹⁰ Some authors also suggest that the rapid (although unsustained) linear growth predisposes to worsening scoliosis and kyphosis in these patients.¹⁰ In contrast, a few studies have shown a greater adult height in patients with hypochondroplasia treated with growth hormone therapy.⁸ As noted previously, genetic testing would be useful to differentiate these 2 conditions before embarking on a long and expensive course of supplemental growth hormone treatment.

With respect to limb lengthening, there is a body of medical literature addressing different surgical methods of lengthening, complications of the procedures,³⁰ perspectives on lengthening the upper extremities,³¹

Developmental Screening Tests in Achondroplasia

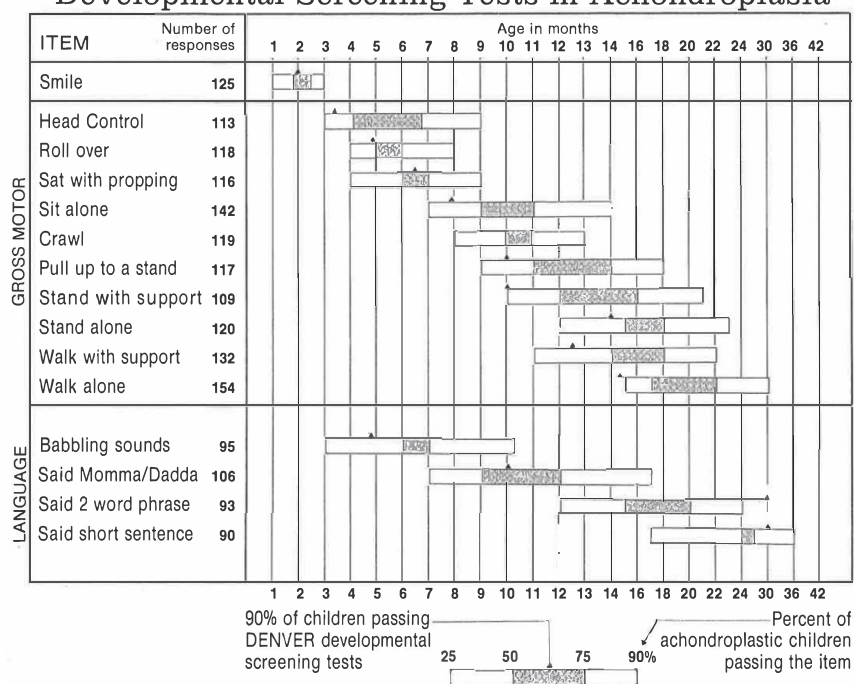


FIGURE 2

Developmental screening tests in achondroplasia, based on questionnaire information from 197 individuals. The bar scale reveals the percentage of children with achondroplasia passing the item. The black triangle on top of the bar reveals the age at which 90% of normal children pass the same item. Illustration is from *Growth References*. Third edition. 2011. Permission for use was granted by the Greenwood Genetic Center.

and reviews of the entire process.³² Opinions about the use and success of surgical limb lengthening vary widely. Regardless of a patient or family's position, however, it is important for the pediatrician to be aware of a few key issues surrounding surgical limb lengthening. Limb lengthening is a long and costly process, associated with significant physical pain for the young patient. The age at which this procedure is recommended varies among surgeons, but implementation before epiphyseal closure is the norm, with many encouraging commencement at younger than 10 years. Medical decision-making in this age group rests with the parent or legal representative who could make a decision without involving the child in the discussion. Per AAP policy on informed consent,³³ it is highly desired that the child and parents engage in discussion about such elective procedures before a decision

is made. Finally, this procedure is associated with complications. Therefore, it is critical that the surgical team is readily available to manage short- and long-term complications associated with limb lengthening.

The last novel issue to address is the pharmaceuticals under development to potentially increase long bone growth and/or ameliorate the skeletal complications of this condition. There are several compounds currently at various stages of development with different targets and mechanisms.^{34,35} More information about these trials can be found online at <https://clinicaltrials.gov>. The trial process often takes several years, and final approval is required from the US Food and Drug Administration for a new drug to become available through a prescription. For families contemplating enrollment of their

child with achondroplasia in one of these trials, it is important to know that a physician conducting a clinical trial should have sufficient experience with the condition to differentiate complications (or a response) to a research pharmaceutical from the natural history of that condition.

THE PRENATAL VISIT

Pediatricians may be asked to counsel expectant parents whose fetus has achondroplasia or is suspected to have achondroplasia because of recognition on ultrasonography of disproportionate small stature and relative large head size. In some situations, the pediatrician may be the primary resource for counseling the family. At other times, counseling may already have been provided to the family by a clinical geneticist, genetic counselor, or maternal-fetal medicine specialist. Because of a previous relationship with the family, however, the pediatrician could be called on to review this information and assist the family in the decision-making process.

The diagnosis of achondroplasia in the fetus is made most often with certainty when one or both biological parents have this condition. In this circumstance, the parents are usually (but not always) knowledgeable about the disorder, the inheritance, and the prognosis for the offspring. However, specific inquiry about the presence of a short stature diagnosis in both parents is recommended when only the mother is present for the clinical visit and may not spontaneously offer that her partner also has short stature. Additionally, it is important to establish clearly the specific short stature diagnosis in both parents. If both parents have achondroplasia, for example, review of the potential outcome of this and each future pregnancy (25% average stature, 50% achondroplasia, 25% homozygous or "double dominant" and, therefore, lethal) is

TABLE 1 Health Supervision for People With Achondroplasia

| | Prepregnancy and Short-Stature Parents | Prenatal and Short- and Average-Stature Parents | Birth to 1 mo | 1 mo to 1 y | 1–5 y | 5–13 y | 13–21 y | Adult |
|---|---|--|------------------|-----------------------|-------------------|-------------------|-------------------|-------------------|
| Diagnosis | | | | | | | | |
| Physical examination | X | X of fetus | X | X | — | — | — | — |
| Imaging | X radiographs | X ultrasonography of fetus | X | — | — | — | — | — |
| Molecular testing | X | X of fetus | X | — | — | — | — | X |
| Genetic counseling | | | | | | | | |
| Review natural history | X of potential offspring | X | X | X | X | X | X | X |
| Recurrence risk and genetics | X | X | X | X | X | X | X | X |
| Delivery mode and location | X | X | — | — | — | — | — | X |
| Support group(s), family support | X | X | X | X | X | X | X | X |
| Desired pregnancy? | — | X | X | — | — | — | — | X |
| Medical evaluation | | | | | | | | |
| Growth (height or length, weight, occipitofrontal circumference) | — | X | X | X | X | X | X | X |
| Physical examination | — | — | X | X | X | X | X | X |
| Neurologic examination | — | — | X | X | X | X | X | X |
| Development | — | — | X | X | X | X | — | — |
| Neuroimaging | — | — | X | X if new diagnosis | X as indicated | X as indicated | X as indicated | X as indicated |
| Polysomnography | — | — | X | X if new diagnosis | X as indicated | X as indicated | X as indicated | X as indicated |
| Hearing assessment | — | — | X | X | X | X | X | X |
| Radiography for kyphosis, genu varus, bowing | — | — | — | X | X as indicated | X as indicated | X as indicated | X as indicated |
| Anticipation or guidance | | | | | | | | |
| Warning signs of severe complications | — | — | X | X | X | X | X | X |
| Car seats | — | X for hospital discharge | X | X | X | X | — | — |
| Achondroplasia-specific development | — | — | X | X | X | — | X | — |
| Jugular bulb dehiscence warning | — | — | — | X | X | X | X | X |
| Supplemental security income inclusion | — | — | — | X | X | X | X | X |
| Accommodations | — | — | — | — | X | X | X | X |
| Obesity, exercise, diet | — | — | — | — | X | X | X | X |
| Driving | — | — | — | — | — | — | X | X |
| College | — | — | — | — | — | — | X | X |
| Job training | — | — | — | — | — | — | X | X |

straightforward. In the situation in which one parent has achondroplasia but the partner has a different dysplasia diagnosis, the recurrence risk discussion must be tailored to their specific diagnoses and associated inheritance. Often, there is little medical literature available to reference and anticipate the medical course of a compound heterozygous offspring. Ideally, such genetic counseling should be provided by genetic medicine professionals, such

as genetic counselors and/or clinical geneticists.

Most often, the scenario presents when the diagnosis of achondroplasia is suspected late in gestation on the basis of long bone foreshortening incidentally discovered via ultrasonography in the fetus of an average-stature couple. It is rare for ultrasonographic features of achondroplasia to be noticeable before 26 weeks' gestation, although Boulet et al³⁶ reported a new prenatal

ultrasonographic diagnostic sign for achondroplasia they named the "collar hoop" sign, which may be evident earlier. If long bone anomalies and/or disproportion are appreciated earlier in gestation, a skeletal dysplasia more severe than achondroplasia is likely.³⁷ Higher-level ultrasonography and examination for other diagnostic features are then required. Confirmation of diagnosis on the basis of ultrasonographic features

characteristic of achondroplasia can be provided by molecular testing (*FGFR3* mutational testing) of prenatal specimens (chorionic villus sampling at 11–13 weeks' gestation or amniocentesis after 15 weeks' gestation). Typically, this would be performed at a specialized prenatal center. If no such confirmation for achondroplasia (or any other dysplasia) has been completed, caution should be exercised when counseling the family.

Prenatal consultation involving a couple in which one or both carry a skeletal dysplasia diagnosis and are seeking genetic counseling and anticipatory guidance is best arranged before pregnancy.³⁸ Typically, this visit would be with a medical geneticist or genetic counselor. In this scenario, there is ample time to confirm the parental dysplasia diagnoses and evaluate the woman (if she is short stature) for neuraxial complications or previous surgical procedures, which could influence anesthesia options for delivery (ie, general versus spinal or epidural).

Depending on the prenatal situation, the pediatrician may consider the following steps as needed:

1. Review, confirm, and demonstrate laboratory or imaging studies leading to the diagnosis.
2. Explain the mechanisms for occurrence of achondroplasia in the fetus and the recurrence risk for the family, depending on the presence of a dysplasia in both, one, or neither of the parents.
3. Explain that up to 80% of patients with achondroplasia are born to average-stature parents. In these affected children, their achondroplasia occurred because of a spontaneous mutation in the *FGFR3* gene. In this situation, recurrence risk is empirically approximately 1% for future pregnancies for this specific

couple because of the possibility of gonadal mosaicism.

4. Review the natural history and manifestations of achondroplasia, including variability.^{4,15}
5. Discuss additional studies that could be performed in the newborn period to confirm the diagnosis (eg, blood test for mutation in *FGFR3*, radiographs to review for achondroplasia-specific features). If miscarriage, stillbirth, or termination occurs, confirmatory testing is important if the woman or family desires optimal genetic counseling. If specific molecular testing cannot be offered immediately, try to secure a blood or tissue sample for future testing.
6. Review currently available treatments and interventions, including efficacy, complications, adverse effects, costs, and other burdens of these treatments. Discuss possible future treatments and interventions. Please see the medical evaluation and anticipatory guidance discussions in the sections on health supervision for children ages 1 month to 1 year, 1 to 5 years, and 5 to 13 years.
7. Explore the options available to the family for the management and rearing of the child by using a nondirective approach. In cases of early prenatal diagnosis, these options may include discussion of pregnancy termination, continuation of pregnancy and rearing of the child at home, foster care, or adoption. If adoption is planned, the Little People of America, Inc, has adoption resources available (<http://www.lpaonline.org/adoption>).³⁹
8. If the pregnant woman carries the diagnosis of achondroplasia, inform her that a cesarean

delivery will be necessary because of the characteristic small pelvis and cephalopelvic disproportion (regardless of whether the fetus is average stature or has achondroplasia also and, therefore, macrocephaly). Prenatal consultation with a high-risk maternal or fetal medicine specialist is recommended to investigate whether general anesthesia or spinal or epidural anesthesia will be needed for delivery. In an average-stature pregnant woman carrying a fetus with achondroplasia, a cesarean delivery may also, but not always, be necessary because of fetal macrocephaly.

9. Establish where the infant with the suspected (or possible) skeletal dysplasia diagnosis will be delivered. Pediatric services to manage potential medical complications at or shortly after delivery may be necessary and are not available at all hospitals.
10. When both parents are of disproportionate short stature, assess the possibility of the fetus inheriting both conditions. Infants with homozygous achondroplasia usually are stillborn or die shortly after birth.⁴⁰
11. Be aware that many of these discussions will be coordinated with the prenatal team, including a medical geneticist, genetic counselor, and/or maternal-fetal medicine specialist. The importance of a knowledgeable medical home for the expected infant should be reviewed.

HEALTH SUPERVISION FROM BIRTH TO 1 MONTH OF AGE: NEWBORN INFANTS

Diagnosis, Genetic Counseling

1. Confirm the diagnosis by radiographic studies in the newborn period. External physical

features may not be highly obvious for achondroplasia. Radiographs should include anteroposterior and lateral skull, anteroposterior and lateral cervical spine, anteroposterior and lateral chest and abdomen with pelvis and upper femurs, anteroposterior of each upper and lower extremity long bone, and anteroposterior of hands and feet separate from long bones. Molecular studies may be pursued if desired.

2. Discuss genetics of achondroplasia with the parents, including the following:

- a. Autosomal dominant inheritance: Any person with achondroplasia will have a 50% chance of passing this condition on to each offspring, regardless of the sex of the parent and child.
- b. Approximately 80% of children born with achondroplasia represent spontaneous new mutations in the *FGFR3* gene.
- c. Germ-line mosaicism (in which some germ cells are derived from a normal cell line and some are from a cell line with a mutation, also known as gonadal mosaicism) has been reported in families with achondroplasia. This means that 2 average-stature parents have had more than 1 child with achondroplasia attributable to gonadal mosaicism. The recurrence risk of achondroplasia in sporadic cases via gonadal mosaicism is approximately 1%.⁴¹⁻⁴³
- d. Recurrence risk when both parents have a skeletal dysplasia diagnosis should also be reviewed.

3. Recognize the potential psychosocial implications for both parent and child related to short stature.

- a. Refer the family to a support group, such as Little People of America.³⁹
- b. If parents do not wish to join a group, offer meeting individually with other affected individuals or parents.
- c. Discuss how they will tell their family and friends about their child's diagnosis.
- d. Refer to other support resources, such as clergy, social workers, and psychologists.
- e. Remind parents that most people with achondroplasia lead productive, independent lives.
- f. Supply the parents with educational books and pamphlets (<http://www.lpaonline.org/>).²⁹
- g. Discuss the realistic functional difficulties for affected individuals.

Medical Evaluation

1. Measure and plot total body length, weight, and occipitofrontal circumference on achondroplasia-specific growth charts (Figs 1 and 3-5)^{16,22,44} at birth and every health supervision visit. Review these growth parameters with both parents.
2. Use achondroplasia-specific developmental charts at every health supervision visit (Fig 2).^{20,22}
3. Assess every infant with achondroplasia for craniocervical junction risks as soon as the diagnosis is recognized⁴⁵ via the following:
 - a. Careful neurologic history and examination. This includes inquiry about feeding ability, choking or gagging with feeding, prolonged apnea while sleeping, cyanosis of lips or mouth with feeding or sleeping, symmetry of limb movements,

and axial and appendicular tone.

- b. Polysomnography (overnight sleep study, evaluated by a pediatric pulmonologist, including end tidal carbon dioxide in addition to standard measures of apnea, hypopnea, saturation) to assess for unusual central apnea.
 - c. Neuroimaging, provided it can be performed safely by appropriate medical personnel if sedation or anesthesia is required to obtain images. If abnormalities suggestive of craniocervical compromise are detected in the medical history, neurologic examination, or sleep study, then neuroimaging is indicated. Neuroimaging should not be used in isolation to determine when or whether surgery is indicated.
4. Consider the pros and cons of the neuroimaging options:
- a. Computed tomography with thin cuts and bone windows:
 - i. Can compare foramen magnum size with published achondroplasia norms.^{46,47}
 - ii. May be possible without sedation.
 - iii. Does not provide adequate images of brainstem and upper cervical cord to determine if there is neural compromise, signaling change.
 - b. MRI:
 - i. Provides direct assessment of the brainstem and upper cervical spinal cord, but no standards for estimation of foraminal size by MRI are currently available.
 - ii. May require general anesthesia if fast MRI protocol is not used or available. General anesthesia should only be

performed in a clinical setting in which a pediatric anesthesiologist, nurse anesthetist, or other airway specialist is present to manage the procedure. Often, a newborn infant can be wrapped and scanned while asleep without sedation or anesthesia, particularly when a faster magnetic resonance scanner is available.

- iii. Evidence that flexion or extension of the cervical spine during MRI may reveal dynamic cord compression and alteration of cerebrospinal fluid (CSF) flow in achondroplasia, which is a better indicator of the need for surgical intervention.^{48,49}
5. Refer in a timely manner to experienced neurosurgical specialist if any of the following are detected during the aforementioned craniocervical junction assessment:
 - a. Abnormal neurologic examination marked by hypotonia or “floppiness,” weakness, sustained lower extremity clonus, asymmetric reflexes, or choking or gagging with eating.
 - b. Poor weight gain on achondroplasia-specific growth charts, especially if caloric intake and/or infant feeding is sufficient.
 - c. Sleep study showing hypoxemic episodes with oxygen saturation <85% and/or central apnea beyond that expected in an average-stature, healthy newborn infant.⁵⁰
 - d. Imaging showing marked smaller foramen magnum size, substantial deformation of the upper cervical spinal cord, or lack of CSF around the spinal cord.
6. Establish care with a pediatric orthopedist to monitor the spine.
7. Confirm newborn screening hearing result and follow-up failed screening results with formal audiology assessment.

Anticipatory Guidance

1. Discuss the following possible severe medical complications and methods of prevention:
 - a. Unexpected infant death occurs in 2% to 5% of all infants with achondroplasia^{50,51} if aggressive, early assessments are not pursued to detect central apnea resulting from compression of the brainstem and arteries at the level of the foramen magnum.
 - b. The universally small foramen magnum may result in a high cervical myelopathy,^{52,53} also detectable by the aforementioned early assessments.
 - c. Macrocephaly with excessive extra-axial fluid and asymptomatic ventriculomegaly is a normal feature of achondroplasia⁵⁴ but may be complicated by hydrocephalus.
 - i. Should head circumference increase unexpectedly on an achondroplasia-specific curve, the fontanelle bulge or become hard to palpation, or lethargy, irritability, poor weight gain, or marked developmental delay occur, the imaging and potential referral to a neurosurgical specialist is indicated.
 - ii. Benign extra-axial fluid and asymptomatic ventriculomegaly visualized by MRI should not be misinterpreted as indicative of need for shunt placement.

d. Restrictive pulmonary disease occurs in less than 5% of children with achondroplasia who are younger than 3 years.⁵⁵ Living at high elevation may exacerbate pulmonary complications as in average-stature individuals. Obstructive pulmonary disease is much more common and warrants systematic assessment.^{15,56,57}

2. Be aware that most infants with achondroplasia develop thoracolumbar kyphosis. More severe kyphosis is associated with unsupported sitting before there is adequate trunk muscle strength and tone.^{58,59} Borkhuu et al⁶⁰ observed developmental delays in motor skill acquisition (compared with other children with achondroplasia) to be highly associated with progression of thoracolumbar kyphosis.⁶¹
 - a. Back support should be provided during bottle and/or breastfeeding.
 - b. Unsupported sitting and devices that cause curved sitting or “C sitting,” such as “umbrella-style” strollers and soft canvas seats, should be avoided during the first year of life.
 - c. Care with a pediatric orthopedist should be established to monitor the spine.
3. Be aware that the common complication of spinal stenosis rarely occurs in childhood but manifests in older individuals with numbness, weakness, and altered deep tendon reflexes.⁵² Severe thoracolumbar kyphosis can greatly exacerbate spinal stenosis; thus, the recommendation is to avoid unsupported sitting before there

ACHONDROPLASIA – WEIGHT, 0-36 MONTHS

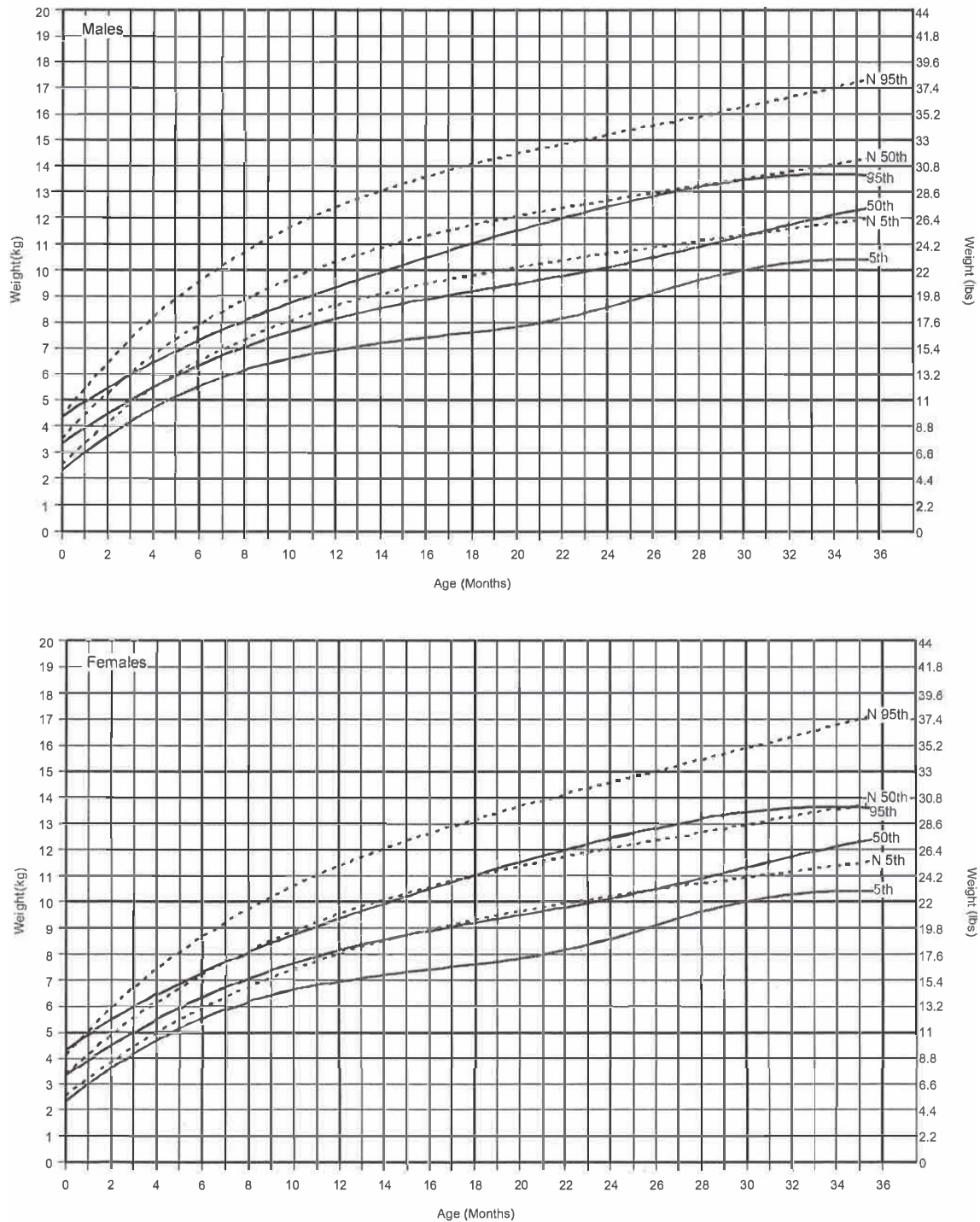


FIGURE 3

Fifth, 50th, and 95th percentiles for weight for boys (top) and girls (bottom) 0 to 36 months of age with achondroplasia (solid lines) compared with those of the general population (dotted lines), based on 1853 observations from 155 boys and 128 girls with achondroplasia. Adapted from Hoover-Fong JE, Schulze KJ, McGready J, Barnes H, Scott CI. Age-appropriate body mass index in children with achondroplasia: interpretation in relation to indexes of height. *Am J Clin Nutr*. 2008;88(2):364–371. Curves for the US population are from Kuczmarski RJ, Ogden CL, Guo SS, et al. *2000 CDC Growth Charts for the United States: Methods and Development*. Hyattsville, MD: National Center for Health Statistics; 2002. Illustration is from *Growth References*. Third edition. 2011. Permission for use was granted by the Greenwood Genetic Center.

ACHONDROPLASIA – WEIGHT, 2-16 YEARS

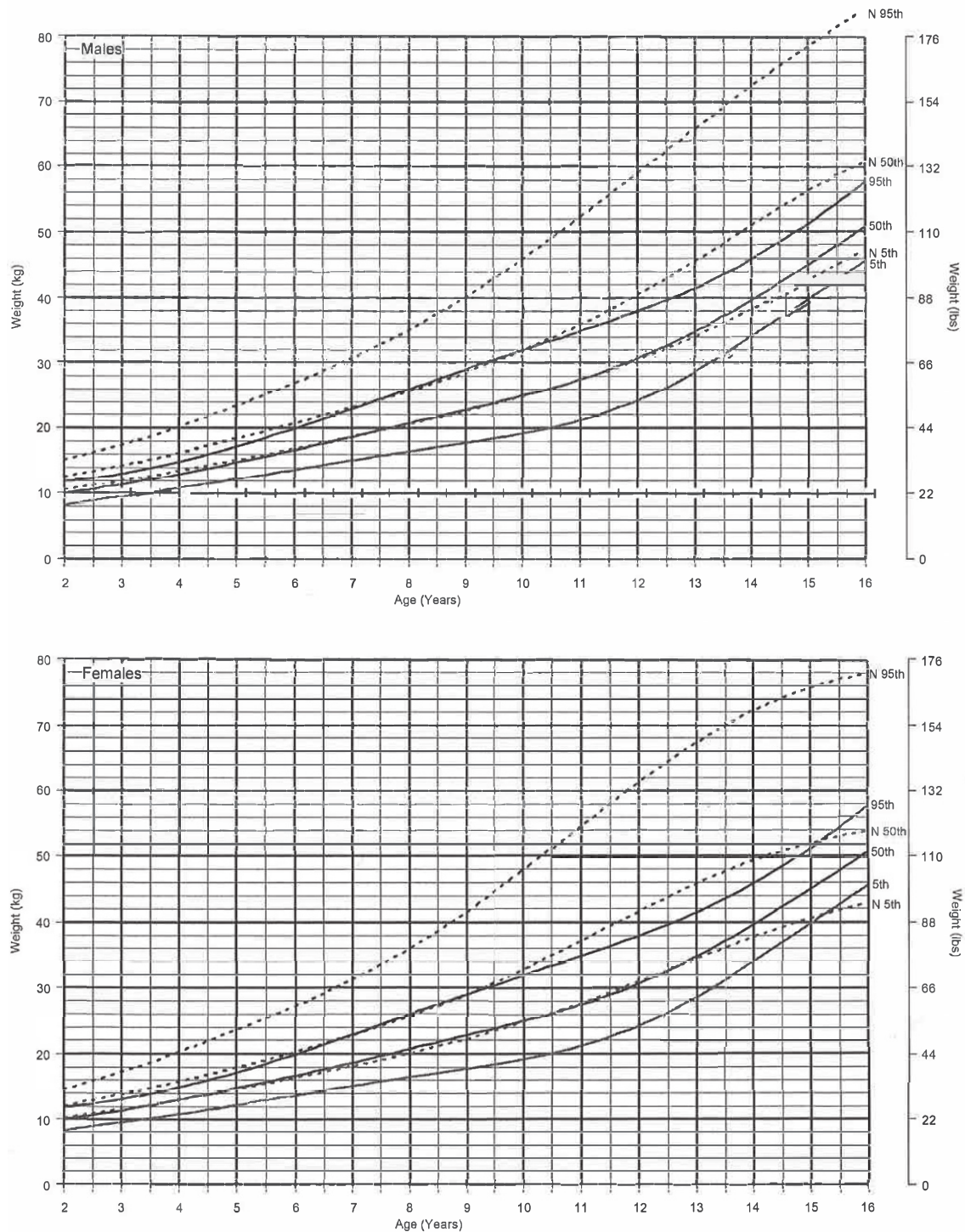


FIGURE 4

Fifth, 50th, and 95th percentiles for weight for boys (top) and girls (bottom) 2 to 16 years of age with achondroplasia (solid lines) compared with those of the general population (dotted lines), based on 1853 observations from 155 boys and 128 girls with achondroplasia. Adapted from Hoover-Fong JE, Schulze KJ, McGready J, Barnes H, Scott CI. Age-appropriate body mass index in children with achondroplasia: interpretation in relation to indexes of height. *Am J Clin Nutr*. 2008;88(2):364–371. Curves for the US population are from Kuczmarski RJ, Ogden CL, Guo SS, et al. *2000 CDC Growth Charts for the United States: Methods and Development*. Hyattsville, MD: National Center for Health Statistics; 2002. Illustration is from *Growth References*. Third edition. 2011. Permission for use was granted by the Greenwood Genetic Center.

ACHONDROPLASIA – HEAD CIRCUMFERENCE

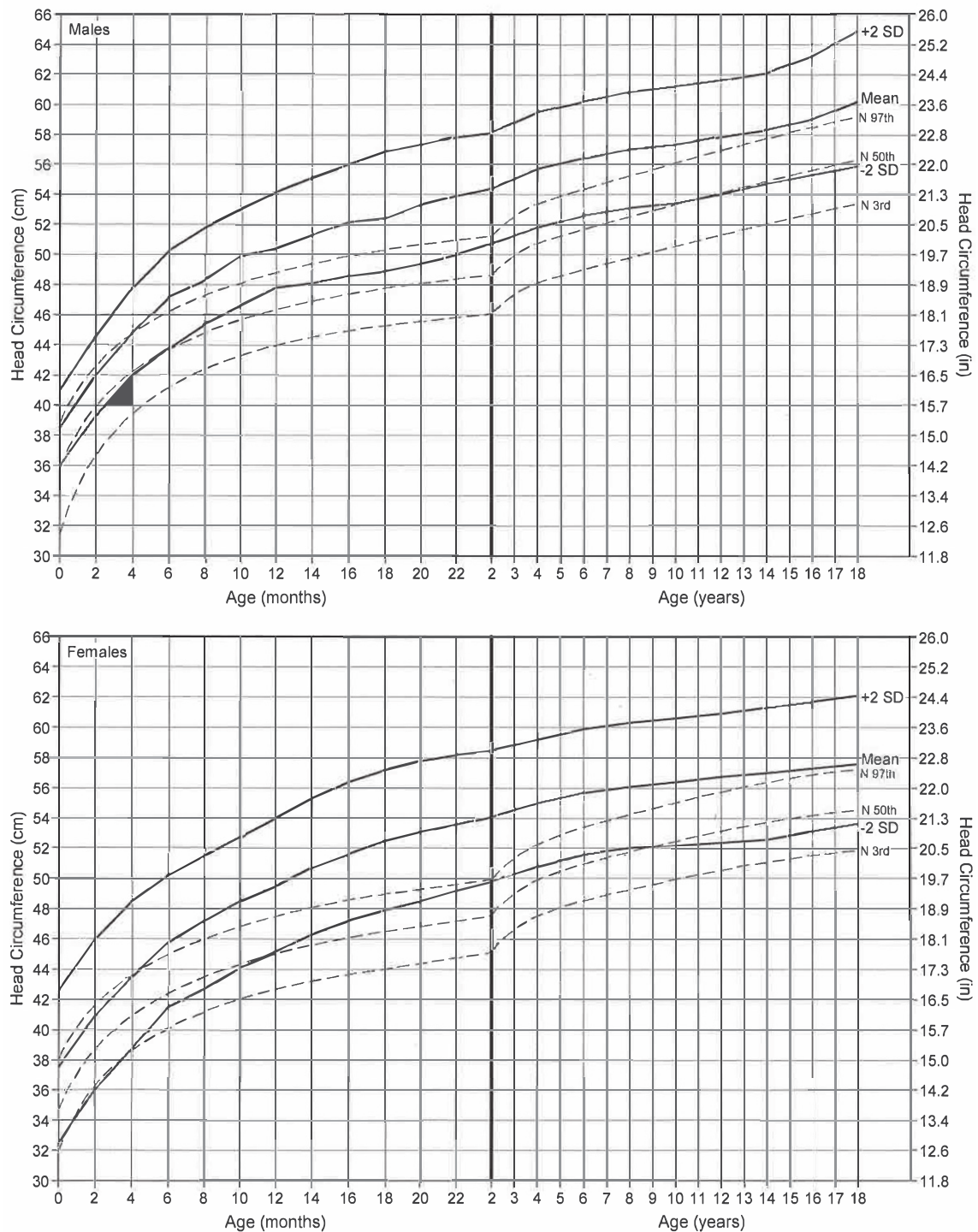


FIGURE 5

Head circumference curves (mean \pm 2 SD) for children with achondroplasia (solid lines) compared with those for the general population (dashed lines). Data are derived from 114 boys and 145 girls. Graphs are adapted from Horton WA, Rotter JL, Rimoin DL, Scott CI, Hall JG. Standard growth curves for achondroplasia. *J Pediatr*. 1978;93(3):435–438. General population curves are from Rollins JD, Collins JS, Holden KR. United States head circumference growth reference charts: birth to 21 years. *J Pediatr*. 2010;156(6):907–913.e2. Illustration is from *Growth References*. Third edition. 2011. Permission for use was granted by the Greenwood Genetic Center.

is adequate trunk muscle strength and tone.

4. Advise parents to use an infant seat or infant carrier that has a firm back (not excessive padding) to support the neck and to use a rear-facing car safety seat for as long as possible.

- a. Car seat laws vary by state (and country) as to the age, weight, and/or height of a child required to convert their seat to forward-facing. Inquire with local experts (eg, police, hospital, or fire station where car seat installation clinics are offered) or online motor vehicle administration.

- b. Infants should not sleep unattended in car seats; this is especially important in those with achondroplasia because decreased axial tone and strength in combination with the large head creates great risk of craniocervical and airway compromise.

5. Avoid use of products like mechanical swings and carrying slings to limit uncontrolled head movement around the small foramen magnum. There is a risk of death if the cervicomedullary junction is compromised, even in infants in which there were no signs of abnormal neurologic status. Always support the head and neck with the caregiver's hand, minimizing flexion and extension (also known as head bobbling).

6. Advise parents that normal intelligence is expected.

7. Advise parents that overall, people with achondroplasia have fairly normal life expectancy. However, the following should be noted:

- a. Wynn et al⁶¹ demonstrated 10-year earlier mortality.⁶²
 - b. Longitudinal studies are required to determine the

cause for this, but serious problems may occur during infancy (eg, cervicomedullary compression, central sleep apnea), as noted.

8. Inform parents that growth hormone and vitamin supplements are not effective in significantly increasing stature. Growth hormone may cause a temporary increase in growth velocity, but little to no significant increase in end height has been shown.^{8–11}

9. Discuss the availability of extended limb lengthening using a variety of surgical techniques, which can result in an increase in ultimate height.

- a. This is a long process with high cost and associated physical pain and can have postoperative adverse effects.

- b. If a family undertakes this procedure, it is critical that the affected child and parents have discussed this at great length and that they are in agreement that proceeding with this surgery is the appropriate decision for them.

- c. If pursued, it should be completed at a well-established surgical center with experience and the capability to manage these patients long-term for complications.

10. Inform parents that the final expected adult height for people with achondroplasia is approximately 120 to 135 cm (4–4.5 ft).

11. If an individual with achondroplasia requires anesthesia and surgery, consider the following⁶³:

- a. Care should be taken in manipulation of the neck because uncontrolled neck movement (as may occur with

intubation) could lead to unintentional spinal cord compression secondary to constriction of the foramen magnum.

- b. Medication should be dosed for patient size, not age.
 - c. Venous access may be more difficult because of incomplete elbow extension.
 - d. In general, spinal or epidural anesthesia should be avoided unless neuroimaging reveals adequate space inside the spinal canal and there are no signs of neurologic compromise.

HEALTH SUPERVISION FROM 1 MONTH TO 1 YEAR OF AGE: INFANCY

Diagnosis, Genetic Counseling

1. For infants not diagnosed in the newborn period, confirm diagnosis by radiographs and physical examination and offer molecular confirmation, if desired.
2. Inquire about personal support available to the family.
3. Inquire about contact with support groups.
4. Observe the emotional status of parents and intrafamily relationships.
5. Discuss the importance of normal socializing experiences with other children.
6. Ask the parents whether they have educated their family members about achondroplasia and offer resources to the Little People of America or local genetic counselors; discuss sibling adjustment.
7. Review genetics of achondroplasia as outlined in the Birth to 1 Month section, as needed.

Medical Evaluation

1. Assess growth (length, weight, head circumference) and

development only in comparison with children with achondroplasia (Figs 1–5).

2. Perform physical examination, including neurologic examination.
3. Check motor development and discuss development; note on the milestone charts for achondroplasia.^{20,22} Expect motor delay as compared with average-stature, age-matched children but not social or cognitive delay.
4. For infants not diagnosed in the newborn period, arrange for polysomnography and neuroimaging at the time of diagnosis.
5. Refer the infant to a pediatric neurologist or pediatric neurosurgeon if any of the following are present:
 - a. Head circumference disproportionately large for length and weight on achondroplasia-specific curves or head circumference crossing percentiles.
 - b. Fontanelle bulging or becoming hard to palpation.
 - c. Abnormal neurologic examination marked by hypotonia or “floppiness,” lethargy, irritability, weakness, sustained lower extremity clonus, asymmetric reflexes, choking or gagging with eating, or early hand preference, which may be attributable to hydrocephalus or craniocervical junction compromise.
 - d. Poor weight gain on achondroplasia-specific growth charts, especially if caloric intake is sufficient.
 - e. Polysomnography showing hypoxemic episodes with oxygen saturation lower than 85% and/or central apnea beyond that expected in an average-stature, healthy infant.⁵⁰

f. Imaging showing marked smaller foramen magnum size, substantial deformation of the upper cervical spinal cord, or lack of CSF around spinal cord.

6. Check for serous otitis media. Formal behavioral audiometric assessment should be completed by 9 to 12 months of age and managed as part of routine health care for patients with achondroplasia, ideally on an annual basis.^{62,64} Language delay may be present secondary to conductive hearing loss.
7. Continue to monitor for progression of kyphosis at the thoracolumbar junction.
 - a. Parents and therapists (if used) should be instructed to provide back support during the first year of life.
 - b. Avoid unsupported sitting and devices that cause curved sitting or “C sitting,” such as “umbrella-style” strollers and soft canvas seats, during the first year of life.
 - c. Position the infant for feeding with a straight back and head and neck in alignment, supported by firm pillows; a feeder seat may be a good option.
 - d. Mild, mobile (nonfixed) thoracolumbar kyphosis will often improve or resolve when the child begins to walk.
 - e. If severe kyphosis appears to be developing, seek pediatric orthopedic assessment to determine if bracing is needed. Rarely, surgical intervention may be necessary.^{59,60}

Anticipatory Guidance

1. Discuss early-intervention services if needed. This is not a uniform recommendation simply because of the diagnosis of achondroplasia.
2. Review the increased risk of serous otitis media because of

short eustachian tubes. Indicate that an ear examination is appropriate with any persistent or severe upper respiratory tract infection or when parents suspect that ear pain may be present.

3. Recommend annual audiology assessment as part of routine health care for patients with achondroplasia.^{62,64}
4. There is a risk of jugular bulb dehiscence (absence of the temporal bone “roof” over the jugular bulb) in patients with achondroplasia. This malformation predisposes to accidental puncture of the jugular bulb during tympanostomy tube placement.⁶⁵
5. Avoid infant carriers and seated positions that “curl up” the infant or young child and avoid prolonged unsupported sitting.
6. Advise parents to use an infant seat or infant carrier that has a firm back (reduced padding) to support the neck and to use a rear-facing car safety seat for as long as possible.
 - a. Car seat laws vary by state (and country), so inquiry with local experts (eg, police, hospital, or fire station where car seat installation clinics are offered) or online motor vehicle administration is recommended.
 - b. Infants should not sleep unattended in car seats; this is especially important in those with achondroplasia because decreased axial tone and strength in combination with the large head creates great risk of craniocervical and airway compromise.
7. Be aware that external rotation of the hips is commonly present and usually disappears spontaneously when the child begins to bear weight. This finding does not require bracing for the infant.

8. Discuss the option of filing for Supplemental Security Income benefits as appropriate.

HEALTH SUPERVISION FROM 1 YEAR TO 5 YEARS: EARLY CHILDHOOD

Diagnosis, Genetic Counseling

1. Review genetics of achondroplasia as outlined in the Birth to 1 Month section, as needed.
2. Inquire about contact with support groups.

Medical Evaluation

1. Assess growth (length or height, weight, head circumference) and development in comparison only with children with achondroplasia (Figs 1–5).
2. Assess BMI on achondroplasia-specific charts⁶⁶ in accordance with AAP recommendations to measure BMI.
3. Perform physical examination, including neurologic examination.
4. Check motor development and discuss development; note on the milestone charts for achondroplasia.^{20,22} Expect motor delay as compared with average-stature, age-matched children but not social or cognitive delay.
5. Continue to monitor for thoracolumbar kyphosis. Any kyphosis present should resolve as the child begins to bear weight. Lumbar lordosis usually develops but rarely requires specific intervention. Weight bearing and walking may occur late; however, they are expected by 2 to 2.5 years of age. When weight bearing begins, the external rotation of the hips should self-correct to a normal orientation within 6 months.
6. Anticipate some bowing of the legs. Many children will also have

instability of the soft tissues surrounding the knee and internal tibial torsion. If positional deformity and instability leads to difficulty walking, a thrust at the knee (uncontrolled lateral or medial movement with weight bearing), or chronic pain, consult a pediatric orthopedist.

7. Check the child's hips for hip flexion contractures. Refer to physical therapy or pediatric orthopedics for exercise recommendation to decrease lumbar lordosis and hip flexion contractures if indicated. Stretching of the hip is performed gently so as not to cause subluxation.
8. Ensure that the patient has an audiology assessment every year in conjunction with establishment of care with an otolaryngologist.^{62,64}
9. Ensure that the patient has a speech evaluation at no later than 2 years of age. If speech is delayed, conductive hearing loss attributable to chronic serous otitis media should be excluded.
10. Because most children with achondroplasia snore, monitor closely for signs of obstructive sleep apnea (increased retraction, glottal stops, choking, intermittent breathing, apnea, deep compensatory sighs, secondary enuresis, recurrent nighttime awakening or emesis) is recommended. If obstructive sleep apnea is suspected, then pulmonary consultation and polysomnography are indicated.
11. Be aware that gastroesophageal reflux disease may be more common in children with achondroplasia and may be more common in those with neurorespiratory

complications.⁶⁷ In addition to usual treatments for gastroesophageal reflux disease, consider referral to a pediatric gastroenterologist or pulmonologist.

12. Do not misinterpret greater-than-average sweating as indicative of serious medical problems; it is normal in many children with achondroplasia, particularly while sleeping. But if there is sweating with eating or the sweating increases dramatically while sleeping and airway obstruction is observed, consider further evaluation with a sleep study.
13. In rare instances in which diagnosis of achondroplasia is delayed beyond 1 year of age, arrange for polysomnography for all individuals and neuroimaging on the basis of clinical signs and symptoms concerning for craniocervical compression, as discussed previously.

Anticipatory Guidance

1. Consider adapting the home so that the child can become independent (eg, lower the light switches, use lever door handles and lever sink faucets, make the toilet accessible, and supply step stools). Determine if an occupational therapy consultation is needed to help adapt the home.
2. Discuss adapting age-appropriate clothing with snapless, easy-opening fasteners and tuckable loops because children with achondroplasia have smaller fingers and shorter arms. Determine if an occupational therapy consultation is needed.
3. Discuss adaptation of toys, such as tricycles, to accommodate short limbs.
4. Discuss adaptation of toilets to allow comfortable, independent use. An extended wand for

wiping is rarely needed in this age group, provided surgical spinal fusion has not been performed. Discuss toileting at school and special preparations needed by the school because of the child's short stature.

5. Discuss the use of a stool during sitting so that the child's feet are not hanging. Feet need support while the child is sitting at a desk, in a chair, or on the toilet. A cushion behind the child's back may be required for good posture and to prevent chronic back pain.
6. Counsel parents for optimal protection to use a convertible rear-facing car safety seat to the highest weight and height allowed by the manufacturer of the seat.⁶⁸ A rear-facing seat provides the best support protection and positioning angle for a child with macrocephaly and skeletal dysplasia.
7. Review weight control and eating habits to avoid obesity, which often becomes a problem in mid to late childhood and through adulthood.
8. Discuss orthodontic bracing and the potential need for palatal expansion in the future.
9. Encourage all physical activities in which the child can participate safely. All children should avoid trampolines⁶⁹ and high-impact, body-contact, and collision sports.⁷⁰
10. Discuss how to talk with the child and friends or family members about short stature.
11. Encourage preschool attendance so that the child can learn to socialize in an age-appropriate way, and work with parents to prepare the teacher and the other children so that the child is treated in an age-appropriate manner (ie, not dictated by the child's height).

HEALTH SUPERVISION FROM 5 TO 13 YEARS: LATE CHILDHOOD

Diagnosis, Genetic Counseling

1. Review genetics of achondroplasia as outlined in the Birth to 1 Month section, as needed.
2. Inquire about contact with support groups. They are especially useful at this age.

Medical Evaluation

1. Assess growth (height, weight, head circumference) and development in comparison only with children with achondroplasia (Figs 1–5).
2. Review weight control.^{44,66} Encouraging and maintaining physical activity with dietary intake is important.
3. Complete a general and neurologically oriented physical examination.
4. Check deep tendon reflexes yearly for asymmetry or increased reflexes that suggest spinal stenosis.
5. Continue to assess history for possible obstructive sleep apnea (increased retraction, glottal stops, choking, intermittent breathing, apnea, deep compensatory sighs, secondary enuresis, recurrent nighttime awakening or emesis). If obstructive sleep apnea is suspected, then pulmonary consultation and polysomnography are indicated.
6. Ensure that formal hearing assessment is conducted as part of annual health maintenance for patients with achondroplasia,^{62,64} with ear, nose, and throat follow-up should problems be identified.
7. Assess for pain and its effects on activities of daily living and desired physical activity.²⁶

Anticipatory Guidance

1. Determine school readiness.
2. Discuss preparation of the school and teacher for a child with short stature. Suggest adaptive aids for

the school to cope with heavy doors, high doorknobs, reaching for the blackboard, foot support, and a regular-sized desk. Also, be sure that the child can use the restroom independently.

3. Prepare the child for the questions and curiosity of others.
4. Assure the parents that children with achondroplasia usually are included in the regular education program.
5. Counsel parents to use a child safety seat with a full harness to the highest weight allowed by the manufacturer of the seat and then to transition to the belt-positioning booster seat for optimal seatbelt positioning.
6. Review socialization and foster independence.
7. Maintain orthopedic surveillance every 1 to 2 years or sooner, if problems occur.
8. Emphasize supported sitting in school desks and while doing homework to avoid kyphosis.
9. Develop an activity program with acceptable activities, such as swimming and biking. The child should avoid competitive gymnastics and collision sports because of the potential for neurologic complications secondary to cervical spinal stenosis.
10. Review orthodontic and speech status.

HEALTH SUPERVISION FROM 13 TO 21 YEARS OR OLDER: ADOLESCENCE TO EARLY ADULTHOOD

Diagnosis, Genetic Counseling

1. Discuss the diagnosis with the adolescent to be sure that he or she has the vocabulary and the understanding of the genetic nature of achondroplasia.
2. Discuss contraception. People with achondroplasia usually are fertile. The importance and use of

contraception should be discussed with both male and female adolescents with achondroplasia, just as it should be for average-stature adolescents. Tailored to the maturity and sexual activity of the adolescent or young adult, review recurrence risk counseling with the patient, as outlined in the Prenatal Visit section previously. The parents of adolescents or young adults may have heard this information for their recurrence risk counseling; now the adolescent needs this information for his or her reproductive decision-making. Ideally, discussions about prenatal testing, pregnancy, and delivery are conducted before conception occurs.³⁸

3. Continue to encourage participation in social activities and support groups. It is particularly useful during this age period.
4. Per the published AAP guidelines for adolescent health, proceed with discussions regarding smoking, drug use, alcohol use, sexual activity, gender identity, exposure to weapons, food and shelter security, and a focus on bullying and psychological health.

Medical Evaluation

1. Continue to record growth parameters.
2. Review weight control and diet. Encouraging and maintaining physical activity with dietary intake is necessary.
3. Complete a general and neurologically oriented physical examination. Monitor for any signs or symptoms of nerve compression and check deep tendon reflexes, tone, and sensory findings.
4. Continue to assess for possible obstructive sleep apnea and obtain polysomnography on the basis of symptoms.
5. Formal hearing assessment is recommended as part of routine

health care for patients with achondroplasia, ideally on an annual basis.

6. Assess for pain and its effects on activities of daily living and desired physical activity.

Anticipatory Guidance

1. Check on social adaptation. Foster independence.
2. Review orthodontic status.
3. Continue weight counseling.
4. Encourage the family and affected patient to set career and life goals high and appropriate, as for other members of the family.
5. Discuss college, vocational planning and training, and other plans after high school.
6. Discuss driving. A driver's license is obtainable. Drivers usually require a vehicle that is adapted with pedal extenders; extenders that can be easily mounted and removed as needed are available. Consultation with a local driver rehabilitation specialist or the Association for Driver Rehabilitation Specialists (<http://www.aded.net/>; phone 866-672-9466) may be helpful if vehicle modifications are needed. Individuals who want to have an air bag on-off switch must read an informational brochure and submit an official request to the National Highway Traffic Safety Administration (1-888-327-4236; www.nhtsa.gov).
7. Assist in transition to adult health care.

HEALTH SUPERVISION FOR ADULTS WITH ACHONDROPLASIA

Health supervision for adults with achondroplasia, which includes genetic counseling, medical concerns and surveillance, and anticipatory guidance, is multifaceted. Health supervision requires specific management recommendations based on the scope of the disease and

symptomatology of the patient. Several of the key features that should be addressed in adulthood are included in the Prenatal Visit section for short-stature adults and noted in Table 1.

LEAD AUTHORS

Julie Hoover-Fong, MD, PhD, FACMG
Charles I. Scott, MD, FAAP
Marilyn C. Jones, MD, FAAP

COUNCIL ON GENETICS EXECUTIVE COMMITTEE, 2017–2018

Emily Chen, MD, PhD, FAAP, Co-Chairperson
Tracy L. Trotter, MD, FAAP, Co-Chairperson
Susan A. Berry, MD, FAAP
Leah W. Burke, MD, FAAP
Timothy A. Geleske, MD, FAAP
Rizwan Hamid, MD, PhD, FAAP
Robert J. Hopkin, MD, FAAP
Wendy J. Introne, MD, FAAP
Michael J. Lyons, MD, FAAP
Angela Scheuerle, MD, FAAP
Joan M. Stoler, MD, FAAP

FORMER EXECUTIVE COMMITTEE MEMBERS

Robert A. Saul, MD, FAAP, Chairperson
Debra L. Freedenberg, MD, FAAP
Marilyn C. Jones, MD, FAAP
Beth Anne Tarini, MD, MS, FAAP

LIAISONS

Katrina M. Dipple, MD, PhD – *American College of Medical Genetics*
Melissa A. Parisi, MD, PhD – *Eunice Kennedy Shriver National Institute of Child Health and Human Development*
Britton D. Rink, MD – *American College of Obstetricians and Gynecologists*
Joan A. Scott, MS, CGC – *Health Resources and Services Administration, Maternal and Child Health Bureau*
Stuart K. Shapira, MD, PhD – *Centers for Disease Control and Prevention*

STAFF

Paul Spire

ABBREVIATIONS

AAP: American Academy of Pediatrics
CSF: cerebrospinal fluid
FGFR3: fibroblast growth factor receptor type 3

FINANCIAL DISCLOSURE: Dr Hoover-Fong received research support from Alexion and BioMarin, participated on Alexion's advisory board (not related to achondroplasia), and has a consultancy and educational relationship with BioMarin (related to achondroplasia); and Drs Scott and Jones have indicated they have no financial relationships relevant to this article to disclose.

FUNDING: No external funding.

POTENTIAL CONFLICT OF INTEREST: The authors have indicated they have no potential conflicts of interest to disclose.

REFERENCES

- American Academy of Pediatrics Committee on Genetics. Health supervision for children with achondroplasia. *Pediatrics*. 1995;95(3):443–451
- Trotter TL, Hall JG; American Academy of Pediatrics Committee on Genetics. Health supervision for children with achondroplasia [published correction appears in *Pediatrics* 2005;116(6):1615]. *Pediatrics*. 2005;116(3):771–783
- Shiang R, Thompson LM, Zhu YZ, et al. Mutations in the transmembrane domain of FGFR3 cause the most common genetic form of dwarfism, achondroplasia. *Cell*. 1994;78(2):335–342
- Horton WA, Hall JG, Hecht JT. Achondroplasia. *Lancet*. 2007;370(9582):162–172
- Rousseau F, Bonaventure J, Legeai-Mallet L, et al. Mutations in the gene encoding fibroblast growth factor receptor-3 in achondroplasia. *Nature*. 1994;371(6494):252–254
- Bellus GA, Hefferon TW, Ortiz de Luna RI, et al. Achondroplasia is defined by recurrent G380R mutations of FGFR3. *Am J Hum Genet*. 1995;56(2):368–373
- Wright MJ, Ain MC, Clough MV, Bellus GA, Hurko O, McIntosh I. Achondroplasia and nail-patella syndrome: the compound phenotype. *J Med Genet*. 2000;37(9):E25
- Tanaka N, Katsumata N, Horikawa R, Tanaka T. The comparison of the effects of short-term growth hormone treatment in patients with achondroplasia and with hypochondroplasia. *Endocr J*. 2003;50(1):69–75
- Hertel NT, Eklöf O, Ivarsson S, et al. Growth hormone treatment in 35 prepubertal children with achondroplasia: a five-year dose-response trial. *Acta Paediatr*. 2005;94(10):1402–1410
- Miccoli M, Bertelloni S, Massart F. Height outcome of recombinant human growth hormone treatment in achondroplasia children: a meta-analysis. *Horm Res Paediatr*. 2016;86(1):27–34
- Stamoyannou L, Karachaliou F, Neou P, Papataxiarchou K, Pistevos G, Bartsocas CS. Growth and growth hormone therapy in children with achondroplasia: a two-year experience. *Am J Med Genet*. 1997;72(1):71–76
- MacDonald IM, Hunter AG, MacLeod PM, MacMurray SB. Growth and development in thanatophoric dysplasia. *Am J Med Genet*. 1989;33(4):508–512
- Pauli RM. Achondroplasia. In: Cassidy SB, Allanson JE, eds. *Management of Genetic Syndromes*, 3rd ed. New York, NY: Wiley-Liss; 2010:9–32
- Baker KM, Olson DS, Harding CO, Pauli RM. Long-term survival in typical thanatophoric dysplasia type 1. *Am J Med Genet*. 1997;70(4):427–436
- Pauli RM. Achondroplasia. In: Pagon RA, Bird TD, Dolan CR, eds., et al *GeneReviews*. Seattle, WA: University of Washington; 1993
- Horton WA, Rotter JL, Rimoin DL, Scott CI, Hall JG. Standard growth curves for achondroplasia. *J Pediatr*. 1978;93(3):435–438
- Hecht JT, Butler IJ. Neurologic morbidity associated with achondroplasia. *J Child Neurol*. 1990;5(2):84–97
- Pyeritz RE, Sack GH Jr., Udvarhelyi GB. Thoracolumbosacral laminectomy in achondroplasia: long-term results in 22 patients. *Am J Med Genet*. 1987;28(2):433–444
- Ain MC, Chang TL, Schkrohowsky JG, Carlisle ES, Hodor M, Rigamonti D. Rates of perioperative complications associated with laminectomies in patients with achondroplasia. *J Bone Joint Surg Am*. 2008;90(2):295–298
- Todorov AB, Scott CI Jr., Warren AE, Leeper JD. Developmental screening tests in achondroplastic children. *Am J Med Genet*. 1981;9(1):19–23
- Fowler ES, Glinski LP, Reiser CA, Horton VK, Pauli RM. Biophysical bases for delayed and aberrant motor development in young children with achondroplasia. *J Dev Behav Pediatr*. 1997;18(3):143–150
- Ireland PJ, Donaghey S, McGill J, et al. Development in children with achondroplasia: a prospective clinical cohort study. *Dev Med Child Neurol*. 2012;54(6):532–537
- Kopits SE. Genetics clinics of the Johns Hopkins Hospital. Surgical intervention in achondroplasia. Correction of bowleg deformity in achondroplasia. *Johns Hopkins Med J*. 1980;146(5):206–209
- Thompson NM, Hecht JT, Bohan TP, et al. Neuroanatomic and neuropsychological outcome in school-age children with achondroplasia. *Am J Med Genet*. 1999;88(2):145–153
- Thompson S, Shakespeare T, Wright MJ. Medical and social aspects of the life course for adults with a skeletal dysplasia: a review of current knowledge. *Disabil Rehabil*. 2008;30(1):1–12
- Alade Y, Tunkel D, Schulze K, et al. Cross-sectional assessment of pain and physical function in skeletal dysplasia patients. *Clin Genet*. 2013;84(3):237–243
- Mortier GR, Cohn DH, Cormier-Daire V, et al. Nosology and classification of genetic skeletal disorders: 2019 revision. *Am J Med Genet A*. 2019;179(12):2393–2419
- American Board of Medical Genetics. Verify certification. Available at: <http://>

- www.abmgg.org/pages/searchmem.shtml. Accessed March 2, 2017
29. Little People of America. Little people of America. Available at: www.lpaonline.org/. Accessed March 2, 2017
 30. Launay F, Younsi R, Pithioux M, Chabrand P, Bollini G, Jouve JL. Fracture following lower limb lengthening in children: a series of 58 patients. *Orthop Traumatol Surg Res*. 2013;99(1):72–79
 31. Kim SJ, Agashe MV, Song SH, Choi HJ, Lee H, Song HR. Comparison between upper and lower limb lengthening in patients with achondroplasia: a retrospective study. *J Bone Joint Surg Br*. 2012;94(1):128–133
 32. Schiedel F, Rödl R. Lower limb lengthening in patients with disproportionate short stature with achondroplasia: a systematic review of the last 20 years. *Disabil Rehabil*. 2012;34(12):982–987
 33. Committee on Bioethics. Informed consent in decision-making in pediatric practice. *Pediatrics*. 2016;138(2):e20161484
 34. Laederich MB, Horton WA. FGFR3 targeting strategies for achondroplasia. *Expert Rev Mol Med*. 2012;14:e11
 35. Lorget F, Kaci N, Peng J, et al. Evaluation of the therapeutic potential of a CNP analog in a Fgfr3 mouse model recapitulating achondroplasia. *Am J Hum Genet*. 2012;91(6):1108–1114
 36. Boulet S, Althuser M, Nùgues F, Schaal J-P, Jouk P-S. Prenatal diagnosis of achondroplasia: new specific signs. *Prenat Diagn*. 2009;29(7):697–702
 37. Krakow D, Lachman RS, Rimoin DL. Guidelines for the prenatal diagnosis of fetal skeletal dysplasias. *Genet Med*. 2009;11(2):127–133
 38. Savarirayan R, Rossiter JP, Hoover-Fong JE, et al; Skeletal Dysplasia Management Consortium. Best practice guidelines regarding prenatal evaluation and delivery of patients with skeletal dysplasia. *Am J Obstet Gynecol*. 2018;219(6):545–562
 39. Little People of America. Adoption. Available at: www.lpaonline.org/adoption-. Accessed March 8, 2013
 40. Pauli RM, Conroy MM, Langer LO Jr, et al. Homozygous achondroplasia with survival beyond infancy. *Am J Med Genet*. 1983;16(4):459–473
 41. Mettler G, Fraser FC. Recurrence risk for sibs of children with “sporadic” achondroplasia. *Am J Med Genet*. 2000;90(3):250–251
 42. Henderson S, Sillence D, Loughlin J, Bennetts B, Sykes B. Germline and somatic mosaicism in achondroplasia. *J Med Genet*. 2000;37(12):956–958
 43. Sobetzko D, Braga S, Rüdeberg A, Superti-Furga A. Achondroplasia with the FGFR3 1138g→a (G380R) mutation in two sibs sharing a 4p haplotype derived from their unaffected father. *J Med Genet*. 2000;37(12):958–959
 44. Hoover-Fong JE, McGready J, Schulze KJ, Barnes H, Scott CI. Weight for age charts for children with achondroplasia. *Am J Med Genet A*. 2007;143A(19):2227–2235
 45. White KK, Bompadre V, Goldberg MJ, et al. Best practices in the evaluation and treatment of foramen magnum stenosis in achondroplasia during infancy. *Am J Med Genet A*. 2016;170A(1):42–51
 46. Hecht JT, Horton WA, Reid CS, Pyeritz RE, Chakraborty R. Growth of the foramen magnum in achondroplasia. *Am J Med Genet*. 1989;32(4):528–535
 47. Hecht JT, Nelson FW, Butler IJ, et al. Computerized tomography of the foramen magnum: achondroplastic values compared to normal standards. *Am J Med Genet*. 1985;20(2):355–360
 48. Danielpour M, Wilcox WR, Alanay Y, Pressman BD, Rimoin DL. Dynamic cervicomedullary cord compression and alterations in cerebrospinal fluid dynamics in children with achondroplasia. Report of four cases. *J Neurosurg*. 2007;107(6 suppl):504–507
 49. Mukherjee D, Pressman BD, Krakow D, Rimoin DL, Danielpour M. Dynamic cervicomedullary cord compression and alterations in cerebrospinal fluid dynamics in children with achondroplasia: review of an 11-year surgical case series. *J Neurosurg Pediatr*. 2014;14(3):238–244
 50. Pauli RM, Scott CI, Wassman ER Jr, et al. Apnea and sudden unexpected death in infants with achondroplasia. *J Pediatr*. 1984;104(3):342–348
 51. Reid CS, Pyeritz RE, Kopits SE, et al. Cervicomedullary compression in young patients with achondroplasia: value of comprehensive neurologic and respiratory evaluation. *J Pediatr*. 1987;110(4):522–530
 52. Hecht JT, Butler IJ, Scott CI Jr. Long-term neurological sequelae in achondroplasia. *Eur J Pediatr*. 1984;143(1):58–60
 53. Pauli RM, Horton VK, Glinski LP, Reiser CA. Prospective assessment of risks for cervicomedullary-junction compression in infants with achondroplasia. *Am J Hum Genet*. 1995;56(3):732–744
 54. Steinbok P, Hall J, Flodmark O. Hydrocephalus in achondroplasia: the possible role of intracranial venous hypertension. *J Neurosurg*. 1989;71(1):42–48
 55. Stokes DC, Phillips JA, Leonard CO, et al. Respiratory complications of achondroplasia. *J Pediatr*. 1983;102(4):534–541
 56. Julliard S, Boulé M, Baujat G, et al. Lung function, diagnosis, and treatment of sleep-disordered breathing in children with achondroplasia. *Am J Med Genet A*. 2012;158A(8):1987–1993
 57. Mogayzel PJ Jr, Carroll JL, Loughlin GM, Hurko O, Francomano CA, Marcus CL. Sleep-disordered breathing in children with achondroplasia. *J Pediatr*. 1998;132(4):667–671
 58. Hall JG. Kyphosis in achondroplasia: probably preventable. *J Pediatr*. 1988;112(1):166–167
 59. Pauli RM, Breed A, Horton VK, Glinski LP, Reiser CA. Prevention of fixed, angular kyphosis in achondroplasia. *J Pediatr Orthop*. 1997;17(6):726–733
 60. Borkhuu B, Nagaraju DK, Chan G, Holmes L Jr, Mackenzie WG. Factors related to progression of thoracolumbar kyphosis in children with achondroplasia: a retrospective cohort study of forty-eight children treated in a comprehensive orthopaedic center. *Spine*. 2009;34(16):1699–1705
 61. Wynn J, King TM, Gambello MJ, Waller DK, Hecht JT. Mortality in achondroplasia study: a 42-year follow-up. *Am J Med Genet A*. 2007;143A(21):2502–2511

62. Tunkel DE, Kerbavaz R, Smith B, Rose-Hardison D, Alade Y, Hoover-Fong J. Hearing screening in children with skeletal dysplasia. *Arch Otolaryngol Head Neck Surg.* 2011;137(12):1236–1239
63. White KK, Bompadre V, Goldberg MJ, et al; Skeletal Dysplasia Management Consortium. Best practices in peri-operative management of patients with skeletal dysplasias. *Am J Med Genet A.* 2017;173(10):2584–2595
64. Tunkel D, Alade Y, Kerbavaz R, Smith B, Rose-Hardison D, Hoover-Fong J. Hearing loss in skeletal dysplasia patients. *Am J Med Genet A.* 2012;158A(7):1551–1555
65. Pauli RM, Modaff P. Jugular bulb dehiscence in achondroplasia. *Int J Pediatr Otorhinolaryngol.* 1999;48(2):169–174
66. Hoover-Fong JE, Schulze KJ, McGready J, Barnes H, Scott CI. Age-appropriate body mass index in children with achondroplasia: interpretation in relation to indexes of height. *Am J Clin Nutr.* 2008;88(2):364–371
67. Tasker RC, Dundas I, Lavery A, Fletcher M, Lane R, Stocks J. Distinct patterns of respiratory difficulty in young children with achondroplasia: a clinical, sleep, and lung function study. *Arch Dis Child.* 1998;79(2):99–108
68. Durbin DR; American Academy of Pediatrics, Committee on Injury, Violence, and Poison Prevention. Child passenger safety. *Pediatrics.* 2011;127(4). Available at: www.pediatrics.org/cgi/content/full/127/4/e1050
69. Briskin S, LaBotz M; Council on Sports Medicine and Fitness; American Academy of Pediatrics. Trampoline safety in childhood and adolescence. *Pediatrics.* 2012;130(4):774–779
70. Rice SG; American Academy of Pediatrics Council on Sports Medicine and Fitness. Medical conditions affecting sports participation. *Pediatrics.* 2008;121(4):814–848

Health Supervision for People With Achondroplasia
Julie Hoover-Fong, Charles I. Scott, Marilyn C. Jones and COMMITTEE ON
GENETICS

Pediatrics 2020;145;

DOI: 10.1542/peds.2020-1010 originally published online May 26, 2020;

Updated Information & Services

including high resolution figures, can be found at:
<http://pediatrics.aappublications.org/content/145/6/e20201010>

References

This article cites 64 articles, 9 of which you can access for free at:
<http://pediatrics.aappublications.org/content/145/6/e20201010#BIBL>

Subspecialty Collections

This article, along with others on similar topics, appears in the following collection(s):

Current Policy

http://www.aappublications.org/cgi/collection/current_policy

Council on Genetics

http://www.aappublications.org/cgi/collection/committee_on_genetics

Genetics

http://www.aappublications.org/cgi/collection/genetics_sub

Permissions & Licensing

Information about reproducing this article in parts (figures, tables) or in its entirety can be found online at:

<http://www.aappublications.org/site/misc/Permissions.xhtml>

Reprints

Information about ordering reprints can be found online:

<http://www.aappublications.org/site/misc/reprints.xhtml>

American Academy of Pediatrics

DEDICATED TO THE HEALTH OF ALL CHILDREN®



PEDIATRICS®

OFFICIAL JOURNAL OF THE AMERICAN ACADEMY OF PEDIATRICS

Health Supervision for People With Achondroplasia

Julie Hoover-Fong, Charles I. Scott, Marilyn C. Jones and COMMITTEE ON GENETICS

Pediatrics 2020;145;

DOI: 10.1542/peds.2020-1010 originally published online May 26, 2020;

The online version of this article, along with updated information and services, is located on the World Wide Web at:

<http://pediatrics.aappublications.org/content/145/6/e20201010>

Pediatrics is the official journal of the American Academy of Pediatrics. A monthly publication, it has been published continuously since 1948. Pediatrics is owned, published, and trademarked by the American Academy of Pediatrics, 345 Park Avenue, Itasca, Illinois, 60143. Copyright © 2020 by the American Academy of Pediatrics. All rights reserved. Print ISSN: 1073-0397.

American Academy of Pediatrics

DEDICATED TO THE HEALTH OF ALL CHILDREN®

