

CASE REPORT

Nagoya J. Med. Sci. 75. 279 ~ 286, 2013

SURGICAL TREATMENT FOR KYPHOSCOLIOSIS IN COHEN SYNDROME

SHIRO IMAGAMA¹, TAICHI TSUJI², TETSUYA OHARA², YOSHITO KATAYAMA³,
MANABU GOTO⁴, NAOKI ISHIGURO¹ and NORIAKI KAWAKAMI²

¹Department of Orthopaedic Surgery, Nagoya University Graduate School of Medicine, Nagoya, Japan

²Department of Orthopaedic Surgery and Spine Center, Meijo Hospital, Nagoya, Japan

³Department of Orthopaedic Surgery, Nagoya Daini Red Cross Hospital, Nagoya, Japan

⁴Goto Hospital and Spine Center, Toyokawa, Japan

ABSTRACT

Cohen syndrome is a very rare disease. Complication by spinal deformity has been reported, but management and surgery for spinal deformity in Cohen syndrome has not been previously described. The objective of this study was to examine the outcome of surgical treatment for kyphoscoliosis of Cohen syndrome with a literature review. The patient was a 14-year-old male with the characteristics of Cohen syndrome: truncal obesity, mental retardation, arachnodactyly, microcephalia, and a facial malformation. Scoliosis was conservatively treated with a brace at 13 years of age, but the spinal deformity rapidly progressed within a year. Plain radiographs before surgery showed scoliosis of 47° (T5-T11) and 79° (T11-L3), and kyphosis of 86° (T7-L1). One-stage anteroposterior corrective fusion of T4-L3 was scheduled after 2-week Halo traction. Postoperative respiratory management was carefully performed because of Cohen syndrome-associated facial malformation, obesity, and reduced muscle tonus. Respiration was managed with intubation until the following day and no respiratory problems occurred. After surgery, thoracolumbar scoliosis was 28° (correction rate: 65%). Kyphosis was markedly improved from 86° to 20°, achieving a favorable balance of the trunk. The outcome is favorable at 6.5 years after surgery. In conclusion, Cohen syndrome is often complicated by spinal deformity, particularly kyphosis, that is likely to progress even in adulthood. In our patient, spinal deformity progressed within a short period, even with brace treatment. Surgery should be required before progression to the severe spinal deformity with careful attention to general anesthesia.

Key Words: Cohen syndrome; Kyphoscoliosis; Hypotonus; Obesity; General anesthesia

INTRODUCTION

Patients with Cohen syndrome have the main characteristics of a facial malformation, reduced muscle tonus, obesity of the trunk, short height, and mental retardation.¹⁾ More than 100 patients have been reported worldwide: the incidence is high in Finns and Jews, and lower in other races.²⁻⁷⁾ Complication with spinal deformity has been reported in some literatures, in addition to complications of cubitus valgus, genu valgum, and arachnodactyly as the complications in four limbs and trunk.⁸⁾ However, to our knowledge, the details of management and surgery for

Received: June 19, 2013; accepted: July 16, 2013

Corresponding author: Shiro Imagama MD

Department of Orthopaedic Surgery, Nagoya University Graduate School of Medicine,
65, Tsurumai-cho, Showa-ku, Nagoya, Aichi, 466-8550, Japan

Phone: +81-52-741-2111, Fax: +81-52-744-2260, E-mail: imagama@med.nagoya-u.ac.jp

spinal deformity in Cohen syndrome have not been described. Herein, we report the case of a patient with Cohen syndrome who underwent surgical treatment for kyphoscoliosis. Consent for publication has been obtained from him and his parents.

CASE REPORT

The patient was a 14-year-old male with mental retardation who had been diagnosed with Cohen syndrome at a pediatric clinic. He had undergone right femoral epiphysiodesis at 12 years of age, but had no other relevant past or familial medical history. Scoliosis was diagnosed at 13 years of age and conservative brace treatment was performed at another hospital. However, the scoliosis progressed by 20° within a year and the patient was referred to our Hospital.

At the first examination, the patient had a height of 158 cm and a body weight of 62 kg. He had obesity of the trunk and other characteristic features of Cohen syndrome, including mental retardation, arachnodactyly and microcephalia. Characteristic physical features of Cohen syndrome were also observed, including marked prominence of the nose root, wide nose wing, short philtrum, extorsion of thick lips, and large incisors (Fig. 1). Blood tests showed no abnormalities and there were no neurological abnormalities. Thoracic kyphosis was obvious and a 15° rib hump was noted, showing coronal decompensation.

On preoperative plain radiograph, scoliosis of T5-T11 was 47° , that of T11-L3 was 79° , L3 tilt was 34° , and kyphosis of T7-L1 was 86° (Fig. 2A,B). In the lateral bending film, both the

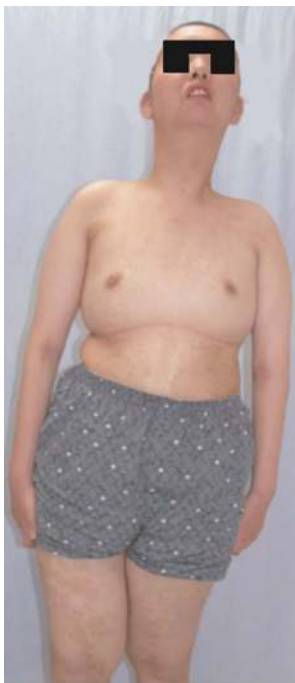

Fig. 1 Photographs of the patient. In addition to obesity of the trunk, thin limbs, and microcephalia, characteristic features of Cohen syndrome were observed, such as marked prominence of the nose root, wide nose wing, short philtrum, extorsion of thick lips, and large incisors. The coronal balance of the trunk was inclined.

KYPHOSCOLIOSIS IN COHEN SYNDROME

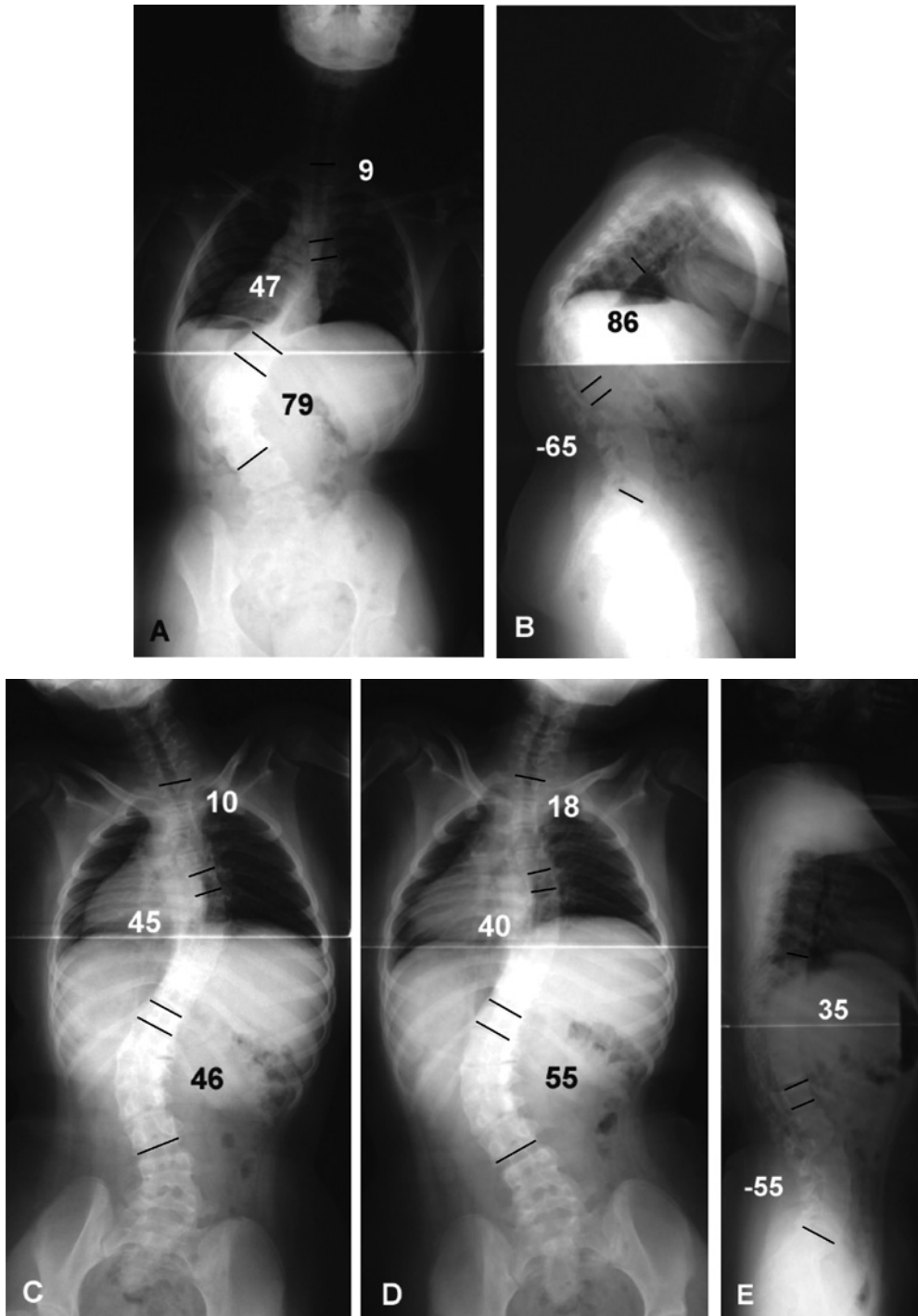


Fig. 2 Plain radiographs before surgery. A: Scoliosis of T5-T11 was 47°, that of T11-L3 was 79°, and L3 tilt was 34°. B: Kyphosis of T7-L1 was 86°. C, D: In the lateral bending film, the thoracic and thoracolumbar curves were rigid. E: In the lateral traction film, kyphosis was improved to 35° (T7-L1).

thoracic and thoracolumbar curves were rigid (Fig. 2C,D). In the traction film, the thoracolumbar scoliosis was 52°, showing a slight improvement, and kyphosis was improved to 35° (Fig. 2E). There were no features of congenital scoliosis or kyphosis.

Surgery was planned because conservative brace treatment was ineffective, the scoliosis was very progressive, and kyphosis was marked. Halo traction was planned for two weeks before surgery to prevent paralysis induced by sudden surgical correction. Anterior and posterior combined surgery was scheduled for rigid symptomatic scoliosis, with the goal of improving kyphosis by posterior correction using the cantilever technique without osteotomy, because some correction was already apparent on lateral traction plain radiograph. After discussion with the parents of the patient, one-stage anteroposterior corrective fusion of T4-L3 was scheduled. Due to possible postoperative protraction of anesthesia-induced muscle relaxation due to reduced muscle tonus, the potential difficulty of the patient to rest due to mental retardation, and difficulty with reintubation due to facial abnormality, postoperative respiratory management with intubation was planned for safety after discussion with anesthesiologists.

Surgery

Initially, left anterior thoracotomy was performed in the right lateral position and anterior corrective fusion was applied to T12-L3 using the TSRH system (Medtronic Sofamor Danek) and rib bone grafting. For using of pedicle screws in the posterior surgery, screws were inserted in the lower half of the vertebral body. The posture was then changed to the prone position and posterior corrective fusion of T4-L3 was performed using pedicle screws, hooks, wire, and iliac bone grafting. Kyphosis was corrected using a cantilever while applying Halo traction and scoliosis was corrected by applying compression and distraction forces and additional in situ bending. Spinal cord monitoring was stable during surgery. The total operation time was 8 hours and 6 minutes, and the total blood loss was 1246 ml. Homologous blood transfusion was avoided by intraoperative blood recovery and preoperative autologous blood collection.

There were no problems concerning general anesthesia during surgery. A total of 5 mg of vecuronium was administered, but no delay of recovery from the muscle relaxant effect or arousal occurred after surgery. To ensure safe postoperative respiratory management, intubation was performed and the tube was removed on the following day. The patient started walking at 1 week after surgery. He was discharged to home without complications.

Postoperative plain radiographs showed thoracolumbar scoliosis of 28°, giving a correction rate of 65%, and the L3 tilt was improved from 34° to 9°. Kyphosis was also markedly improved from 86° to 20° and a favorable balance of the trunk was achieved. Bony fusion was obtained without loss of correction and good body balance was maintained at 6.5 years after surgery (Fig. 3A,B).

DISCUSSION

The incidence of Cohen syndrome is relatively high in Finland and Israel, but is still rare, with a rate of 1 in 105,000 persons in the Finnish population.⁹⁾ Only about 10 Japanese cases have been reported.^{10,11)} Cohen syndrome is transmitted by autosomal recessive inheritance. The responsible gene, COH1, is located at 8q22,¹²⁻¹⁴⁾ but the causal genetic link has not been completely proven¹⁵⁾ and solitary cases have also been reported.¹⁶⁾ A patient with Cohen syndrome is normal for some time after birth, but muscle tonus slowly decreases, a delay in motor development becomes apparent, and the patient does not start independent walking until 2–5 years of age. Marked prominence of the nose root, a wide nose wing, short philtrum, extorsion of thick lips,

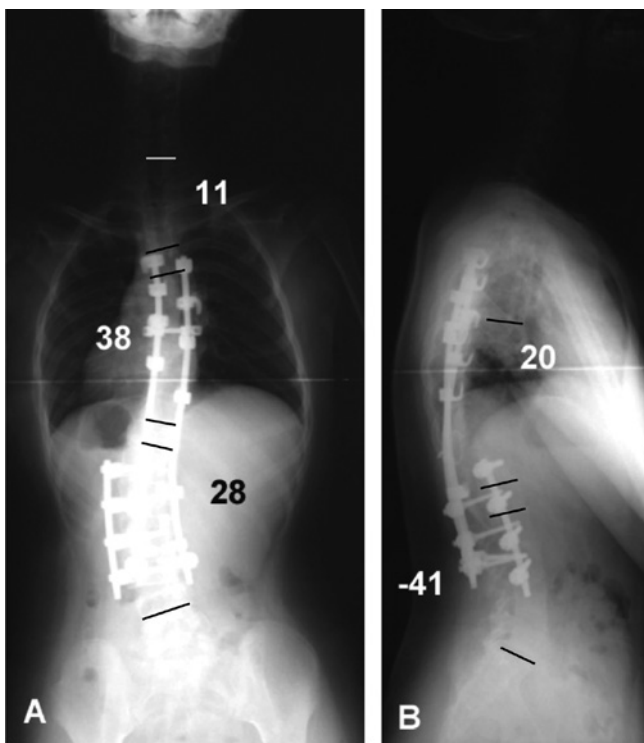


Fig. 3 Plain radiographs after surgery. A: Thoracolumbar scoliosis was 28° (T11-L4), giving a correction rate of 65%, and L3 tilt was improved from 34° to 9° . B: Kyphosis was markedly improved from 86° to 20° (T7-L1)

and large incisors are observed as specific features. However, microcephalia is the abnormality that is initially noticeable, at about 1 year after birth.¹⁷⁾ Survival is favorable because there is no severe complication involving visceral organ dysfunction.^{8,18)}

There are 6 characteristic symptoms of Cohen syndrome: facial malformation, reduced muscle tonus, truncal obesity, short height, mental retardation, and visual abnormality, and patients are divided into Finland and Israel types based on differences in visual loss and other symptoms of complications.¹⁰⁾ The Finland type is complicated by pigmentary degeneration of the retina and leukopenia, but is not sensitive to infection. The Israel type does not have these complications and tends to be milder than the Finland type.¹⁹⁾ The patient in this report was of the Israel type, and it is interesting that severe kyphoscoliosis occurred in this relatively mild type. Complication of Cohen syndrome by spinal deformity is known, but to our knowledge this is the first report describing surgical correction of spinal deformity.

Among English literatures on spinal deformity in Cohen syndrome, Cohen reported a 100% incidence (3/3) of scoliosis,¹⁾ and Chandler *et al.* found an incidence of kyphoscoliosis of 31% in 33 patients (3–46 years of age) registered in a Cohen syndrome support group.²⁾ However, neither of these studies reported measured values or the method of evaluation of kyphoscoliosis. Kivitie-Lallio *et al.* measured the scoliosis and thoracic kyphosis angles in 17 Finnish patients with Cohen syndrome (4 children and 13 adults) and found incidences of scoliosis of 59% and of severe thoracic kyphosis ($>40^\circ$) of 75%.⁸⁾ These are interesting results, but it should be noted that most of the data were from adult patients, and the details of the thoracic kyphosis angle or

thoracolumbar and lumbar kyphosis, plain radiographs, and treatment of spinal deformity were unavailable. Regarding the 4 pediatric patients, there was no scoliosis or kyphosis in a 1-year-old patient; 10° lumbar scoliosis and 48° thoracic kyphosis in a 5-year-old patient; no scoliosis, but 45° thoracic kyphosis in a 14-year-old patient; and no scoliosis and unevaluated kyphosis in a 15-year-old patient. In the 13 adults (mean age 36 years old, range 20–57 years old), scoliosis was present in 11 (85%), with a mean thoracic kyphosis angle of 56° (19–86°), and the angle was $\geq 40^\circ$ in 10 (77%). Thus, the rate of complication by scoliosis in patients aged ≤ 15 years old was 25% and the thoracic kyphosis angle was $\geq 40^\circ$ in 50%, showing that the findings of spinal deformity were mostly derived from adults. However, this result is expected since spinal deformity in Cohen syndrome is not congenital, but is caused by reduced muscle tonus.

Abnormal connective tissue that leads to reduction of muscle tonus and tendon and ligament relaxation has been assumed to be a cause of Cohen syndrome, based on the presence of enhanced urinary hyaluronic acid secretion.¹¹⁾ Associated severe obesity may also cause scoliosis and kyphosis, which may promote progression of spinal deformity. These findings suggest two important points. First, since the incidence of complication by thoracic hyperkyphosis is high in children and adults in the past report, not only scoliosis but also progressive kyphosis and kyphoscoliosis should be of concern in Cohen syndrome. Second, the high rate of complication of spinal deformity in adults suggests that the risk of advancement of scoliosis in adulthood is high, even it remains mild in childhood, and spinal deformity may occur in adulthood. It is difficult to make a definite statement because of the small number of patients with Cohen syndrome and the absence of data based on observation of the condition over time. However, reduced muscle tonus and obesity may be risks for spinal deformity and careful course observation for adulthood spinal deformity is necessary, in addition to follow-up of childhood spinal deformity.

Regarding treatment, it may be appropriate to use brace treatment first, since no surgery for spinal deformity accompanying Cohen syndrome has previously been reported. However, the effect of and compliance with brace treatment may be poor because of severe obesity and mental retardation. Furthermore, deformity progressed within a short period in our patient and Kivitie-Kallio *et al.* also reported many adult cases with severe kyphosis. Thus, avoidance of surgery may not be possible, especially for kyphosis. In follow-up, conservative treatment should be performed carefully with attention to the risk of rapid progression of spinal deformity, and surgery should be considered before deformity progresses to a severe state. Anterior and posterior surgery was performed and favorable correction and bone fusion were achieved in this patient. However, posterior surgery without anterior surgery is often considered sufficient. Correction may be possible if osteotomy is concomitantly employed, but the policy of our department is to perform anterior and posterior surgery for severe symptomatic spinal deformity, provided that anterior surgery is applicable and that no problems with general anesthesia are identified in discussion with the anesthesia department before surgery. Prevention of a postoperative crankshaft phenomenon by segmental pedicle screw fixation in posterior surgery has been reported, but we selected a procedure that ensures release of the vertebral bodies and achieves anterior bone fusion. This choice was made because the case involved symptomatic kyphoscoliosis, for which detailed surgery has not been previously reported, and a favorable outcome was achieved.

Potential complications of general anesthesia should also be examined prior to surgery.^{6,20)} After surgery, the muscle relaxant effect of anesthesia may be protracted due to reduced muscle tonus, aspiration may occur because of restlessness due to mental retardation, and reintubation may be difficult because of facial malformation. Due to these risks, intubation was used for postoperative respiratory management for safety in our case, after discussion with anesthesiologists. Meng *et al.* reported a case of general anesthesia for MRI testing in a 28-year-old patient with Cohen syndrome and stated the importance of sufficient preparation with anticipation

KYPHOSCOLIOSIS IN COHEN SYNDROME

of potential problems, including consideration of tracheotomy.⁶⁾ We note that no problems with general anesthesia occurred during surgery in our patient, and postoperative respiratory management without intubation may have been possible because no delay in recovery from the muscle relaxant effect or arousal occurred. However, intraoperative anesthesia and postoperative respiratory management are important in a patient with Cohen syndrome because this condition is accompanied by obesity, facial malformation, reduced muscle tonus, and mental retardation. It is necessary to plan respiratory management carefully to avoid postoperative respiratory problem and achieve a favorable surgical outcome in patients with Cohen syndrome.

CONCLUSION

A case of kyphoscoliosis accompanying pediatric Cohen syndrome was initially treated with a brace, but the deformity progressed within a short period. One-staged anteroposterior corrective fusion was performed with a favorable outcome. Cohen syndrome is a rare disease that is frequently complicated by kyphosis and kyphoscoliosis, and these are likely to progress even in adulthood. Thus, surgery should be required before progression to the severe spinal deformity with careful attention to general anesthesia.

ACKNOWLEDGEMENTS

The authors thank Ms. Keiko Ogura for her assistance throughout this study. No funds were received in support of this work.

REFERENCES

- 1) Cohen MM, Jr., Hall BD, Smith DW, Graham CB, Lampert KJ. A new syndrome with hypotonia, obesity, mental deficiency, and facial, oral, ocular, and limb anomalies. *J Pediatr* 1973; 83: 280–4.
- 2) Chandler KE, Kidd A, Al-Gazali L, Kolehmainen J, Lehesjoki AE, Black GC, Clayton-Smith J. Diagnostic criteria, clinical characteristics, and natural history of Cohen syndrome. *J Med Genet* 2003; 40: 233–41.
- 3) Chandler KE, Moffett M, Clayton-Smith J, Baker GA. Neuropsychological assessment of a group of UK patients with Cohen syndrome. *Neuropediatrics* 2003; 34: 7–13.
- 4) Howlin P. Autistic features in Cohen syndrome: a preliminary report. *Dev Med Child Neurol* 2001; 43: 692–6.
- 5) Kivitie-Kallio S, Norio R. Cohen syndrome: essential features, natural history, and heterogeneity. *Am J Med Genet* 2001; 102: 125–35.
- 6) Meng L, Quinlan JJ, Sullivan E. The anesthetic management of a patient with Cohen syndrome. *Anesth Analg* 2004; 99: 697–8, table of contents.
- 7) Norio R, Raitta C, Lindahl E. Further delineation of the Cohen syndrome; report on chorioretinal dystrophy, leukopenia and consanguinity. *Clin Genet* 1984; 25: 1–14.
- 8) Kivitie-Kallio S, Eronen M, Lipsanen-Nyman M, Marttinen E, Norio R. Cohen syndrome: evaluation of its cardiac, endocrine and radiological features. *Clin Genet* 1999; 56: 41–50.
- 9) Karpf J, Turk J, Howlin P. Cognitive, language, and adaptive behavior profiles in individuals with a diagnosis of Cohen syndrome. *Clin Genet* 2004; 65: 327–32.
- 10) Kondo I, Nagataki S, Miyagi N. The Cohen syndrome: does mottled retina separate a Finnish and a Jewish type? *Am J Med Genet* 1990; 37: 109–13.
- 11) Okamoto N, Hatsukawa Y, Arai H, Goto M. Cohen syndrome with high urinary excretion of hyaluronic acid. *Am J Med Genet* 1998; 76: 387–8.
- 12) Kolehmainen J, Black GC, Saarinen A, Chandler K, Clayton-Smith J, Traskelin AL, Perveen R, Kivitie-Kallio S, Norio R, Warburg M, Fryns JP, de la Chapelle A, Lehesjoki AE. Cohen syndrome is caused by mutations in a novel gene, COH1, encoding a transmembrane protein with a presumed role in vesicle-mediated sorting

- and intracellular protein transport. *Am J Hum Genet* 2003; 72: 1359–69.
- 13) Mehes K, Kosztolanyi G, Kardos M, Horvath M. Cohen syndrome: a connective tissue disorder? *Am J Med Genet* 1988; 31: 131–3.
 - 14) Mochida GH, Rajab A, Eyaid W, Lu A, Al-Nouri D, Kosaki K, Noruzinia M, Sarda P, Ishihara J, Bodell A, Apse K, Walsh CA. Broader geographical spectrum of Cohen syndrome due to COH1 mutations. *J Med Genet* 2004; 41: e87.
 - 15) Atabek ME, Keskin M, Kurtoglu S, Kumandas S. Cohen syndrome with insulin resistance and seizure. *Pediatr Neurol* 2004; 30: 61–3.
 - 16) Kolehmainen J, Norio R, Kivitie-Kallio S, Tahvanainen E, de la Chapelle A, Lehesjoki AE. Refined mapping of the Cohen syndrome gene by linkage disequilibrium. *Eur J Hum Genet* 1997; 5: 206–13.
 - 17) Kivitie-Kallio S, Larsen A, Kajasto K, Norio R. Neurological and psychological findings in patients with Cohen syndrome: a study of 18 patients aged 11 months to 57 years. *Neuropediatrics* 1999; 30: 181–9.
 - 18) Massa G, Doods L, Vanderschueren-Lodeweyckx M. Growth hormone deficiency in a girl with the Cohen syndrome. *J Med Genet* 1991; 28: 48–50.
 - 19) Sack J, Friedman E. The Cohen syndrome in Israel. *Isr J Med Sci* 1986; 22: 766–70.
 - 20) Cavaliere F, Cormaci S, Cormaci M, Alberti A. [General anesthesia in Cohen syndrome. Report of a clinical case]. *Minerva Anestesiol* 1995; 61: 163–6.