

Drop episodes improved after tracheotomy: a case of Coffin-Lowry syndrome associated with obstructive sleep apnea syndrome

G. IMATAKA¹, I. NAKAJIMA², K. GOTO², W. KONNO²,
H. HIRABAYASHI², O. ARISAKA¹

¹Department of Pediatrics, Dokkyo Medical University School of Medicine, Tochigi, Japan

²Department of Otorhinolaryngology, Head and Neck Surgery, Dokkyo Medical University School of Medicine, Tochigi, Japan

Abstract. – Some cases of Coffin-Lowry syndrome recognized episodic drops and it tended to be intractable for medical treatment. We reported here a patient with the Coffin-Lowry syndrome associated with obstructive sleep apnea syndrome (OSAS). The patient had epileptic seizures and drop attacks only during night-time and it was not recognized during the daytime. His sleep-induced electroencephalogram was normal. At 12-years old of his age, his OSAS was worse, so we performed a tracheotomy. Notably after the operation, his epileptic episodes were disappeared.

Key Words:

Epilepsy, Convulsion, RSK2, RPS6KA3, OSAS.

Introduction

Coffin-Lowry syndrome (CLS) was first reported independently by Coffin et al¹ and Lowry et al² and established as a novel syndrome by Temtany et al³. CLS is an X-linked semi-dominant condition with dysmorphism, mental retardation, more severe in affected males than females due to mutations in the RSK2 protein kinase gene⁴ which was encoded ribosomal protein S6 kinase alpha 3⁵⁻⁸, partially related to epigenetic condition⁹ and other reasons¹⁰. Clinically problematic manifestations of CLS were mainly cardiovascular system^{11,12} and epileptic-like recurrent drop attack episodes⁴.

We report herein a clinical case of CLS associated obstructive sleep apnea syndrome (OSAS)¹³ whose epileptic drop attacks were disappeared after operated with a tracheotomy.

Case Report

This boy is the third-born child of non-consanguineous Japanese parents. At the time of birth, the mother was 27 and father 33 years old. There was no history of miscarriage and no major family history. He was born at 38 weeks gestation by normal vaginal delivery following spontaneous rupture of membranes. His Apgar score was 9 point at 1 minute. Birth weight and tall were 2014 g and 47.0 cm, respectively. His developmental milestones were turn-over at 6 months, sitting at 10 months and walking at 20 months. He could not say meaningful words. The intellectual and developmental delay was recognized, and he took G-banding congenital chromosomal examination, which was normal karyotype with 46, XY. Before 2-years old, he revealed complex febrile seizure with 5 times. Electroencephalogram and brain MRI exhibited normal findings. He started rehabilitation at 3 years. At 4-years of his age, he underwent to the examination of the neuro-pediatrician, and he was clinically diagnosed with CLS. After the age of 10 years, he tended to develop sleep disturbance because of sleep apnea during the night. He also often slept during daytime. Moreover, generalized tonic seizure with dyspnea lasting few minutes happened several times followings sleep apnea. He tends to recognized epileptic-like drop attack episodes during daytime. Therefore, he was visited at our hospital to consultation both seizures and sleep apnea situation at 12-years of his age. His tall stature was 139 cm and weighting 29 kg. Facial expression showed distant eyes, thick lips, small teeth, small jaw, large tonsils and ears protruding. His

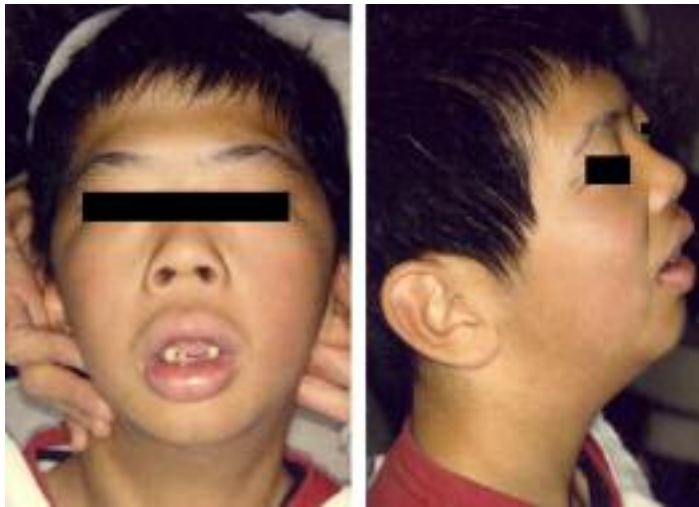

Figure 1. Facial expression of the patient.

hand is soft with big maple like shape. Fingers are fine-tipped shape. His personality is calm and often laughing (Figure 1). Sleep induced recorded electroencephalogram showed normal record. Sleep apnea monitoring test was performed and frequently developed sleep apnea over continue a 20 seconds. During episodes of sleep apnea, the monitoring of the oxygen saturation revealed that the level was below 80% (Figure 2).

His sleeping condition recognized tongue base subsidence. He was also diagnosed with CLS associated with obstructive sleep apnea syndrome

(OSAS). We consulted the otolaryngologist and he recommended tracheostomy. After the operation, OSAS was improved and his drop attacks were disappeared over the 5 years observation with no anti-epileptic medication.

Discussion

It is well known that some movement disorders, behavioral abnormalities, hyperreflexia, cataplexy, startle reaction, startle epilepsy, and stimulus-induced drop episodes occur in CLS¹⁴⁻¹⁶.

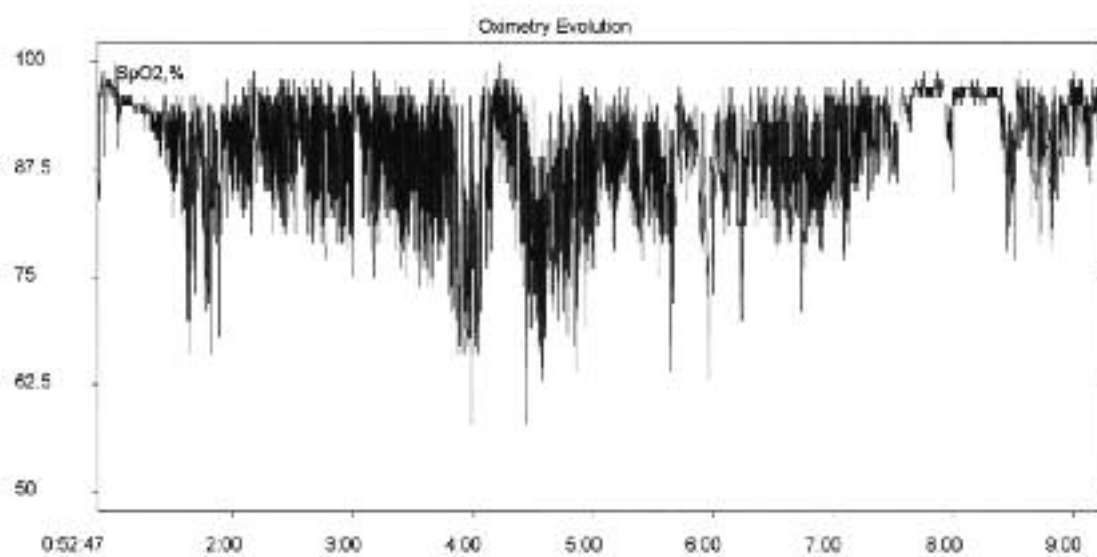


Figure 2. Sleep apnea monitoring during midnight of the patients.

Epileptic-like drop attacks tended to be intractable in CLS and considering some kind of treatment to this condition^{17,18}. Moreover, approximately 5% of CLS associated epilepsy and Gschwind et al¹⁶ reported a non-convulsive type of status epilepticus in CLS. Among these symptoms, epilepsy like drop episodes were stimulus-induced occurred and this mechanism was agued similar to another type of unusual startle response²⁰. Overall, treatment for these attacks in CLS is not established.

Our patient with CLS who has epileptic seizures and drop attacks was associated with OSAS and the patient's attacks disappeared after having performed tracheotomy. Wyler et al²¹ reported that treating the sleep apnea with permanent tracheotomy improved his generalized seizures in patients with OSAS-associated epilepsy. OSAS was well developed among the child patient with neurologically-impaired^{22,23} who had micro-jaw.

Conclusions

In this patient's clinical course, the tracheotomy produced good effects to his epileptic symptom. It was observed that the mechanisms for both drop attacks and epilepsy occur in patients with CLS associated with OSAS.

Conflict of Interest

The Authors declare that they have no conflict of interests.

References

- 1) COFFIN GS, SIRIS E, WEGIENKA LC. Mental retardation with osteocartilaginous anomalies. *Am J Dis Child* 1966; 112: 205-213.
- 2) LOWRY RB, MILLER JR, FRASSER C. A new dominant gene mental retardation syndrome: associated with small stature, tapering fingers, characteristic facies, and possible hydrocephalus. *Am J Dis Child* 1971; 121: 496-500.
- 3) TEMTAMY SA, MILLER JD, HUSSELS-MAUMENEE I. The Coffin-Lowry syndrome: an inherited facio-digital mental retardation syndrome. *J Pediatr* 1975; 86: 724-773.
- 4) NAKAMURA M, YAMAGATA T, MORI M, MOMOI MY. RSK2 gene mutations in Coffin-Lowry syndrome with drop episodes. *Brain Dev* 2005; 27: 114-117.

- 5) TOS T, ALP MY, AKSOY A, CEYLANER S, HANAUER A. A familial case of Coffin-Lowry syndrome caused by RPS6KA3 C.898C>T mutation associated with multiple abnormal brain imaging findings. *Genet Couns* 2015; 26: 47-52.
- 6) NISHIMOTO HK, HA K, JONES JR, DWIVEDI A, CHO HM, LAYMAN LC, KIM HG. The historical Coffin-Lowry syndrome family revisited: identification of two novel mutations of RPS6KA3 in three male patients. *Am J Med Genet A* 2014; 164A: 2172-2179.
- 7) ROJNUEANGNIT K, JONES JR, BASEHORE MJ, ROBIN NH. Classic phenotype of Coffin-Lowry syndrome in a female with stimulus-induced drop episodes and a genotype with preserved N-terminal kinase domain. *Am J Med Genet A* 2014; 164A: 516-21.
- 8) SENEL S, CEYLANER S, CEYLANER G, SAHIN AH, ANDRIEUX J, DELAUNOY JP. A novel mutation in the RPS6KA3 gene in a patient with Coffin-Lowry syndrome. *Genet Couns* 2011; 22: 21-24.
- 9) URDINGUIO RG, SANCHEZ-MUT JV, ESTELLER M. Epigenetic mechanisms in neurological diseases: genes, syndromes, and therapies. *Lancet Neurol* 2009; 8: 1056-1072.
- 10) KUECHLER A, BUYSSE K, CLAYTON-SMITH J, LE CAIGNEC C, DAVID A, ENGELS H, KOHLHASE J, MARI F, MORTIER G, RENIERI A, WIECZOREK D. Five patients with novel overlapping interstitial deletions in 8q22.2q22.3. *Am J Med Genet A* 2011; 155A: 1857-1864.
- 11) STÖLLBERGER C, FINSTERER J. Consider the neuro-cardiac continuum of Coffin-Lowry syndrome! *Am J Med Genet A* 2015; 167: 1954-1955.
- 12) MARTINEZ HR, NIU MC, SUTTON VR, PIGNATELLI R, VATTA M, JEFFERIES JL. Coffin-Lowry syndrome and left ventricular noncompaction cardiomyopathy with a restrictive pattern. *Am J Med Genet A* 2011; 155A: 3030-3034.
- 13) STEPHENSON JB, HOFFMAN MC, RUSSELL AJ, FALCONER J, BEACH RC, TOLMIE JL, McWILLIAM RC, ZUBERI SM. The movement disorders of Coffin-Lowry syndrome. *Brain Dev* 2005; 27: 108-113.
- 14) AMERICAN ACADEMY OF SLEEP MEDICINE: International classification of sleep disorders: Diagnostic and coding manual. 2nd ed., American Academy of Sleep Medicine, 2005.
- 15) FRYSSIRA H, KOUNTOUPI S, DELAUNOY JP, THOMAIDIS L. A female with Coffin-Lowry syndrome and "cataplexy." *Genet Couns* 2002; 13: 405-409.
- 16) GSCHWIND M, FOLETTI G, BAUMER A, BOTTANI A, NOVY J. Recurrent nonconvulsive status epilepticus in a patient with coffin-lowry syndrome. *Mol Syndromol* 2015; 6: 91-95.
- 17) O'RIRDAN S, PATTON M, SCHON F. Treatment of drop episodes in Coffin-Lowry syndrome. *J Neurol* 2006; 253: 109-110.
- 18) ARSLAN EA, CEYLANER S, TURANLI G. Stimulus-induced myoclonus treated effectively with clonazepam in genetically confirmed Coffin-Lowry

- syndrome. *Epilepsy Behav Case Rep* 2014; 2: 196-198.
- 19) HAVALIGI N, MATADEEN-ALI C, KHURANA DS, MARKS H, KOTHARE SV. Treatment of drop attacks in Coffin-Lowry syndrome with the use of sodium oxybate. *Pediatr Neurol* 2007; 37: 373-374.
- 20) CARABALLO R, TESI ROCHA A, MEDINA C, FEJERMAN N. Drop episodes in Coffin-Lowry syndrome: an unusual type of startle response. *Epileptic Disord* 2000; 2: 173-176.
- 21) WYLER AR, WEYMULLER EA JR. Epilepsy complicated by sleep apnea. *Ann Neurol* 1981; 19: 403-404.
- 22) ARNOLD JE, ALLPHIN AL. Sleep apnea in the neurologically-impaired child. *Ear Nose Throat J* 1993; 72: 80-81.
- 23) CAPDEVILA OS, KHEIRANDISH-GOZAL L, DAYYAT E, GOZAL D. Pediatric obstructive sleep apnea: complications, management, and long-term outcomes. *Proc Am Thorac Soc* 2008; 5: 274-282.