



Saudi J Anaesth. 2016 Jan-Mar; 10(1): 98–100.

PMCID: PMC4760052

doi: 10.4103/1658-354X.169485: 10.4103/1658-354X.169485

PMID: [26955318](https://pubmed.ncbi.nlm.nih.gov/26955318/)

## Anesthetic management of a patient with Weaver syndrome undergoing emergency evacuation of extra-dural hematoma: A case report and review of the literature

[RS Khokhar](#), [MSM Hajnour](#), [M Aqil](#), [AH Al-Saeed](#), and [S Qureshi](#)

Department of Anesthesiology, College of Medicine, King Saud University, Riyadh, Saudi Arabia

**Address for correspondence:** Dr. Rashid Saeed Khokhar, Department of Anesthesiology, College of Medicine, King Saud University, Riyadh, Saudi Arabia. E-mail: [rashidskhokhar@yahoo.com](mailto:rashidskhokhar@yahoo.com)

**Copyright** : © 2016 Saudi Journal of Anesthesia

This is an open access article distributed under the terms of the Creative Commons Attribution-NonCommercial-ShareAlike 3.0 License, which allows others to remix, tweak, and build upon the work non-commercially, as long as the author is credited and the new creations are licensed under the identical terms.

### Abstract

Weaver syndrome is a rare disorder of unknown etiology characterized by skeletal overgrowth, distinctive craniofacial and digital abnormalities and advanced bone age. In general, craniofacial abnormalities that cause difficulty with tracheal intubation may improve, worsen, or remain unchanged as craniofacial structures mature. Furthermore, there is an estimated risk in these children of  $\leq 1.09\%$  of rhabdomyolysis or malignant hyperpyrexia. We report a case of a boy with Weaver syndrome who underwent emergency evacuation of extra-dural hematoma under general anesthesia.

**Keywords:** Anesthesia, emergency, Weaver syndrome

### Introduction

Weaver syndrome is a rare congenital pediatric syndrome, characterized by accelerated growth tendency, advanced osseous maturation and distinct craniofacial, mental and respiratory features. The syndrome was described first by Weaver *et al.* in 1974[1] and since then only 40 cases have been reported and published in the up to date studies.

We report a case of a boy with Weaver syndrome who underwent emergency evacuation of extra-dural hematoma under general anesthesia. The objective of this report to inform the anesthesiologists regarding the anesthesia implication and review of the literature of this rare abnormality.

### Case Report

A 4-year-old male (weight 32 kg, height 130 cm) who was a diagnosed case of Weaver syndrome presented in pediatric emergency with history of the fall from stairs and suffered a head injury. The exact cause of the fall and head injury was not known, and it might be due to the developmental delay or hypotonia. Baseline laboratory investigations were within normal range with hemoglobin level of 9.5 g/dl. Hemodynamically he was stable with Glasgow coma scale of 13/15. Emergency computed tomography scan done which revealed an extra-dural hematoma in left parietotemporal region with a maximum thickness at 2.9 cm causing mass effect as subfalcine herniation and compression of the ipsilateral ventricle [Figure 1]. Hence, an emergent evacuation under general anesthesia planned.

His last oral intake was 2 h before the fall and a total fasting period of 6 h till the time of surgery. His birth history was not significant as he was delivered as full term, weighed 3.6 kg by spontaneous vaginal delivery. Later on, he was diagnosed to have hypotonia, developmental delay, and accelerated growth at age of 7 months. He was under regular follow-up with an endocrinologist and orthopedic surgeons. He underwent umbilical hernia repair at age of 6 months, and previous general anesthesia was un-eventful.

Keeping in view the risks due to of full stomach, malignant hyperpyrexia and difficult intubation, rapid sequence induction with rocuronium, and endotracheal intubation facilitated by use of glidescope and anesthesia maintenance with total intravenous anesthesia (TIVA) was planned. In the operating room after all application of standard noninvasive monitors, patient preoxygenated with 100% oxygen for 4-5 min and general anesthesia were induced with fentanyl 2 mcg/kg, propofol 2 mg/kg, rocuronium 0.15 mg/kg and cricoid pressure was applied, endotracheal intubation was accomplished with 4.5 mm uncuffed reinforced endotracheal tube (ETT). However, there was substantial leakage around the tube, and the ETT was replaced with 5.0 mm reinforced tube. Even after insertion of one bigger ETT, the leakage was still significant and finally we replace it with 5.5 mm internal diameter (ID) tube. Though with this size ETT there was still little audible leakage around the ETT but it was acceptable to us, and we consider it to be adequate size for him. A 20 gauge arterial cannula was inserted in left radial artery for invasive hemodynamic monitoring, and additional (18 gauge cannula) intravenous line was established on the left-hand dorsum.

Foley's catheter was also inserted to measure urine output. Anesthesia was maintained with infusions of propofol (range 6-10 mg/kg) and remifentanyl (range 0.05-0.2 mcg/kg/min), titrated to maintain mean heart rate and mean arterial pressure in range of 80-90/min and 70-90 mmHg, respectively. Lungs of the patient were ventilated with 50% oxygen in air mixture and the ventilator parameters were tidal volume 8-10 ml/kg and the respiratory rate adjusted to keep  $ETCO_2$  in the range 30-35 mmHg. Surgical procedure lasted for 2.5 h and intraoperative blood loss estimated to 500 ml and replaced by 350 ml packed red blood cells. Fluid balance was positive 50 ml. At the end of surgical procedure. The surgeon requested to keep the patient ventilated in the initial postoperative period, and the reinforced tube was exchanged with regular cuffed ETT of the same size. And the patient shifted to pediatric Intensive Care Unit (PICU). In PICU, his trachea was extubated after 24 h and after subsequent 2 days transferred to the surgical floor.

## Discussion

Weaver syndrome is a rare disorder of unknown etiology characterized by skeletal overgrowth, distinctive craniofacial and digital abnormalities and advanced bone age.[1] Presumed to have autosomal dominant inheritance, caused by mutation in the nuclear receptor-binding Su-var (NSD1 gene) which is located on 5q35. Infants are usually large for gestational age and may demonstrate alterations in muscle tone and delayed psychomotor development. Most cases have been sporadic, although some reports have described parent-to-child transmission demonstrating different patterns of inheritance.[2,3,4] Males as our patient are affected 3 times as frequently as females.[5]

In general, craniofacial abnormalities that cause difficulty with tracheal intubation may improve, worsen or remain unchanged as craniofacial structures mature.[6] The craniofacial features of Weaver syndrome become less prominent with advancing age, eventually making the diagnosis difficult in adulthood. Thus, it is possible that intubation difficulties in Weaver syndrome may diminish with advancing age, as has been described for other micrognathic syndromes like Pierre Robin sequence.[6]

As in spite of our prediction of difficulty in tracheal intubation, it was an easy intubation using glidescope. We found difficulty in selecting the appropriate size ETT due to him being overweight and taller than the ideal body weight. The ideal body weight and height should range between 15-20 kg and 95-110 cm, respectively. And our patient was almost 100% overweight and about 30% taller than ideal height. To avoid an intubation trauma, we attempted first intubation with an ideal ETT size was 4.5-5.0 mm for his age.

As reinforced tubes have larger outer diameter than the regular ETT of the same size, we selected 4.5 mm ID uncuffed ETT as our first choice, however, due to significant leakage we replaced it to bigger size and our final selection was 5.5 mm uncuffed reinforced tube.

The risk of anesthesia induced rhabdomyolysis or malignant hyperthermia (MH) in a floppy child with an uncertain diagnosis depends really on the stage of the investigation. Children presenting for muscle biopsy have a 10-20% chance of a positive finding, and around half of these have a diagnosis of muscular dystrophy. There is an estimated risk in these children of  $\leq 1.09\%$  of rhabdomyolysis or MH.[7] In these circumstances, volatile agents should be avoided. The safest anesthetic technique for these children is an intravenous induction, followed by maintenance with TIVA. Children with neuromuscular disease commonly present requiring anesthesia for diagnostic and surgical procedures. The specific diagnosis is very important to inform a logical plan for the anesthetic technique, ensuring awareness of possible triggers for serious adverse events. In cases where diagnosis is not clear or the exact incidence of malignant hyperpyrexia is not known, it is a safe approach to avoid succinylcholine and volatile anesthetics.

Patients with Weaver syndrome may be taking antiepileptic drugs, and we should consider the interaction between antiepileptic treatment and anesthetic drugs. In these patients, careful intraoperative positioning is needed because of skeletal deformities.

Regional anesthesia is not contraindicated but can be difficult to realize because of deformations and spasticity. Clinical assessment of functional capacity with a high suspicion of co-existing cardiac or respiratory disease combined with focused investigations allows assessment of risk. In all cases, there should be close perioperative monitoring and access to postoperative intensive care with ventilator support if required.

### Financial support and sponsorship

Nil.

### Conflicts of interest

There are no conflicts of interest.

### References

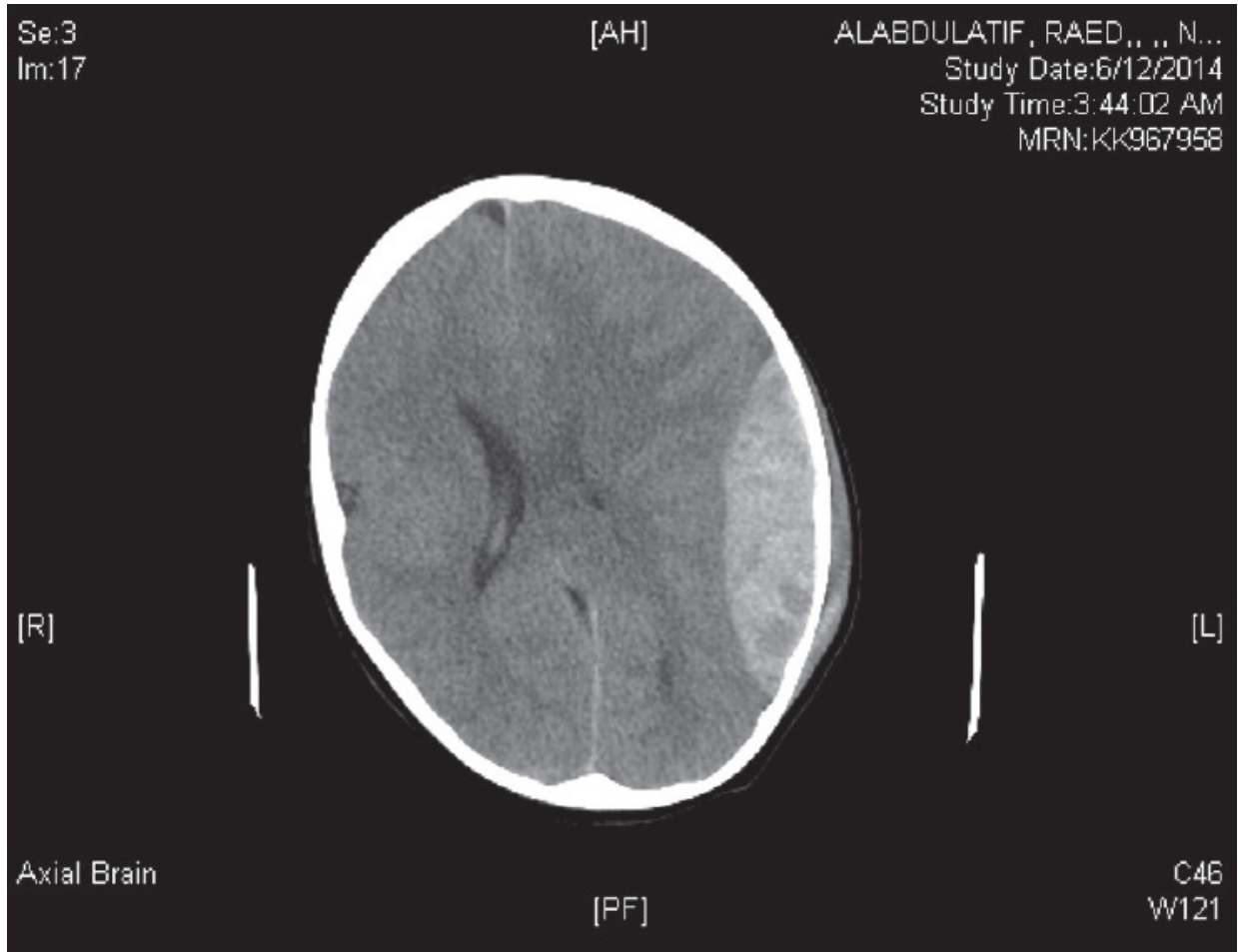
---

1. Weaver DD, Graham CB, Thomas IT, Smith DW. A new overgrowth syndrome with accelerated skeletal maturation, unusual facies, and camptodactyly. *J Pediatr.* 1974;84:547–52. [PubMed: 4366187]
2. Proud VK, Braddock SR, Cook L, Weaver DD. Weaver syndrome: Autosomal dominant inheritance of the disorder. *Am J Med Genet.* 1998;79:305–10. [PubMed: 9781912]
3. Opitz JM, Weaver DW, Reynolds JF., Jr The syndromes of Sotos and Weaver: Reports and review. *Am J Med Genet.* 1998;79:294–304. [PubMed: 9781911]
4. Derry C, Temple IK, Venkat-Raman K. A probable case of familial Weaver syndrome associated with neoplasia. *J Med Genet.* 1999;36:725–8. [PMCID: PMC1734420] [PubMed: 10507738]
5. Ardinger HH, Hanson JW, Harrod MJ, Cohen MM, Jr, Tibbles JA, Welch JP, et al. Further delineation of Weaver syndrome. *J Pediatr.* 1986;108:228–35. [PubMed: 2418189]
6. Nargozian C. The airway in patients with craniofacial abnormalities. *Paediatr Anaesth.* 2004;14:53–9. [PubMed: 14717875]
7. White RJ, Bass SP. Myotonic dystrophy and paediatric anesthesia. *Paediatr Anaesth.* 2003;13:94–102. [PubMed: 12562480]

### Figures and Tables

---

**Figure 1**



Computed tomography scan brain

---

Articles from Saudi Journal of Anaesthesia are provided here courtesy of **Wolters Kluwer -- Medknow Publications**