

# The 2017 International Classification of the Ehlers–Danlos Syndromes

**FRANSISKA MALFAIT,\* CLAIR FRANCOMANO, PETER BYERS, JOHN BELMONT, BRITTA BERGLUND, JAMES BLACK, LARA BLOOM, JESSICA M. BOWEN, ANGELA F. BRADY, NIGEL P. BURROWS, MARCO CASTORI, HELEN COHEN, MARINA COLOMBI, SERWET DEMIRDAS, JULIE DE BACKER, ANNE DE PAEPE, SYLVIE FOURNEL-GIGLEUX, MICHAEL FRANK, NEETI GHALI, CECILIA GIUNTA, RODNEY GRAHAME, ALAN HAKIM, XAVIER JEUNEMAITRE, DIANA JOHNSON, BIRGIT JUUL-KRISTENSEN, INES KAPFERER-SEEBACHER, HANADI KAZKAZ, TOMOKI KOSHO, MARK E. LAVALLEE, HOWARD LEVY, ROBERTO MENDOZA-LONDONO, MELANIE PEPIN, F. MICHAEL POPE, EYAL REINSTEIN, LEEMA ROBERT, MARIANNE ROHRBACH, LYNN SANDERS, GLENDA J. SOBEY, TIM VAN DAMME, ANTHONY VANDERSTEEN, CAROLINE VAN MOURIK, NICOL VOERMANS, NIGEL WHEELDON, JOHANNES ZSCHOCKE, AND BRAD TINKLE**

The Ehlers–Danlos syndromes (EDS) are a clinically and genetically heterogeneous group of heritable connective tissue disorders (HCTDs) characterized by joint hypermobility, skin hyperextensibility, and tissue fragility. Over the past two decades, the Villefranche Nosology, which delineated six subtypes, has been widely used as the standard for clinical diagnosis of EDS. For most of these subtypes, mutations had been identified in collagen-encoding genes, or in genes encoding collagen-modifying enzymes. Since its publication in 1998, a whole spectrum of novel EDS subtypes has been described, and mutations have been identified in an array of novel genes. The International EDS Consortium proposes a revised EDS classification, which recognizes 13 subtypes. For each of the subtypes, we propose a set of clinical criteria that are suggestive for the diagnosis. However, in view of the vast genetic heterogeneity and phenotypic variability of the EDS subtypes, and the clinical overlap between EDS subtypes, but also with other HCTDs, the definite diagnosis of all EDS subtypes, except for the hypermobile type, relies on molecular confirmation with identification of (a) causative genetic variant(s). We also revised the clinical criteria for hypermobile EDS in order to allow for a better distinction from other joint hypermobility disorders. To satisfy research needs, we also propose a pathogenetic scheme, that regroups EDS subtypes for which the causative proteins function within the same pathway. We hope that the revised International EDS Classification will serve as a new standard for the diagnosis of EDS and will provide a framework for future research purposes. © 2017 Wiley Periodicals, Inc.

**KEY WORDS:** classification; Ehlers–Danlos syndromes; genetic basis; collagen

**How to cite this article:** Malfait F, Francomano C, Byers P, Belmont J, Berglund B, Black J, Bloom L, Bowen JM, Brady AF, Burrows NP, Castori M, Cohen H, Colombi M, Demirdas S, De Backer J, De Paepe A, Fournel-Gigleux S, Frank M, Ghali N, Giunta C, Grahame R, Hakim A, Jeunemaitre X, Johnson D, Juul-Kristensen B, Kapferer-Seebacher I, Kazkaz H, Kosho T, Lavallee ME, Levy H, Mendoza-Londono R, Pepin M, Pope FM, Reinstein E, Robert L, Rohrbach M, Sanders L, Sobey GJ, Van Damme T, Vandersteen A, van Mourik C, Voermans N, Wheeldon N, Zschocke J, Tinkle B. 2017. The 2017 international classification of the Ehlers–Danlos syndromes. *Am J Med Genet Part C Semin Med Genet* 175C:8–26.

## INTRODUCTION

The Ehlers–Danlos syndromes (EDS) are a heterogeneous group of heritable

connective tissue disorders (HCTDs) characterized by joint hypermobility, skin hyperextensibility, and tissue fragility. The clinical and genetic

heterogeneity of this condition has long been recognized. The 1988 “Berlin Nosology” recognized 11 subtypes, defined by Roman numerals, based on

\*Correspondence to: Fransiska Malfait, Center for Medical Genetics, Ghent University Hospital, De Pintelaan 185, B-9000 Ghent, Belgium.  
E-mail: Fransiska.Malfait@UGent.be  
DOI 10.1002/ajmg.c.31552  
Article first published online in Wiley Online Library (wileyonlinelibrary.com).

clinical findings and mode of inheritance [Beighton et al., 1988]. The subjective interpretation of several semi-quantitative clinical signs, such as joint hypermobility, skin hyperextensibility, tissue fragility and bruising, however, led to clinical uncertainty, diagnostic confusion regarding the type of EDS and the inclusion of phenotypically similar conditions under the broad diagnosis of EDS. With the elucidation of the biochemical and molecular basis of many of these EDS types, a revised classification, the “Villefranche Nosology,” was published in 1998 [Beighton et al., 1998]. This classification delineated six subtypes, for which major and minor clinical criteria were defined, and which included the biochemical and molecular basis, when known. The Roman numerals were substituted by a descriptive name, which captured the characteristic manifestations of each type. One underlying assumption was that most, if not all, of these types of EDS were a consequence of alterations in fibrillar collagen genes or in genes that encoded collagen modifiers.

---

***With the elucidation of the biochemical and molecular basis of many of these EDS types, a revised classification, the “Villefranche Nosology,” was published in 1998. This classification delineated six subtypes, for which major and minor clinical criteria were defined, and which included the biochemical and molecular basis, when known.***

---

Over the past two decades the Villefranche Nosology has served its purpose and has been widely used as the standard for the clinical diagnosis of

EDS, and for clinical research on various aspects of these conditions. However, since its publication, a whole spectrum of novel EDS subtypes has been described, and with the advent of next-generation sequencing (NGS) facilities, mutations have been identified in an array of new genes, that are not always, at first sight, involved in collagen biosynthesis and/or structure. As such, the Villefranche classification is showing its age. Furthermore, in the persistent lack of a genetic defect, there is a dire need for a better clinical definition of the hypermobile type of EDS and its delineation from other hypermobility disorders. Therefore, we undertook a comprehensive review of the EDS-related literature, and, based on our findings, revised the EDS Classification.

### **THE 2017 INTERNATIONAL CLASSIFICATION FOR THE EHLERS-DANLOS SYNDROMES**

The new classification recognizes 13 subtypes, as outlined in Table I. After careful discussions whether to maintain a clinically orientated classification versus a genetic classification, we propose to maintain a clinical classification, in which the previously established descriptive names are maintained, since they are generally accepted and widely used in the medical, scientific and patient community. For newly defined EDS phenotypes, we propose a novel descriptor that captures the characteristic manifestations of the phenotype.

We included all phenotypes that present the basic clinical hallmarks of EDS, that is joint hypermobility, skin hyperextensibility and tissue fragility. In particular, such features should distinguish the redefined hypermobile type (hypermobile EDS, hEDS) from other joint hypermobility disorders (See also “A framework for the classification of Joint Hypermobility and Related Conditions” by Castori et al., this issue). Some of the phenotypes clinically overlap with other HCTDs, such as “myopathic EDS,” which is caused by heterozygous

or biallelic mutations in *COL12A1* (mEDS) and which clinically overlaps with Bethlem Myopathy, and “spondylodysplastic EDS” caused by biallelic *B3GALT6* mutations (spEDS-*B3GALT6*), which clinically overlaps with spondylo-epimetaphyseal dysplasia with joint laxity type I (SEMD-JL1). Since several patients with these conditions are clinically suspected to have a form of EDS, we believe that inclusion in the EDS classification is justified. This is also the case for Brittle Cornea Syndrome. We currently did not retain the filaminA-related periventricular nodular heterotopia (PVNH) with EDS-features within the classification, as the majority of patients primarily present with a neurological phenotype. A minority of patients has varying features of a HCTD, which may include life-threatening aneurysms, however, there is insufficient published data to reliably differentiate and prognosticate PVNH from PVNH-EDS. We recommend that in- or exclusion of these conditions in the EDS classification is reviewed in future years, when more information becomes available.

In line with the 1997 Villefranche Nosology, we propose a set of major and minor clinical criteria for each EDS subtype. A major criterion has high diagnostic specificity because it is present in the vast majority of the affected individuals and/or it is characteristic for the disorder and allows differentiation from other EDS subtypes and/or other HCTDs. A minor criterion is a sign of lesser diagnostic specificity, but its presence supports the diagnosis. For each of the subtypes, we defined minimal major  $\pm$  minor clinical criteria that are suggestive for the diagnosis of a specific subtype. However, in view of the vast genetic heterogeneity and phenotypic variability of the EDS subtypes, and the clinical overlap between many of these subtypes, but also with other HCTDs, the *definite diagnosis relies* for all subtypes, except hEDS, *on molecular confirmation* with identification of (a) causative variant(s) in the respective gene. A molecular diagnosis is extremely important for counseling

**TABLE I. Clinical Classification of the Ehlers–Danlos Syndromes, Inheritance Pattern, and Genetic Basis**

Clinical EDS subtype	Abbreviation	IP	Genetic basis	Protein
1 Classical EDS	cEDS	AD	Major: <i>COL5A1</i> , <i>COL5A1</i> Rare: <i>COL1A1</i> c.934C>T, p.(Arg312Cys)	Type V collagen Type I collagen
2 Classical-like EDS	clEDS	AR	<i>TNXB</i>	Tenascin XB
3 Cardiac-valvular	cvEDS	AR	<i>COL1A2</i> (biallelic mutations that lead to <i>COL1A2</i> NMD and absence of pro $\alpha$ 2(I) collagen chains)	Type I collagen
4 Vascular EDS	vEDS	AD	Major: <i>COL3A1</i> Rare: <i>COL1A1</i> c.934C>T, p.(Arg312Cys) c.1720C>T, p.(Arg574Cys) c.3227C>T, p.(Arg1093Cys)	Type III collagen Type I collagen
5 Hypermobility EDS	hEDS	AD	Unknown	Unknown
6 Arthrochalasia EDS	aEDS	AD	<i>COL1A1</i> , <i>COL1A2</i>	Type I collagen
7 Dermatosparaxis EDS	dEDS	AR	<i>ADAMTS2</i>	ADAMTS-2
8 Kyphoscoliotic EDS	kEDS	AR	<i>PLOD1</i> <i>FKBP14</i>	LH1 FKBP22
9 Brittle Cornea syndrome	BCS	AR	<i>ZNF469</i> <i>PRDM5</i>	ZNF469 PRDM5
10 Spondylodysplastic EDS	spEDS	AR	<i>B4GALT7</i> <i>B3GALT6</i> <i>SLC39A13</i>	$\beta$ 4GalT7 $\beta$ 3GalT6 ZIP13
11 Musculocontractural EDS	mcEDS	AR	<i>CHST14</i> <i>DSE</i>	D4ST1 DSE
12 Myopathic EDS	mEDS	AD or AR	<i>COL12A1</i>	Type XII collagen
13 Periodontal EDS	pEDS	AD	<i>C1R</i> <i>C1S</i>	C1r C1s

IP, inheritance pattern; AD, autosomal dominant; AR, autosomal recessive, NMD, nonsense-mediated mRNA decay.

purposes, as it allows confirmation of the precise diagnosis and gives information on inheritance pattern, recurrence risk and prognosis, and it may guide management. Moreover, it allows for the formation of homogeneous cohorts for research purposes, and future therapeutic interventions. Since the genetic basis of hEDS is still unknown, the diagnosis of this subtype rests on clinical findings, as delineated in the revised criteria for hEDS.

***In view of the vast genetic heterogeneity and phenotypic variability of the EDS subtypes, and the clinical overlap between many of these subtypes, but also with other HCTDs, the definite diagnosis relies for all subtypes, except hEDS, on***

***molecular confirmation with identification of (a) causative variant(s) in the respective gene.***

Molecular diagnostic strategies should rely on NGS technologies, which offer the potential for parallel sequencing of multiple genes. Targeted resequencing of a panel of genes, for example, *COL5A1*, *COL5A2*,

*COL1A1* and *COL1A2*, is a time- and cost-effective approach for the molecular diagnosis of the genetically heterogeneous EDS. When no mutation (or in case of an autosomal recessive condition only one mutation) is identified, this approach should be complemented with a copy number variant (CNV) detection strategy to identify large deletions or duplications, for example Multiplex Ligation-dependent Probe Amplification (MLPA), qPCR, or targeted array analysis. Alternatively, or in a second phase, whole exome sequencing (WES) or whole genome sequencing (WGS) and RNA sequencing techniques can be used, with data-analysis initially focusing on the genes of interest for a given EDS subtype. In absence of the identification of a causal mutation, this approach allows to expand the analysis to other genes within the genome. This is particularly interesting in view of the clinical overlap between EDS subtypes and with other HCTDs, and the observation that in an important proportion of EDS-patients, no pathogenic variants are identified in any of the known EDS-associated genes.

The interpretation of variants of uncertain significance (VUS), especially missense variants, should include correlation with the complete clinical phenotype. In keeping with the ACMG guidelines, variants that are supported by some evidence of pathogenicity (e.g., high *in silico* scores, presence in a functionally active domain) can be considered “likely pathogenic.” Familial segregation studies may help to interpret the pathogenicity of the variant, and for some genes, ultrastructural, biochemical and/or functional protein assays are available, as outlined below. Individuals harboring such a “likely pathogenic” variant should be followed clinically. Initial counseling for such patients should point out that the true significance of the variant will not be known until these additional tests are completed. In the longer term, assignment of pathogenicity is likely to be facilitated by data from large-scale genome-sequencing projects in patient and

control cohorts [Weerakkody et al., 2016].

For patients who fulfill the set of minimal clinical requirements for a specific EDS subtype, but (i) who have no access to molecular confirmation; (ii) in whom one or more VUS is/are identified in one the EDS subtype-specific genes; or (iii) in whom no causative variants are identified in any of the EDS-subtype-specific genes, a “provisional clinical diagnosis” of an EDS subtype can be made, and patients should be followed clinically. However, alternative diagnoses and hence expanded molecular testing should be considered.

### **PATHOGENETIC MECHANISMS UNDERLYING THE EHLERS-DANLOS SYNDROMES**

While the proposed clinically orientated classification aims to be user-friendly for the EDS non-specialist, and offers the affected patients and their family members a “descriptive” diagnosis that he or she can identify with, a genetic classification provides a better framework for research purposes and for the development of future treatment strategies. To satisfy both clinical and research needs, we propose, in addition to the clinical classification, a pathogenetic scheme, that regroups EDS subtypes for which the proteins, coded by the causative genes, function within the same pathway, and which are likely to have shared pathogenetic mechanisms, based on current knowledge (Table II). A similar regrouping of osteogenesis imperfecta (OI) subtypes by gene function was proposed and is widely adapted in clinical and in research settings.

### **CLASSIFICATION OF EDS**

#### **Classical EDS (cEDS)**

- Inheritance  
Autosomal dominant

- Major criteria
  1. Skin hyperextensibility<sup>1</sup> and atrophic scarring<sup>2</sup>
  2. Generalized joint hypermobility (GJH)<sup>3</sup>
- Minor criteria
  1. Easy bruising<sup>4</sup>
  2. Soft, doughy skin<sup>5</sup>
  3. Skin fragility (or traumatic splitting)
  4. Molluscoid pseudotumors<sup>6</sup>
  5. Subcutaneous spheroids<sup>7</sup>
  6. Hernia (or history thereof)
  7. Epicanthal folds<sup>8</sup>
  8. Complications of joint hypermobility (e.g., sprains, luxation/subluxation, pain, flexible flatfoot)
  9. Family history of a first degree relative who meets clinical criteria

<sup>1</sup>Skin extensibility should be measured by pinching and lifting the cutaneous and subcutaneous layers of the skin on the volar surface at the middle of the non-dominant forearm as described in Remvig et al. [2009]. Skin is hyperextensible if it can be stretched over a standardized cut-off in three of the following areas: 1.5 cm for the distal part of the forearms and the dorsum of the hands; 3 cm for neck, elbow, and knees.

<sup>2</sup>Abnormal scarring can range in severity. Most patients have extensive atrophic scars at a number of sites (Fig. 1). These can sometimes be haemosiderotic. A minority of patients are more mildly affected.

<sup>3</sup>GJH is evaluated according to the Beighton score; a Beighton score of  $\geq 5$  is considered positive for the presence of GJH (Fig. 2). Since laxity decreases with age, patients with a Beighton score  $< 5/9$  may be considered positive based on their historical observations (see “five-point questionnaire (5PQ)” (Table III).

<sup>4</sup>Easy bruising can occur anywhere on the body, including unusual sites. The pretibial area often remains stained with hemosiderin from previous bruises.

<sup>5</sup>Subjective abnormality of the skin texture is appreciable by touching the skin.

<sup>6</sup>Molluscoid pseudotumors are fleshy lesions associated with scars, found over pressure points (e.g., elbow, fingers).

<sup>7</sup>Subcutaneous spheroids (Fig. 1F) are small spherical hard bodies, frequently mobile, and palpable on the forearms and shins. Spheroids may be calcified and detectable radiologically.

<sup>8</sup>Epicanthal folds are often seen in childhood but may also be seen in adults.



TABLE II. (Continued)

Former nomenclature and other names	Villefranche nomenclature	New Nomenclature	OMIM condition	Locus	Gene	OMIM gene	Protein	IP
<b>GROUP E: Disorders of complement pathway</b>								
EDSVIII	EDS periodontitis	Periodontal EDS (pEDS)	130080	12p13.31	C1R C1S	613785 120580	C1r C1s	AD
<b>GROUP F: Disorders of intracellular processes<sup>a</sup></b>								
Spondylocheirodysplastic EDS	Spondylocheirodysplastic EDS (spEDS-SLC39A13)	Spondylocheirodysplastic EDS (spEDS-SLC39A13)	612350	11p11.2	SLC39A13	608735	ZIP13	AR
Brittle Cornea Syndrome	Brittle Cornea Syndrome (BCS)	Brittle Cornea Syndrome (BCS)	229200 614170	16q24 4q27	ZNF469 PRDM5	612078 614161	ZNF469 PRDM5	AR AR
<b>Unresolved forms of EDS</b>								
Hypermobile EDS III	Hypermobility type	Hypermobile EDS (hEDS)	130020	?	?		?	AD
<b>Conditions not included in EDS spectrum anymore</b>								
Occipital horn syndrome	/	/	304150	Xq21.1	ATP7A	300011	ATP7A	X-L
Fibronectin-deficient (EDS X)	/	/						AD
Familial Articular hypermobility (EDS XI)	/	/						AD
X-linked EDS with muscle hematoma (EDS V)	/	/						X-L
Filamin A related EDS with periventricular nodular heterotopia	/	/	300049	Xq28	FLNA	300017	Filamin A	X-L

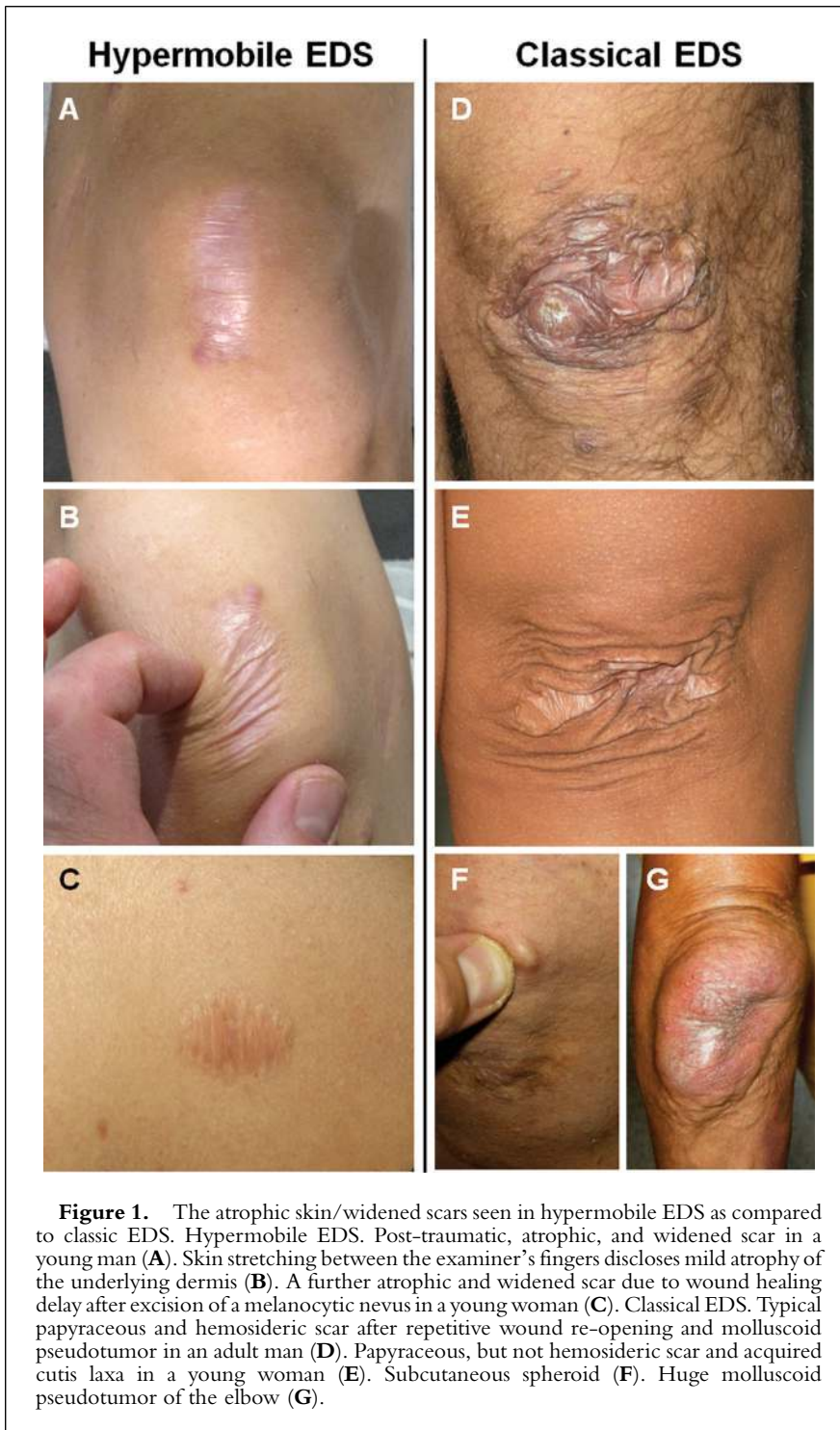IP, inheritance pattern; AD, autosomal dominant; AR, autosomal recessive; X-L, X-linked recessive.

<sup>a</sup>For EDS subtypes implemented in this category, the underlying pathophysiological mechanism is not readily understood, and classification within this subgroup is provisional, until further functional information becomes available.

- Minimal criteria suggestive for cEDS:
  - Major criterion (1): skin hyperextensibility and atrophic scarring
 Plus
  - Either major criterion (2): GJH
  - And/or: at least three minor criteria
 Confirmatory molecular testing is obligatory to reach a final diagnosis.
- Molecular basis
 

More than 90% of cEDS patients harbor a heterozygous mutation in one of the genes encoding type V collagen (*COL5A1* and *COL5A2*) [Symoens et al., 2012; Ritelli et al., 2013; Zoppi et al., 2015] (see also “Ehlers–Danlos Syndrome, Classical Type,” by Bowen et al., this issue). Rarely, specific mutations in the genes encoding type I collagen can be associated with a cEDS–phenotype. These include the heterozygous *COL1A1* c.934C>T, p.(Arg312Cys) substitution [Malfait et al., 2007a]. Patients harboring this mutation are particularly at risk for vascular rupture, whereas patients harboring other *COL1A1* arginine-to-cysteine substitutions are associated with other specific phenotypes (see also “Ehlers–Danlos Syndromes, Rare Types,” by Brady et al., this issue). Sodium Dodecyl Sulfate PolyAcrylamide Gel Electrophoresis (SDS PAGE) demonstrates the migration of an extra band in the cell fraction, and sometimes also in the medium fraction. This band, which disappears after reduction with β-mercaptoethanol, consists of disulfide-bonded α chains [Malfait et al., 2007b]. Furthermore, biallelic *COL1A2* mutations that lead to complete absence of the proα2(I) collagen chain may also present with a classical EDS-like phenotype, but these patients are at risk for developing severe cardiac–valvular problems. Moreover, inheritance of this condition is autosomal recessive (see also “Cardiac–valvular EDS,” below, and “Ehlers–Danlos Syndromes, Rare Types,” by Brady et al., this issue). SDS PAGE demonstrates complete absence of (pro-) α2 chains of type I (pro) collagen extracted from dermis [Schwarze et al., 2004; Malfait et al., 2006].
- Verification of clinical diagnosis
 

Molecular screening by means of targeted resequencing of a gene panel



**Figure 1.** The atrophic skin/widened scars seen in hypermobile EDS as compared to classic EDS. Hypermobile EDS. Post-traumatic, atrophic, and widened scar in a young man (A). Skin stretching between the examiner's fingers discloses mild atrophy of the underlying dermis (B). A further atrophic and widened scar due to wound healing delay after excision of a melanocytic nevus in a young woman (C). Classical EDS. Typical papyraceous and hemosideric scar after repetitive wound re-opening and molluscoid pseudotumor in an adult man (D). Papyraceous, but not hemosideric scar and acquired cutis laxa in a young woman (E). Subcutaneous spheroid (F). Huge molluscoid pseudotumor of the elbow (G).

**More than 90% of cEDS patients harbor a heterozygous mutation in one of the genes encoding type V collagen (COL5A1 and COL5A2).**

that includes at least the *COL5A1*, *COL5A2*, *COL1A1*, and *COL1A2* genes, or by WES or WGS, is indicated. When no mutation is identified, this approach should be complemented with a CNV detection strategy to identify large deletions or duplications.

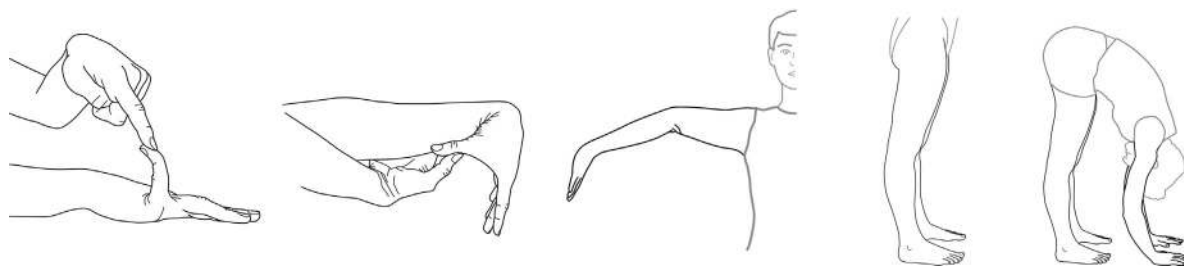
In case of unavailability of genetic testing, transmission electron microscopy (TEM) findings of collagen flowers on skin biopsy can support the clinical diagnosis, but cannot confirm it.

Absence of these confirmatory findings does not exclude the diagnosis, as specific types of mutations (e.g., deep intronic mutations) may go undetected by standard diagnostic molecular techniques; however, alternative diagnoses should be considered in the absence of (a) *COL5A1*, *COL5A2*, *COL1A1*, or *COL1A2* mutation(s).

### Classical-Like EDS (cEDS)

- Inheritance  
Autosomal Recessive
- Major criteria
  1. Skin hyperextensibility,<sup>9</sup> with velvety skin texture and absence of atrophic scarring
  2. GJH<sup>9</sup> with or without recurrent dislocations (most commonly shoulder and ankle)
  3. Easy bruisable skin/spontaneous ecchymoses
- Minor criteria
  1. Foot deformities: broad/plump fore-foot, brachydactyly with excessive skin; pes planus; hallux valgus; piezogenic papules
  2. Edema in the legs in absence of cardiac failure
  3. Mild proximal and distal muscle weakness
  4. Axonal polyneuropathy
  5. Atrophy of muscles in hands and feet
  6. Acrogeric hands, mallet finger(s), clinodactyly, brachydactyly
  7. Vaginal/uterus/rectal prolapse
- Minimal criteria suggestive for cEDS:
  - All three major criteria AND a family history compatible with autosomal recessive transmission.
 Confirmatory molecular testing is obligatory to reach a final diagnosis.

<sup>9</sup>For definitions of GJH and skin hyperextensibility, see criteria for "Classical EDS."



**Figure 2.** The Beighton scoring system. Each joint is measured using a goniometer and each side is scored independently as outlined [Juul-Kristensen et al., 2007]. **(A)** With the palm of the hand and forearm resting on a flat surface with the elbow flexed at  $90^\circ$ , if the metacarpal-phalangeal joint of the fifth finger can be hyperextended more than  $90^\circ$  with respect to the dorsum of the hand, it is considered positive, scoring 1 point. **(B)** With arms outstretched forward but hand pronated, if the thumb can be passively moved to touch the ipsilateral forearm it is considered positive scoring 1 point. **(C)** With the arms outstretched to the side and hand supine, if the elbow extends more than  $10^\circ$ , it is considered positive scoring 1 point. **(D)** While standing, with knees locked in genu recurvatum, if the knee extends more than  $10^\circ$ , it is considered positive scoring 1 point. **(E)** With knees locked straight and feet together, if the patient can bend forward to place the total palm of both hands flat on the floor just in front of the feet, it is considered positive scoring 1 point. The total possible score is 9. Figure courtesy of Dr. Juul-Kirstensen.

- Molecular basis

cEDS is caused by a complete lack of Tenascin XB (TNXB) due to biallelic *TNXB* mutations, that lead to nonsense-mediated mRNA decay, or biallelic deletion of *TNXB*. As a result the TNX protein is completely absent. *TNXB* is the only gene associated with cEDS.

- Verification of diagnosis

Molecular analysis of the *TNXB* gene should be used as the standard confirmatory test. Difficulties in DNA testing are related to the presence of a pseudogene (*TNXA*), which is more than 97% identical to the 3' end of *TNXB* (exons 32–44). With the only exception of exon 35, which partially shows a *TNXB*-specific sequence, exon and intron sequences in this region are identical or almost identical in both the gene and the pseudogene. This has implications both for sequencing and deletion/duplication analysis.

For sequence analysis of *TNXB*, two approaches are recommended.

1. Sanger sequencing of the entire *TNXB* gene.
2. Next-generation sequencing of *TNXB* + Sanger sequencing of the pseudogene region.

Both approaches will require sequence analysis of the pseudogene-homolog region in a few large multi-exons amplicons.

If no or only one causative mutation is identified by classic sequencing, additional methods that allow detection of large deletions/duplications should be added. So far no method is able to specifically detect *TNXB* CNVs in the highly homologous exons 32–34 and 36–44. CNV analysis of exon 35 is currently used to detect deletions in this region, including the 30 kb deletion previously described by Schalkwijk et al. [2001].

TNX, a large 450 kDa extracellular matrix glycoprotein, secreted by skin fibroblasts, can be detected with antibodies directed against its carboxyterminal end. Patients with cEDS are completely depleted of the TNX protein in serum. We refer to the paper of Schalkwijk et al. [2001] for more detailed information concerning the used method to detect TNX.

Absence of these confirmatory findings does not exclude the diagnosis, as specific types of mutations (e.g., deep intronic mutations) may go undetected by standard diagnostic molecular techniques; however, alternative diagnoses should be considered in the absence of a *TNXB* mutation.

### Cardiac-Valvular EDS (cvEDS)

- Inheritance

Autosomal recessive

- Major criteria

1. Severe progressive cardiac-valvular problems (aortic valve, mitral valve)<sup>10</sup>
2. Skin involvement: skin hyperextensibility,<sup>11</sup> atrophic scars, thin skin, easy bruising
3. Joint hypermobility (generalized or restricted to small joints)

- Minor criteria

1. Inguinal hernia
2. Pectus deformity (especially excavatum)
3. Joint dislocations
4. Foot deformities: pes planus, pes planovalgus, hallux valgus

- Minimal criteria suggestive for cvEDS:

- Major Criterion (1): severe progressive cardiac-valvular problems
  - AND a family history compatible with autosomal recessive inheritance
- Plus
- Either: one other major criterion
  - And/or: at least two minor criteria
- Confirmatory molecular testing is obligatory to reach a final diagnosis.

- Molecular basis

cvEDS is caused by a complete lack of the pro $\alpha$ 2-chain of type I collagen due to biallelic *COL1A2* mutations, that

<sup>10</sup>The cardiac-valvular problems were reported in all affected adult individuals, but were absent in the two reported children (both <10 years of age).

<sup>11</sup>For definition of skin hyperextensibility, see criteria for “Classical EDS.”



lead to nonsense-mediated mRNA decay. *COL1A2* is the only gene associated with cvEDS.

- Verification of diagnosis  
Molecular screening by Sanger sequencing of *COL1A2*, or targeted resequencing of a gene panel that includes *COL1A2* is indicated. When no mutation is identified, this approach should be complemented with a CNV detection strategy to identify large deletions or duplications.

In case of unavailability of genetic testing, SDS PAGE demonstrates total absence of (pro-)  $\alpha 2(I)$  collagen chains.

Whereas absence of these confirmatory biochemical findings allows to exclude the diagnosis of cvEDS, absence of confirmatory genetic findings does not exclude the diagnosis, as specific types of mutations (e.g., deep intronic mutations) may go undetected by standard diagnostic molecular techniques.

### Vascular EDS (vEDS)

- Inheritance  
Autosomal dominant
- Major criteria
  1. Family history of vEDS with documented causative variant in *COL3A1*
  2. Arterial rupture at a young age
  3. Spontaneous sigmoid colon perforation in the absence of known diverticular disease or other bowel pathology
  4. Uterine rupture during the third trimester in the absence of previous C-section and/or severe peripartum perineum tears
  5. Carotid-cavernous sinus fistula (CCSF) formation in the absence of trauma
- Minor criteria
  1. Bruising unrelated to identified trauma and/or in unusual sites such as cheeks and back
  2. Thin, translucent skin with increased venous visibility
  3. Characteristic facial appearance
  4. Spontaneous pneumothorax
  5. Acrogeria
  6. Talipes equinovarus
  7. Congenital hip dislocation

8. Hypermobility of small joints
9. Tendon and muscle rupture
10. Keratoconus
11. Gingival recession and gingival fragility
12. Early onset varicose veins (under age 30 and nulliparous if female)

- Minimal criteria suggestive for vEDS:  
A family history of the disorder, arterial rupture or dissection in individuals less than 40 years of age, unexplained sigmoid colon rupture, or spontaneous pneumothorax in the presence of other features consistent with vEDS should all lead to diagnostic studies to determine if the individual has vEDS. Testing for vEDS should also be considered in the presence of a combination of the other “minor” clinical features listed above.

---

***A family history of the disorder, arterial rupture, or dissection in individuals less than 40 years of age, unexplained sigmoid colon rupture, or spontaneous pneumothorax in the presence of other features consistent with vEDS should all lead to diagnostic studies to determine if the individual has vEDS.***

---

Even for experienced clinicians the clinical diagnosis of vEDS may be difficult. Because of implications for treatment, natural history, and recurrence risk, the diagnosis of vEDS rests on the identification of a causative variant in one allele of *COL3A1*.

- Molecular basis  
Patients with vEDS typically harbor a heterozygous mutation in the *COL3A1* gene, encoding type III collagen, with the rare exception of specific heterozygous arginine-to-cysteine substitution mutations in *COL1A1* (c.934C>T, p.Arg312Cys; c.1720C>T, p.Arg574Cys and c.3277C>T, p.Arg1093Cys) that

are also associated with vascular fragility, mimicking *COL3A1*-vEDS [Malfait et al., 2007b], (see also “Ehlers–Danlos Syndrome, Rare Types,” by Brady et al., this issue).

In very rare instances, biallelic pathogenic variants in *COL3A1* may be identified.

- Verification of clinical diagnosis  
Molecular screening by Sanger sequencing of *COL3A1*, or targeted resequencing of a gene panel that includes *COL3A1* and *COL1A1* (the latter to identify the above-listed arginine-to-cysteine substitution mutations) is indicated. When no mutation is identified, this approach should be complemented with a CNV detection strategy to identify large deletions or duplications.

Absence of these confirmatory findings does not exclude the diagnosis, as specific types of mutations (e.g., deep intronic mutations) may go undetected by standard diagnostic molecular techniques; however, alternative diagnoses should be considered in the absence of a *COL3A1* or *COL1A1* mutation.

### Hypermobility EDS (hEDS)

- Inheritance  
Autosomal dominant
- Molecular basis  
Unknown
- Clinical diagnosis  
The diagnosis of hEDS remains clinical as there is yet no reliable or appreciable genetic etiology to test for in the vast majority of patients. This, in part, likely reflects genetic heterogeneity. In addition, the syndromic presentation may vary according to age and gender. There is also a clinical spectrum ranging from asymptomatic joint hypermobility, through “non-syndromic” hypermobility with secondary manifestations, to hEDS (see “A Framework for the Classification of Joint Hypermobility and Related Conditions” by Castori et al., this issue). A diagnosis of hEDS should be assigned only in those who meet all of the criteria described below, which should help to reduce heterogeneity and facilitate efforts to discover the

underlying genetic cause(s) of the syndrome which, in turn, may help clinical management. Since there is currently no “gold standard” laboratory test to confirm or refute the diagnosis, we anticipate that future research will lead to further revisions of these clinical criteria necessitating regular review of the relevant medical literature. It is also imperative, as this is a clinical diagnosis, to be relatively confident that the patient’s presentation does not represent one of the many other disorders of connective tissue. Therefore, the clinician should be experienced at the physical examination described herein as well the historical and clinical presentation of other HCTD and their diagnoses.

The clinical diagnosis of hEDS needs the simultaneous presence of criteria 1 AND 2 AND 3. Specific annotations and further explanations (i.e., footnotes [FN]) are reported for select features.

### **Criterion 1: Generalized Joint Hypermobility (GJH)**

To date, the Beighton score (Fig. 2) is the most recognized tool for assessing GJH (see “Measurement Properties of Clinical Assessment Methods for Classifying Generalized Joint Hypermobility—a Systematic Review” by Juul-Kristensen et al., *this issue*). According to the original definition of the Beighton score and its subsequent incorporation into the Villefranche nosology for the hEDS, the cut-off for the definition of GJH is  $\geq 5$  points out of 9. However, joint range of motion decreases with age [Soucie et al., 2011; McKay et al., 2016] and there is an inverse relationship between age at ascertainment and the Beighton score [Remvig et al., 2007], so the cut-off of five may prompt an over-diagnosis in children and an under-diagnosis among adults and elders. As GJH is considered a prerequisite for the diagnosis of hEDS and GJH is a constitutional trait strongly influenced by acquired and inherited conditions (e.g., sex, age, past-traumas, co-morbidities, etc.), some minor adaptations to the cut-off of five should be considered for the diagnosis of hEDS. The Committee on behalf of

the International Consortium on the Ehlers–Danlos Syndromes proposes  $\geq 6$  for pre-pubertal children and adolescents,  $\geq 5$  for pubertal men and women up to the age of 50, and  $\geq 4$  for those  $>50$  years of age for hEDS. This may vary from other types of EDS but such types have confirmatory testing.

---

***According to the original definition of the Beighton score and its subsequent incorporation into the Villefranche nosology for the hEDS, the cut-off for the definition of GJH is  $\geq 5$  points out of 9. However, joint range of motion decreases with age and there is an inverse relationship between age at ascertainment and the Beighton score, so the cut-off of five may prompt an over-diagnosis in children and an under-diagnosis among adults and elders.***

---

In individuals with acquired joint limitations (past surgery, wheelchair,

amputations, etc.) affecting the Beighton score calculation, the assessment of GJH may include historical information using the five-point questionnaire (5PQ) (Table III) [Hakim and Grahame, 2003; Mulvey et al., 2013], although this has not been validated in children (see “Measurement Properties of Clinical Assessment Methods for Classifying Generalized Joint Hypermobility—a Systematic Review” by Juul-Kristensen et al., *this issue*). If the Beighton score is 1 point below the age- and sex-specific cut-off AND the 5PQ is ‘positive’ (= at least two positive items), then a diagnosis of GJH can be made.

For patients with lower Beighton scores, the assessment of other joints is often considered, including temporomandibular joint, shoulder, hip, foot, wrist, ankle, and other digits. Increased ankle and wrist dorsiflexion, increased internal and external hip rotation, and pes planus have been correlated with Beighton score [Smits-Engelsman et al., 2011] However, similar concerns about age, gender, and environmental influences as well as measurement methodology and reliable cut-off values, limit such analysis as too subjective in the determination of GJH. Therefore, the use of such measurements cannot be factored into a diagnostic algorithm at this time. Obviously, more information regarding the assessment methodology (ies) in the determination of GJH is needed (see “Measurement Properties of Clinical Assessment Methods for Classifying Generalized Joint Hypermobility—a

**TABLE III. The Five-Point Questionnaire. Adapted From [Grahame and Hakim, 2003]**

1. Can you now (or could you ever) place your hands flat on the floor without bending your knees?
  2. Can you now (or could you ever) bend your thumb to touch your forearm?
  3. As a child, did you amuse your friends by contorting your body into strange shapes or could you do the splits?
  4. As a child or teenager, did your shoulder or kneecap dislocate on more than one occasion?
  5. Do you consider yourself “double-jointed”?
- A “yes” answer to two or more questions suggests joint hypermobility with 80–85% sensitivity and 80–90% specificity

*Systematic Review*” by Juul-Kristensen et al., this issue).

Lastly, the use of the Beighton scoring system is meant to be a diagnostic screening method. It is understood that gender, age, ethnicity, strength training, stretching exercises, and warming up all affect JH and therefore GJH. However, muscular overcompensation, injury and surgery can cause either joint hypermobility or hypomobility. Muscular overcompensation, such as tight hamstrings, can affect the degree of knee extension and lumbar flexion negatively, while stretching exercises and warming up affects positively. Injury can destabilize a joint or alternatively reduce movement. Surgery can similarly affect a joint. For example, a person with lumbar spine fusion may not be able to have a “positive” forward spinal flexion for Beighton scoring. There is a temptation by clinicians to consider this a positive score but without current ability or historical demonstration, it should be scored negative. An argument could be made to invalidate spinal flexion scoring thus the total score would be eight and not nine. However, it is not known if the numerator (determinant of GJH) should be adjusted in this situation. In theory, this makes sense but what is the appropriate cut-off? Therefore, like any clinical tool, there is some subjectivity and this is a guideline not to replace the judgment of the experienced clinician; however, standardization of performance procedures is required. One may want to label such persons as having “probable GJH” but at the present time, “probable GJH” should not be considered an alternative of the objectively diagnosed GJH (as described above) into the diagnostic flow-chart of hEDS. Stronger scrutiny of phenocopies should be contemplated.

**Criterion 2: Two or More Among the Following Features (A–C) MUST Be Present (for Example: A and B; A and C; B and C; A and B and C)**

Feature A: systemic manifestations of a more generalized connective tissue

disorder (a total of five must be present)<sup>12</sup>

1. Unusually soft or velvety skin<sup>13</sup>
2. Mild skin hyperextensibility<sup>14</sup>
3. Unexplained striae such as striae distensae or rubrae at the back, groins, thighs, breasts and/or abdomen in adolescents, men or prepubertal women without a history of significant gain or loss of body fat or weight
4. Bilateral piezogenic papules of the heel<sup>15</sup>
5. Recurrent or multiple abdominal hernia(s) (e.g., umbilical, inguinal, crural)

<sup>12</sup>If marfanoid features are present, consider other conditions such as: Marfan syndrome, Loeys–Dietz syndrome, congenital contractural arachnodactyly, Shprintzen–Goldberg syndrome, Stickler syndrome, Homocystinuria, multiple endocrine neoplasia type 2B, and the familial thoracic aortic aneurysmal disorders [Pyeritz and Loeys, 2012]. Molecular testing for many of these conditions is clinically available.

<sup>13</sup>While skin softness and texture remain subjective, it is often very notable in some individuals and useful when present but not quantifiable; we therefore recommend a high threshold for positivity.

<sup>14</sup>Skin extensibility as measured by pinching and lifting the cutaneous and subcutaneous layers of the skin on the volar surface at the middle of the non-dominant forearm as described in Remvig et al. [2009]. Skin extensibility of >1.5 cm is considered the upper end of normal. It is likely that the hyperextensibility of the skin in hEDS overlaps significantly with that of “normal” skin. Therefore, extensibility of more than 1.5 cm is “positive.” If extensibility >2.0 cm is present especially in combination with other cutaneous features, such as papyraceous scars, molluscoid pseudotumors and/or subcutaneous spheroids, consider other EDS types as possible alternative diagnoses (mainly cEDS and classical-like EDS).

<sup>15</sup>Piezogenic papules are herniations of subcutaneous fat often demonstrable in the heel upon standing (Fig. 3). It is considered uncommon in children but can be found in adults with history of prolonged standing (occupational), marathon runners, or weightlifters [Pope and Hamm, 2013] However, in a sex- and age-matched study of 29 Dutch EDS patients, piezogenic papules were found in 34.5% but none in the control group [Kahana et al., 1987].

6. Atrophic scarring involving at least two sites and without the formation of truly papyraceous and/or hemosideric scars as seen in classical EDS<sup>16</sup>
7. Pelvic floor, rectal, and/or uterine prolapse in children, men or nulliparous women without a history of morbid obesity or other known predisposing medical condition
8. Dental crowding and high or narrow palate<sup>17</sup>
9. Arachnodactyly, as defined in one or more of the following: (i) positive wrist sign (Steinberg sign) on both sides; (ii) positive thumb sign (Walker sign) on both sides
10. Arm span-to-height  $\geq 1.05$
11. Mitral valve prolapse (MVP) mild or greater based on strict echocardiographic criteria<sup>18</sup>
12. Aortic root dilatation with Z-score > +2

Feature B: positive family history, with one or more first degree relatives

<sup>16</sup>Atrophic scarring is defined as scars from linear traumatic lacerations or single-surgery that are unusually shallow (i.e., thin and sunken) and/or wider than the original wound due to impaired repair and subsequent dermal hypotrophy. Atrophic scars as the result of multiple incisions, wound infections, or inflammatory conditions (such as viral infections, cystic acne, etc.) are not to be considered. Elliptical incisions (e.g., for removal of nevi) may be difficult to assess without knowing the size of the original wound. True skin fragility, such as the propensity to have an open wound due to trivial trauma, is not a typical feature of hEDS. Atrophic scarring in hEDS is mildly to moderately different from that usually considered typical of cEDS (Fig. 1).

<sup>17</sup>Includes history of dental crowding or orthodontic intervention(s) to correct such problems. Both conditions must be positive to meet this criterion.

<sup>18</sup>Some studies show no increase in the frequency of clinically significant MVP [Dolan et al., 1997; McDonnell et al., 2006; Atzinger et al., 2011] and others show an MVP frequency of 28–67% among hEDS patients [Camerota et al., 2014; Kozanoglu et al., 2016]. This feature is included in the diagnostic criteria because it can be a marker of connective tissue laxity, but is usually not clinically significant in patients with hEDS.

independently meeting the current diagnostic criteria for hEDS.

Feature C: musculoskeletal complications (must have at least one):

1. Musculoskeletal pain in two or more limbs, recurring daily for at least 3 months
2. Chronic, widespread pain for  $\geq 3$  months
3. Recurrent joint dislocations or frank joint instability, in the absence of trauma (a or b)<sup>19</sup>
  - a. Three or more atraumatic dislocations in the same joint or two or more atraumatic dislocations in two different joints occurring at different times
  - b. Medical confirmation of joint instability at two or more sites not related to trauma<sup>20</sup>

### Criterion 3: All the Following Prerequisites MUST Be Met

1. Absence of unusual skin fragility, which should prompt consideration of other types of EDS
2. Exclusion of other heritable and acquired connective tissue disorders, including autoimmune rheumatologic conditions. In patients with an acquired connective tissue disorder (e.g., lupus, rheumatoid arthritis, etc.), additional diagnosis of hEDS requires meeting both Features A and B of Criterion 2. Feature C of Criterion 2 (chronic pain and/or instability) cannot be counted towards a diagnosis of hEDS in this situation.
3. Exclusion of alternative diagnoses that may also include joint hypermobility by means of hypotonia and/or connective tissue laxity. Alternative diagnoses and diagnostic categories include, but are not limited to, neuromuscular

disorders (e.g., myopathic EDS, Bethlem myopathy), other HCTD (e.g., other types of EDS, Loeys–Dietz syndrome, Marfan syndrome), and skeletal dysplasias (e.g., OI). Exclusion of these considerations may be based upon history, physical examination, and/or molecular genetic testing, as indicated.

#### • General comment

Many other features are described in hEDS but most are not sufficiently specific nor sensitive at the moment to be included in formal diagnostic criteria (see “*Hypermobile Ehlers–Danlos Syndrome (a.k.a. Ehlers–Danlos Syndrome Type III and Ehlers–Danlos syndrome hypermobility type): Clinical Description, and Natural History*” by Tinkle et al., *this issue*). These include but are not limited to: sleep disturbance, fatigue, postural orthostatic tachycardia, functional gastrointestinal disorders, dysautonomia, anxiety, and depression. These other systemic manifestations may be more debilitating than the joint symptoms, often impair functionality and quality of life, and should always be determined during clinical encounters. While they are not part of the diagnostic criteria, the presence of such systemic manifestations may prompt consideration of hEDS in the differential diagnosis. Future research will need to focus on such symptoms to validate any association with hEDS, describe sub-groups or sub-phenotypes, and be focused on evidence-based management of the symptoms in the context of hEDS.

### Arthrochalasia EDS (aEDS)

- Inheritance  
Autosomal dominant
- Major criteria
  1. Congenital bilateral hip dislocation<sup>21</sup>

<sup>21</sup>All reported aEDS patients had congenital bilateral hip dislocation. One unreported molecularly proven aEDS patient is known to have had congenital unilateral hip dislocation [Byers et al., personal communication].

2. Severe GJH, with multiple dislocations/subluxations<sup>22</sup>
3. Skin hyperextensibility<sup>22</sup>

#### • Minor criteria

1. Muscle hypotonia
2. Kyphoscoliosis
3. Radiologically mild osteopenia
4. Tissue fragility, including atrophic scars
5. Easy bruisable skin

#### • Minimal criteria suggestive for aEDS:

- Major criterion (1): Congenital bilateral hip dislocation

Plus

- Either major criterion (3): skin hyperextensibility
- Or major criterion (2): severe GJH with multiple dislocations/subluxations and at least two other minor criteria

Confirmatory molecular testing is obligatory to reach a final diagnosis.

#### • Molecular basis

aEDS is caused by heterozygous mutations in either *COL1A1* or *COL1A2*, that cause entire or partial loss of exon 6 of the respective gene. No other genes are associated with aEDS.

#### • Verification of diagnosis

Molecular screening by Sanger sequencing of *COL1A1* and *COL1A2*, or targeted resequencing of a gene panel that includes these genes, is indicated. When no mutation is identified, this approach should be complemented with a CNV detection strategy to identify large deletions or duplications.

In case of unavailability of genetic testing, SDS PAGE of the pepsin-digested collagen in the medium or cell layer of cultured dermal fibroblasts demonstrates the presence of a mutant pN $\alpha$ 1(I) or pN $\alpha$ 2(I) chain (precursor procollagen chains in which the carboxy (C)-but not the amino (N)-propeptide is cleaved off).

TEM of skin specimens shows loosely and randomly organized collagen fibrils with a smaller and more variable diameter, and an irregular outline. These findings may support the diagnosis, but cannot confirm it.

Absence of a causative mutation in *COL1A1* or *COL1A2* that leads to

<sup>22</sup>For definition of GJH, see criteria for “Classical EDS.”

<sup>19</sup>“Dislocation” is defined as displacement of a bone out of the joint socket (or out of normal position in the case of sesamoid bones such as the patella), sufficiently severe to limit motion of the joint and requiring manual reduction.

<sup>20</sup>Refers to sites regardless of laterality. For example, right and left patellar instability would count as two. Instability should be evaluated and determined by a qualified practitioner using recommended guidelines.

complete or partial deletion of the exon 6 of either gene excludes the diagnosis of aEDS.

### Dermatosparaxis EDS (dEDS)

- Inheritance  
Autosomal recessive
- Major criteria:
  1. Extreme skin fragility with congenital or postnatal skin tears
  2. Characteristic craniofacial features, which are evident at birth or early infancy, or evolve later in childhood<sup>23</sup>
  3. Redundant, almost lax skin, with excessive skin folds at the wrists and ankles
  4. Increased palmar wrinkling
  5. Severe bruisability with a risk of subcutaneous hematomas and haemorrhage
  6. Umbilical hernia
  7. Postnatal growth retardation
  8. Short limbs, hand and feet
  9. Perinatal complications due to connective tissue fragility<sup>24</sup>
- Minor criteria
  1. Soft and doughy skin texture
  2. Skin hyperextensibility
  3. Atrophic scars
  4. GJH<sup>25</sup>
  5. Complications of visceral fragility (e.g., bladder rupture, diaphragmatic rupture, rectal prolapse)
  6. Delayed motor development<sup>26</sup>
  7. Osteopenia

<sup>23</sup>Craniofacial features include: prominent and protuberant eyes with puffy, oedematous eyelids and excessive periorbital skin, epicanthal folds, downslanting palpebral fissures, blue sclerae, large fontanels and/or wide cranial sutures, delayed closure of fontanels and hypoplastic chin.

<sup>24</sup>Reported perinatal complications due to connective tissue fragility include: congenital skull fractures, intracerebral hemorrhage, friable umbilical cord, congenital skin tears, neonatal pneumothorax.

<sup>25</sup>For definition of GJH, see criteria for “Classical EDS.”

<sup>26</sup>Most patients identified to date display a severe phenotype, recognizable from birth or first months of life. Milder forms of the condition have recently been described.

8. Hirsutism
  9. Tooth abnormalities
  10. Refractive errors (myopia, astigmatism)
  11. Strabismus
- Minimal criteria suggestive for dEDS:
    - Major criterion (1): extreme skin fragility
    - AND major criterion (2): characteristic craniofacial features
  - Plus
    - Either: one other major criterion
    - And/or: three minor criteria
  - Confirmatory molecular testing is obligatory to reach a final diagnosis.
  - Molecular basis  
dEDS is caused by biallelic mutations in *ADAMTS2*, the gene encoding ADAMTS-2, the main procollagen I N-proteinase. It is the only gene associated with dEDS.
  - Verification of diagnosis  
Molecular screening by Sanger sequencing of targeted resequencing of a gene panel that includes *ADAMTS2* is indicated. When no, or only one, causative mutation is identified, this approach should be complemented with a CNV detection strategy to identify large deletions or duplications.

In case of unavailability of genetic testing, SDS PAGE demonstrates presence of pN $\alpha$ 1(I) and pN $\alpha$ 2(I) chains of type I procollagen extracted from dermis in the presence of protease inhibitors or detected in fibroblast cultures.

TEM shows collagen fibrils in affected skin specimens with a hieroglyphic pattern. These ultrastructural findings are usually typical but may be almost indistinguishable from those observed in aEDS. As such, they are not sufficient to confirm the diagnosis.

Absence of these confirmatory findings does not exclude the diagnosis of dEDS, as specific types of mutations (e.g., deep intronic mutations) may go undetected by standard diagnostic molecular techniques; however, alternative diagnoses should be considered in the absence of *ADAMTS2* mutations.

### Kyphoscoliotic (kEDS)

- Inheritance  
Autosomal recessive

- Major criteria
  1. Congenital muscle hypotonia<sup>27</sup>
  2. Congenital or early onset kyphoscoliosis (progressive or non-progressive)<sup>28</sup>
  3. GJH<sup>29</sup> with dislocations/subluxations (shoulders, hips, and knees in particular)
- Minor criteria:
  1. Skin hyperextensibility<sup>29</sup>
  2. Easy bruisable skin
  3. Rupture/aneurysm of a medium-sized artery
  4. Osteopenia/osteoporosis
  5. Blue sclerae
  6. Hernia (umbilical or inguinal)
  7. Pectus deformity
  8. Marfanoid habitus
  9. Talipes equinovarus
  10. Refractive errors (myopia, hypermetropia)
- Gene-specific minor criteria
  1. *PLOD1*
    1. Skin fragility (easy bruising, friable skin, poor wound healing, widened atrophic scarring)
    2. Scleral and ocular fragility/rupture<sup>30</sup>
    3. Microcornea
    4. Facial dysmorphology<sup>31</sup>
  2. *FKBP14*
    1. Congenital hearing impairment (sensorineural, conductive, or mixed)
    2. Follicular hyperkeratosis
    3. Muscle atrophy
    4. Bladder diverticula

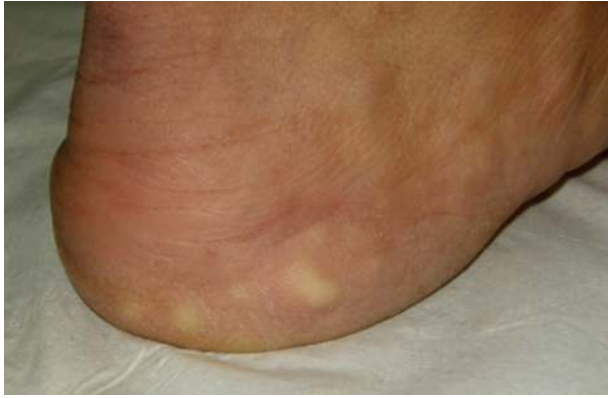<sup>27</sup>Muscular hypotonia can be very pronounced and lead to delayed gross motor development. This condition should be considered in the initial differential diagnosis of a floppy infant. Neuromuscular work-up is however normal.

<sup>28</sup>Kyphoscoliosis is usually present at birth or develops in infancy. In patients with biallelic *PLOD1* mutations, it may be absent throughout adulthood.

<sup>29</sup>For definitions of GJH and skin hyperextensibility, see criteria for “Classical EDS.”

<sup>30</sup>Scleral and ocular fragility were removed from the major clinical criteria of kEDS-*PLOD1*, as rupture of the eye globe following minimal trauma has only been reported in five individuals, including one patient with both eyes affected.

<sup>31</sup>Facial dysmorphic features include: low-set ears, epicanthal folds, down-slanting palpebral fissures, synophrys, and high palate.



**Figure 3.** Piezogenic papules of the feet which are subcutaneous fat herniations through the fascia. They often appear as blanching white nodules only while bearing weight.

- Minimal criteria suggestive for kEDS:
    - Major criterion (1): congenital muscle hypotonia
    - AND major criterion (2): congenital or early-onset kyphoscoliosis
- Plus
- Either major criterion (3): GJH
  - And/or three minor criteria (either general or gene-specific criteria)

Confirmatory molecular testing is obligatory to reach a final diagnosis.

- Molecular basis

The majority of patients with kEDS harbor biallelic mutations in *PLOD1*, the gene encoding the collagen-modifying enzyme procollagen-lysine, 2-oxoglutarate 5-dioxygenase 1 (*PLOD1* or *LH1* [lysylhydroxylase1]). *LH1* plays an important role as a post-translational modifying enzyme in collagen biosynthesis through (i) hydroxylation of helical lysyl residues in—Xaa-Lys-Gly—collagen sequences to hydroxy-lysyl residues which serve as sites of attachment for carbohydrate units (either galactose or glucosyl-galactose) and (ii) in the formation of intra- and intermolecular collagen cross-links. *LH1* deficiency results in underhydroxylation of lysyl residues and underglycosylation of hydroxylysyl residues in collagens and, hence, impaired cross-link formation with consequent mechanical instability of the affected tissues.

---

***The majority of patients with kEDS harbor biallelic mutations in *PLOD1*, the gene encoding the collagen-modifying enzyme procollagen-lysine, 2-oxoglutarate 5-dioxygenase 1 (*PLOD1* or *LH1* [lysylhydroxylase1]).***

---

Recently, biallelic mutations have been identified in *FKBP14*, encoding *FKBP22*, a member of the F506-binding family of peptidyl-prolyl cis-trans isomerases, in patients displaying a phenotype that clinically largely overlaps with kEDS-*PLOD1* [Baumann et al., 2012].

- Verification of diagnosis

Laboratory confirmation of kEDS should start with the quantification of deoxypyridinoline (Dpyr or LP for lysyl-pyridinoline) and pyridinoline (Pyr or HP for hydroxylysyl-pyridinoline) cross-links in urine quantitated by means of high-performance liquid chromatography (HPLC). An increased Dpyr/Pyr ratio is a highly sensitive and specific test for kEDS caused by biallelic *PLOD1* mutations (kEDS-*PLOD1*),

but is normal for biallelic *FKBP14* mutations (kEDS-*FKBP14*).

The normal ratio of Dpyr/Pyr cross-links is approximately 0.2, whereas in kEDS-*PLOD1* the ratio is significantly increased (approximately 10–40 times increase, range 2–9). This method is fast and cost-effective and it can also be used to determine the pathogenic status of a VUS in *PLOD1*.

SDS-PAGE may detect faster migration of underhydroxylated collagen chains and their derivatives in kEDS-*PLOD1* but not in kEDS-*FKBP14*. However, abnormalities in migration can be subtle.

Molecular analysis for kEDS-*PLOD1* may start with MLPA analysis of *PLOD1*, for the evaluation of the common intragenic duplication in *PLOD1* caused by an Alu-Alu recombination between introns 9 and 16 (the most common mutant allele) [Hautala et al., 1993].

Molecular screening by means of targeted resequencing of a gene panel that includes *PLOD1* and *FKBP14*, is indicated when MLPA of *PLOD1* fails to identify the common duplication. Such a gene panel may also include other genes associated with phenotypes that clinically overlap with kEDS, such as *ZNF469*, *PRDM5*, *B4GALT7*, *B3GALT6*, *SLC39A13*, *CHST14*, and *DSE*. Alternatively, WES may be performed. When no, or only one, causative mutation is identified, this approach should be complemented with a CNV detection strategy to identify large deletions or duplications in these genes.

TEM on skin specimens has shown variable diameters and abnormal contours of the collagen fibrils and irregular interfibrillar space, but these abnormalities are not unique to this condition. As such, whereas TEM on a skin biopsy can support diagnosis, it cannot confirm it.

Whereas absence of an abnormal urinary LP/HP ratio excludes the diagnosis of kEDS-*PLOD1*, absence of the confirmatory genetic findings does not exclude the diagnosis of kEDS, as specific types of mutations (e.g., deep intronic mutations) may go undetected

by standard diagnostic molecular techniques and/or other, yet to be discovered, genes, may be associated with this phenotype; however, alternative diagnoses should be considered in the absence of *PLOD1* or *FKBP14* mutations.

### Brittle Cornea Syndrome (BCS)

- Inheritance
  - Autosomal recessive
- Major criteria
  1. Thin cornea, with or without rupture (central corneal thickness often <400  $\mu\text{m}$ )
  2. Early onset progressive keratoconus
  3. Early onset progressive keratoglobus
  4. Blue sclerae
- Minor criteria
  1. Enucleation or corneal scarring as a result of previous rupture
  2. Progressive loss of corneal stromal depth, especially in central cornea
  3. High myopia, with normal or moderately increased axial length
  4. Retinal detachment
  5. Deafness, often with mixed conductive and sensorineural components, progressive, higher frequencies often more severely affected (“sloping” pure tone audiogram),
  6. Hypercompliant tympanic membranes
  7. Developmental dysplasia of the hip
  8. Hypotonia in infancy, usually mild if present
  9. Scoliosis
  10. Arachnodactyly
  11. Hypermobility of distal joints
  12. Pes planus, hallux valgus
  13. Mild contractures of fingers (especially 5th)
  14. Soft, velvety skin, translucent skin
- Minimal criteria suggestive for kEDS:
  - Major criterion (1): thin cornea, with or without rupture (central corneal thickness often <100 micrometer)
- Plus
  - Either: at least one other major criterion
  - And/or three other minor criteria

Confirmatory molecular testing is obligatory to reach a final diagnosis

- Molecular basis
 

BCS is caused by biallelic mutations in either *ZNF469*, encoding ZNF469, a zinc finger protein of unknown function, or *PRDM5*, encoding a DNA-binding transcription factor of the PR/SET protein family that lacks the intrinsic histone methyltransferase activity. At least one family with a clinical BCS phenotype did not harbor mutations in these genes, suggesting that at least one other gene might be associated with BCS [Rohrbach et al., 2013].
- Verification of diagnosis
 

Molecular screening by means of targeted resequencing of a gene panel that includes *ZNF469* and *PRDM5* is indicated. Such a gene panel may also include other genes associated with phenotypes that clinically overlap with BCS, such as *PLOD1*, *FKBP14*, *B4GALT7*, *B3GALT6*, *SLC39A13*, *CHST14* and *DSE*. Alternatively, WES may be performed. When no, or only one, causative mutation is identified, this approach should be complemented with a CNV detection strategy to identify large deletions or duplications in these genes.

Absence of these confirmatory findings does not exclude the diagnosis, as specific types of mutations (e.g., deep intronic mutations) may go undetected by standard diagnostic molecular techniques, and other, yet unknown genes, might be associated with BCS.

### Spondylodysplastic EDS (spEDS)

- Inheritance
  - Autosomal recessive
- Major criteria
  1. Short stature (progressive in childhood)
  2. Muscle hypotonia (ranging from severe congenital, to mild later-onset)
  3. Bowing of limbs
- Minor criteria
  1. Skin hyperextensibility,<sup>32</sup> soft, doughy skin, thin translucent skin
  2. Pes planus

<sup>32</sup>For definitions of GJH and skin hyperextensibility, see criteria for “Classical EDS.”

3. Delayed motor development
  4. Osteopenia
  5. Delayed cognitive development
- Gene-specific minor criteria
    - *B4GALT7*
      - Radioulnar synostosis
      - Bilateral elbow contractures or limited elbow movement
      - GJH<sup>32</sup>
      - Single transverse palmar crease
      - Characteristic craniofacial features<sup>33</sup>
      - Characteristic radiographic findings<sup>34</sup>
      - Severe hypermetropia
      - Clouded cornea
    - *B3GALT6*
      - Kyphoscoliosis (congenital or early onset, progressive)
      - Joint hypermobility, generalized or restricted to distal joints, with joint dislocations
      - Joint contractures (congenital or progressive) (especially hands)
      - Peculiar fingers (slender, tapered, arachnodactyly, spatulate, with broad distal phalanges)
      - Talipes equinovarus
      - Characteristic craniofacial features<sup>35</sup>
      - Tooth discoloration, dysplastic teeth

<sup>33</sup>Characteristic craniofacial features associated with biallelic *B4GALT7* mutations include: triangular face, wide-spaced eyes, proptosis, narrow mouth, low-set ears, sparse scalp hair, abnormal dentition, flat face, wide forehead, blue sclerae, and cleft palate/bidif uvula.

<sup>34</sup>Reported radiographic findings associated with biallelic *B4GALT7* mutations include: include radioulnar synostosis, metaphyseal flaring, osteopenia, radial head subluxation or dislocation, and short clavicles with broad medial ends.

<sup>35</sup>Characteristic craniofacial features associated with biallelic *B3GALT6* mutations include: midfacial hypoplasia, frontal bossing, proptosis, or prominent eyes, blue sclerae, downslanting palpebral fissures, depressed nasal bridge, long upperlip, low-set ears, micrognathia, abnormal dentition, cleft palate, sparse hair.

- Characteristic radiographic findings<sup>36</sup>
- Osteoporosis with multiple spontaneous fractures
- Ascending aortic aneurysm
- Lung hypoplasia, restrictive lung disease
- *SLC39A13*:
  - Protuberant eyes with bluish sclerae
  - Hands with finely wrinkled palms
  - Atrophy of the thenar muscles, and tapering fingers
  - Hypermobility of distal joints
  - Characteristic radiologic findings<sup>37</sup>
- Minimal criteria suggestive for spEDS:
  - Major criterion (1): short stature
  - AND major criterion (2): muscle hypotonia
- Plus
  - Characteristic radiographic abnormalities and at least three other minor criteria (general or type-specific)
- Confirmatory molecular testing is obligatory to reach a final diagnosis
- Molecular basis
  - spEDS is caused by either:
    - Biallelic mutations in *B4GALT7*, encoding galactosyltransferase I ( $\beta$ 1,4-galactosyltransferase 7 or  $\beta$ 4GalT7), which catalyzes the transfer of the first galactose to the xylose residue in tetrasaccharide linker region of glycosaminoglycans (GAGs).
    - Biallelic mutations in *B3GALT6*, encoding galactosyltransferase II ( $\beta$ 1,3-galactosyltransferase 6 or  $\beta$ 3GalT6), which catalyzes the

transfer of the second galactose to the first galactose residue in tetrasaccharide linker region of GAGs.

- Biallelic mutations in *SLC39A13*, encoding the homodimeric transmembrane Zrt/irt-like protein 13 (ZIP13) protein, a member of the SLC39A/ZIP family that regulates the influx of Zn into the cytosol.

- Verification of diagnosis
  - Molecular screening by means of targeted resequencing of a gene panel that includes *B4GALT7*, *B3GALT6*, and *SLC39A13* is indicated. Such a gene panel may also include other genes associated with phenotypes that clinically overlap with spEDS, such as *PLOD1*, *FKBP14*, *ZNF469*, *PRDM5*, *CHST14*, and *DSE*. Alternatively, WES may be performed. When no, or only one, causative mutation is identified, this approach should be complemented with a CNV detection strategy to identify large deletions or duplications in these genes.

For definite proof of GAG deficiency (*B4GALT7* and *B3GALT6* mutations), biochemical methods to assess GAG synthesis in patients' cultured fibroblasts are currently available in many specialized laboratories [Talhoui et al., 2010].

The laboratory measurement of urinary pyridinolines, lysyl-pyridinoline (LP) and hydroxylysyl-pyridinoline (HP) quantitated by HPLC allows the detection of an increased ratio LP/HP to approximately 1, (compared to a normal values of approximately 0.2) in patients with mutations in *SLC39A13* [Giunta et al., 2008]. This fast and cost-effective method can also be used to determine the pathogenic status of a VUS (see also "verification of diagnosis" in kEDS-*PLOD1*).

Absence of confirmatory genetic findings does not exclude the diagnosis of spEDS, as specific types of mutations (eg deep intronic mutations) may go undetected by standard diagnostic molecular techniques, and still other, yet to be discovered, genes may be associated with these phenotypes. In case no *B4GALT7*, *B3GALT6*, or *SCL39A13* mutations are identified, alternative diagnoses should however be considered.

## Musculocontractural EDS (mcEDS)

- Inheritance
  - Autosomal recessive
- Major criteria
  1. Congenital multiple contractures, characteristically adduction-flexion contractures and/or talipes equinovarus (clubfoot)
  2. Characteristic craniofacial features, which are evident at birth or in early infancy<sup>38</sup>
  3. Characteristic cutaneous features including skin hyperextensibility<sup>39</sup>, easy bruisability, skin fragility with atrophic scars, increased palmar wrinkling
- Minor criteria
  1. Recurrent/chronic dislocations<sup>40</sup>
  2. Pectus deformities (flat, excavated)
  3. Spinal deformities (scoliosis, kyphoscoliosis)
  4. Peculiar fingers (tapering, slender, cylindrical)
  5. Progressive talipes deformities (valgus, planus, cavum)
  6. Large subcutaneous hematomas
  7. Chronic constipation
  8. Colonic diverticula
  9. Pneumothorax/pneumohemothorax
  10. Nephrolithiasis/cystolithiasis
  11. Hydronephrosis
  12. Cryptorchidism in males
  13. Strabismus
  14. Refractive errors (myopia, astigmatism)
  15. Glaucoma/elevated intraocular pressure

<sup>38</sup>Characteristic craniofacial features include: large fontanelle, hypertelorism, short and downslanting palpebral fissures, blue sclerae, short nose with hypoplastic columella, low-set and rotated ears, high palate, long philtrum, thin upper lip vermilion, small mouth, microretrognathia.

<sup>39</sup>For definition of skin hyperextensibility, see criteria for "Classical EDS."

<sup>40</sup>The phenotypic features in the three reported patients with EDS caused by DSE deficiency seem to be milder than those in patients with EDS caused by D4ST1-deficiency, but identification of additional patients with DSE-deficiency is needed to confirm this correlation.

<sup>36</sup>Reported radiographic features associated with biallelic *B3GALT6* mutations include: platyspondyly, anterior beak of vertebral body, short ilium, prominent lesser trochanter, acetabular dysplasia, metaphyseal flaring, metaphyseal dysplasia of femoral head, elbow malalignment, radial head dislocation, over-tubulation, bowing of long bones, generalized osteoporosis, healed fractures. Craniosynostosis and radioulnar dysostosis has been reported in one patient.

<sup>37</sup>Reported radiologic findings associated with biallelic *SLC39A13* mutations include: mild to moderate platyspondyly, mild to moderate osteopenia of the spine, small ileum, flat proximal femoral epiphyses, short, wide femoral necks.



- Minimal criteria suggestive for mcEDS:
  - At birth or in early childhood: Major criterion (1): Congenital multiple contractures AND (2) characteristic craniofacial features
  - In adolescence and in adulthood: Major criterion (1): Congenital multiple contractures AND (3) characteristic cutaneous features
 Confirmatory molecular testing is obligatory to reach a final diagnosis.
- Molecular basis  
mcEDS is caused by biallelic mutations in *CHST14*, encoding D4ST1, a single-exon gene encoding carbohydrate sulfotransferase 14 or dermatan 4-O-sulfotransferase 1, an enzyme involved in the biosynthesis of the GAG dermatan sulfate. It catalyzes 4-O-sulfation of *N*-acetylgalactosamine (GalNAc) in the sequence “L-iduronic acid (IdoA)-GalNAc,” immediately after epimerization of D-glucuronic acid (GlcA) to IdoA by dermatan sulfate epimerase (DSE).

---

***mcEDS is caused by biallelic mutations in *CHST14*, encoding D4ST1, a single-exon gene encoding carbohydrate sulfotransferase 14 or dermatan 4-O-sulfotransferase 1, an enzyme involved in the biosynthesis of the GAG dermatan sulfate.***

---

A few mutations have been identified in the *DSE* gene, encoding DSE, in patients with a similar phenotype.

- Verification of diagnosis  
Molecular screening by means of targeted resequencing of a gene panel that includes *CHST14* and *DSE* is indicated. Such a gene panel may also include other genes associated with phenotypes that clinically overlap with mcEDS, such as *PLOD1*, *FKBP14*, *ZNF469*, *PRDM5*, *B4GALT7*, *B3GALT6*, and *SLC39A13*. Alternatively, WES may be

performed. When no, or only one, causative mutation is identified, this approach should be complemented with a CNV detection strategy to identify large deletions or duplications in these genes.

Absence of these confirmatory findings does not exclude the diagnosis of mcEDS, as specific types of mutations (e.g., deep intronic mutations) may go undetected by standard diagnostic molecular techniques. In case no *CHST14* or *DSE* mutations are identified, alternative diagnoses should be considered.

### **Myopathic EDS (mEDS)**

- Inheritance  
Autosomal dominant or autosomal recessive
- Major criteria
  1. Congenital muscle hypotonia, and/or muscle atrophy, that improves with age<sup>41</sup>
  2. Proximal joint contractures (knee, hip, and elbow)<sup>42</sup>
  3. Hypermobility of distal joints
- Minor criteria
  1. Soft, doughy skin
  2. Atrophic scarring

---

<sup>41</sup>So far, five families have been reported: four with an autosomal dominant condition and one with an autosomal recessive condition. The affected siblings from the family with the autosomal recessive condition have a more severe form of the condition than patients with autosomal dominant inheritance [Zou et al., 2014].

<sup>42</sup>Muscle biopsy and skin fibroblast culture studies: the diagnosis can be suspected in patients that undergo a muscle biopsy and/or in whom a fibroblast line is established. In the autosomal recessive form in which there is no collagen XII produced, immunostaining has shown absence of collagen XII staining. In missense mutations that lead to autosomal dominant forms, collagen XII may be abnormally secreted. The myopathic pattern on muscle biopsy may be suggestive, but is not diagnostic. Recently, muscle MRI has been developed as an alternative, non-invasive technique to study muscle involvement, however it is not specific enough to confirm the diagnosis.

3. Motor developmental delay
  4. Myopathy on muscle biopsy
- Minimal clinical criteria suggestive for mEDS:
    - Major criterion (1): congenital muscle hypotonia that improves with age Plus
    - Either: one other major criterion
    - And/or: three minor criteria
 Confirmatory molecular testing is obligatory to reach a final diagnosis.
  - Molecular basis  
mEDS is caused by heterozygous or biallelic mutations in *COL12A1*, encoding type XII collagen. The clinical phenotype highly overlaps with collagen type VI-related myopathies, that is, Bethlem Myopathy, and Ullrich Congenital Muscular Dystrophy. It is currently unknown whether other, yet to be discovered genes, are associated with this phenotype.

- Verification of diagnosis  
Molecular screening by means of targeted resequencing of a gene panel that includes *COL12A1* is indicated. Such a gene panel may also include other genes associated with phenotypes that clinically overlap with mEDS, such as *COL6A1*, *COL6A2*, *COL6A3*. Alternatively, WES may be performed. When no, or only one, causative mutation is identified, this approach should be complemented with a CNV detection strategy to identify large deletions or duplications in these genes.

Absence of these confirmatory findings does not exclude the diagnosis, as specific types of mutations (eg deep intronic mutations) may go undetected by standard diagnostic molecular techniques, and other, yet to be discovered, genes may be associated with this phenotype. In case no *COL12A1* mutations are identified alternative diagnoses, especially collagen VI-related Ullrich Congenital Muscular Dystrophy and Bethlem Myopathy, should be considered.

### **Periodontal EDS (pEDS)**

- Inheritance  
Autosomal dominant

- Major criteria
  - Severe and intractable periodontitis of early onset (childhood or adolescence)
  - Lack of attached gingiva
  - Pretibial plaques
  - Family history of a first-degree relative who meets clinical criteria
- Minor criteria
  - Easy bruising
  - Joint hypermobility, mostly distal joints
  - Skin hyperextensibility<sup>43</sup> and fragility, abnormal scarring (wide or atrophic)
  - Increased rate of infections
  - Hernias
  - Marfanoid facial features
  - Acrogeria
  - Prominent vasculature
- Minimal criteria suggestive for pEDS:
  - Major criterion (1): severe and intractable periodontitis of early onset (childhood or adolescence)
  - OR major criterion (2): lack of attached gingiva

Plus

- At least two other major criteria and one minor criterion

Confirmatory molecular testing is obligatory to reach a final diagnosis.

- Molecular basis
 

pEDS is caused by heterozygous gain-of-function mutations in *C1R* or *C1S*, encoding subunits C1r and C1s of the first component of the classical complement pathway.
- Verification of diagnosis
 

Identification of known or compatible mutations by sequence analysis of *C1R* and *C1S*. Large deletions or null mutations that completely remove C1r or C1s protein function do not cause pEDS.

At present it cannot be stated whether absence of a *C1R* or *C1S* mutations excludes the diagnosis because the experience with the molecular diagnosis is limited.

## CONCLUDING REMARKS

We hope that the revised International EDS criteria will serve as a new, albeit provisional, standard for the diagnosis of EDS. Our proposal has the aim of

facilitating accurate and timely diagnosis, and improve the diagnostic uniformity for clinical and research purposes, genetic counseling, management, natural history studies, and identification of potential areas of research. Future revision of this EDS Classification will be planned within the framework of the International EDS Consortium and the Ehlers–Danlos Society.

## ACKNOWLEDGMENTS

We are very grateful for the cooperation of many patients and their families all over the world. We thank Professor Stephen Robertson and PVNH support for their help with PVNH-EDS. We also wish to acknowledge the contributions of many professionals and lay persons alike to this endeavour. We would like to thank our generous sponsors including, but not limited to, The Ehlers–Danlos National Foundation, the Ehlers–Danlos Support UK, and the Ehlers–Danlos Society. Fransiska Malfait is Senior Clinical Investigator at the Fund for Scientific Research Flanders.

## REFERENCES

- Atzinger CL, Meyer RA, Khoury PR, Gao Z, Tinkle BT. 2011. Cross-sectional and longitudinal assessment of aortic root dilation and valvular anomalies in hypermobile and classic Ehlers–Danlos syndrome. *J Pediatr* 158:826–830.e821.
- Baumann M, Giunta C, Krabichler B, Ruschendorf F, Zoppi N, Colombi M, Bittner RE, Quijano-Roy S, Muntoni F, Cirak S, Schreiber G, Zou Y, Hu Y, Romero NB, Carlier RY, Amberger A, Deuschmann A, Straub V, Rohrbach M, Steinmann B, Rostasy K, Karall D, Bonnemann CG, Zschocke J, Fauth C. 2012. Mutations in FKBP14 cause a variant of Ehlers–Danlos syndrome with progressive kyphoscoliosis, myopathy, and hearing loss. *Am J Hum Genet* 90:201–216.
- Beighton P, de Paepe A, Danks D, Finidori G, Gedde-Dahl T, Goodman R, Hall JG, Hollister DW, Horton W, McKusick VA, et al. 1988. International nosology of heritable disorders of connective tissue, Berlin, 1986. *Am J Med Genet* 29:581–594.
- Beighton P, de Paepe A, Steinmann B, Tsipouras P, Wenstrup RJ. 1998. Ehlers–Danlos syndromes: Revised nosology, villefranche, 1997. ehlers–Danlos national foundation (USA) and ehlers–Danlos support group (UK). *Am J Med Genet* 77:31–37.

- Camerota F, Castori M, Celletti C, Colotto M, Amato S, Colella A, Curione M, Danese C. 2014. Heart rate, conduction and ultrasound abnormalities in adults with joint hypermobility syndrome/Ehlers–Danlos syndrome, hypermobility type. *Clin Rheumatol* 33:981–987.
- Dolan AL, Mishra MB, Chambers JB, Grahame R. 1997. Clinical and echocardiographic survey of the Ehlers–Danlos syndrome. *Br J Rheumatol* 36:459–462.
- Giunta C, Elçioglu NH, Albrecht B, Eich G, Chambaz C, Janecke AR, Yeowell H, Weis M, Eyre DR, Kraenzlin M, Steinmann B. 2008. Spondylocheiro dysplastic form of the Ehlers–Danlos syndrome—An autosomal-recessive entity caused by mutations in the zinc transporter gene SLC39A13. *Am J Hum Genet* 82:1290–1305.
- Hakim AJ, Grahame R. 2003. A simple questionnaire to detect hypermobility: An adjunct to the assessment of patients with diffuse musculoskeletal pain. *Int J Clin Pract* 57:163–166.
- Hautala T, Heikkinen J, Kivirikko KI, Myllylä R. 1993. A large duplication in the gene for lysyl hydroxylase accounts for the type VI variant of Ehlers–Danlos syndrome in two siblings. *Genomics* 15:399–404.
- Kahana M, Feinstein A, Tabachnic E, Schewach-Millet M, Engelberg S. 1987. Painful piezogenic pedal papules in patients with Ehlers–Danlos syndrome. *J Am Acad Dermatol* 17:205–209.
- Kozanoglu E, Coskun Benlidayi I, Akilli R, Tasal A. 2016. Is there any link between joint hypermobility and mitral valve prolapse in patients with fibromyalgia syndrome? *Clin Rheumatol* 35:1041–1044.
- Malfait F, Symoens S, Coucke P, Nunes L, De Almeida S, De Paepe A. 2006. Total absence of the alpha2(I) chain of collagen type I causes a rare form of Ehlers–Danlos syndrome with hypermobility and propensity to cardiac valvular problems. *J Med Genet* 43:e36.
- Malfait F, Symoens S, De Backer J, Hermans-Le T, Sakalihan N, Lapiere CM, Coucke P, De Paepe A. 2007a. Three arginine to cysteine substitutions 4 in the pro-alpha (I)-collagen chain cause Ehlers–Danlos syndrome with a propensity to arterial rupture in early adulthood. *Human Mutation* 28:387–395.
- Malfait F, Symoens S, De Backer J, Hermans-Le T, Sakalihan N, Lapiere CM, Coucke P, De Paepe A. 2007b. Three arginine to cysteine substitutions in the pro-alpha (I)-collagen chain cause Ehlers–Danlos syndrome with a propensity to arterial rupture in early adulthood. *Hum Mutat* 28:387–395.
- McDonnell NB, Gorman BL, Mandel KW, Schurman SH, Assanah-Carroll A, Mayer SA, Najjar SS, Francomano CA. 2006. Echocardiographic findings in classical and hypermobile Ehlers–Danlos syndromes. *Am J Med Genet A* 140A:129–136.
- McKay MJ, Baldwin JN, Ferreira P, Simic M, Vanicek N, Hiller CE, Nightingale EJ, Moloney NA, Quinlan KG, Pourkazemi F, Sman AD, Nicholson LL, Mousavi SJ, Rose K, Raymond J, Mackey MG, Chard A, Hubscher M, Wegener C, Fong Yan A, Refshauge KM, Burns J, Norms Project C. 2016. 1000 Norms Project: Protocol of a

- cross-sectional study cataloging human variation. *Physiotherapy* 102:50–56.
- Mulvey MR, Macfarlane GJ, Beasley M, Symmons DP, Lovell K, Keeley P, Woby S, McBeth J. 2013. Modest association of joint hypermobility with disabling and limiting musculoskeletal pain: Results from a large-scale general population-based survey. *Arthritis Care Res (Hoboken)* 65:1325–1333.
- Poppe H, Hamm H. 2013. Piezogenic papules in Ehlers-Danlos syndrome. *J Pediatr* 163:1788.
- Pyeritz RE, Loeys B. 2012. The 8th international research symposium on the Marfan syndrome and related conditions. *Am J Med Genet A* 158A:42–49.
- Remvig L, Duhn PH, Ullman S, Kobayasi T, Hansen B, Juul-Kristensen B, Jurvelin JS, Arokoski J. 2009. Skin extensibility and consistency in patients with Ehlers-Danlos syndrome and benign joint hypermobility syndrome. *Scand J Rheumatol* 38:227–230.
- Remvig L, Jensen DV, Ward RC. 2007. Are diagnostic criteria for general joint hypermobility and benign joint hypermobility syndrome based on reproducible and valid tests? A review of the literature. *J Rheumatol* 34:798–803.
- Ritelli M, Dordoni C, Venturini M, Chiarelli N, Quinzani S, Traversa M, Zoppi N, Vascellaro A, Wischmeijer A, Manfredini E, Garavelli L, Calzavara-Pinton P, Colombi M. 2013. Clinical and molecular characterization of 40 patients with classic Ehlers-Danlos syndrome: Identification of 18 COL5A1 and 2 COL5A2 novel mutations. *Orphanet J Rare Dis* 8:58.
- Rohrbach MSH, Porter LF, Burkitt-Wright EM, Bürer C, Janecke A, Bakshi M, Sillence D, Al-Hussain H, Baumgartner M, Steinmann B, Black GC, Manson FD, Giunta C. 2013. ZNF469 frequently mutated in the brittle cornea syndrome (BCS) is a single exon gene possibly regulating the expression of several extracellular matrix components. *Mol Genet Metab* 109:289–295.
- Schalkwijk J, Zweers MC, Steijlen PM, Dean WB, Taylor G, van Vlijmen IM, van Haren B, Miller WL, Bristow J. 2001. A recessive form of the Ehlers-Danlos syndrome caused by tenascin-X deficiency. *N Engl J Med* 345:1167–1175.
- Schwarze U, Hata R, McKusick VA, Shinkai H, Hoyme HE, Pyeritz RE, Byers PH. 2004. Rare autosomal recessive cardiac valvular form of Ehlers-Danlos syndrome results from mutations in the COL1A2 gene that activate the nonsense-mediated RNA decay pathway. *Am J Hum Genet* 74:917–930.
- Smits-Engelsman B, Klerks M, Kirby A. 2011. Beighton score: A valid measure for generalized hypermobility in children. *J Pediatr* 158:119–123 e111–114.
- Soucie JM, Wang C, Forsyth A, Funk S, Denny M, Roach KE, Boone D, Hemophilia Treatment Center N. 2011. Range of motion measurements: Reference values and a database for comparison studies. *Haemophilia* 17:500–507.
- Symoens S, Syx D, Malfait F, Callewaert B, De Backer J, Vanakker O, Coucke P, De Paepe A. 2012. Comprehensive molecular analysis demonstrates type V collagen mutations in over 90% of patients with classic EDS and allows to refine diagnostic criteria. *Hum Mutat* 33:1485–1493.
- Talhaoui I, Bui C, Oriol R, Mulliert G, Gulberti S, Netter P, Coughtrie MW, Ouzzine M, Fournel-Gigleux S. 2010. Identification of key functional residues in the active site of human  $\beta$ 1, 4-galactosyltransferase 7: A major enzyme in the glycosaminoglycan synthesis pathway. *J Biol Chem* 285:37342–37358.
- Weerakkody RA, Vandrovцова J, Kanonidou C, Mueller M, Gampawar P, Ibrahim Y, Norsworthy P, Biggs J, Abdullah A, Ross D, Black HA, Ferguson D, Cheshire NJ, Kazkaz H, Grahame R, Ghali N, Vanders-teen A, Pope FM, Aitman TJ. 2016. Targeted next-generation sequencing makes new molecular diagnoses and expands genotype-phenotype relationship in Ehlers-Danlos syndrome. *Genet Med* 18:1119–1127.
- Zoppi N, Chiarelli N, Cinquina V, Ritelli M, Colombi M. 2015. GLUT10 deficiency leads to oxidative stress and non-canonical  $\alpha$ v $\beta$ 3 integrin-mediated TGF $\beta$  signalling associated with extracellular matrix disarray in arterial tortuosity syndrome skin fibroblasts. *Hum Mol Genet* 24:6769–6787.
- Zou Y, Zwolaneck D, Izu Y, Gandhi S, Schreiber G, Brockmann K, Devoto M, Tian Z, Hu Y, Veit G, Meier M, Stetefeld J, Hicks D, Straub V, Voermans NC, Birk DE, Barton ER, Koch M, Bonnemann CG. 2014. Recessive and dominant mutations in COL12A1 cause a novel EDS/myopathy overlap syndrome in humans and mice. *Hum Mol Genet* 23:2339–2352.