



## Floating-Harbor Syndrome

Malgorzata JM Nowaczyk, MD, FRCPC, FCCMG, FACMG,<sup>1</sup> Sarah M Nikkel, MD, FRCPC, FCCMG,<sup>2</sup> and Susan M White, MD, FRACP<sup>3</sup>

Created: November 29, 2012; Updated: May 23, 2019.

## Summary

### Clinical characteristics

Floating-Harbor syndrome (FHS) is characterized by typical craniofacial features; low birth weight, normal head circumference, and short stature; bone age delay that normalizes between ages six and 12 years; skeletal anomalies (brachydactyly, clubbing, clinodactyly, short thumbs, prominent joints, clavicular abnormalities); severe receptive and expressive language impairment; hypernasality and high-pitched voice; and intellectual disability that is typically mild to moderate. Difficulties with temperament and behavior that are present in many children tend to improve in adulthood. Other features can include hyperopia and/or strabismus, conductive hearing loss, seizures, gastroesophageal reflux, renal anomalies (e.g., hydronephrosis / renal pelviectasis, cysts, and/or agenesis), and genital anomalies (e.g., hypospadias and/or undescended testes).

### Diagnosis/testing

The diagnosis is established by identification of a heterozygous *SRCAP* pathogenic variant in those with clinical findings of FHS.

### Management

*Treatment of manifestations:* Early intervention programs, special education, and vocational training to address developmental disabilities; communication rehabilitation with sign language or alternative means of communication; and behavior management by a behavioral specialist/psychologist with consideration of medication as needed. Referral to an endocrinologist for consideration of human growth hormone (HGH) therapy; however, data on use of HGH in FHS are limited. Standard treatment for refractive errors and strabismus, hearing loss, seizures, gastroesophageal reflux, and renal and genitourinary anomalies.

**Author Affiliations:** 1 Department of Pathology and Molecular Medicine, McMaster University, Hamilton, Ontario, Canada; Email: [nowaczyk@hhsc.ca](mailto:nowaczyk@hhsc.ca). 2 Department of Genetics, BC Children's Hospital, Vancouver, British Columbia, Canada; Email: [sarah.nikkel@cw.bc.ca](mailto:sarah.nikkel@cw.bc.ca). 3 Victorian Clinical Genetics Service, Murdoch Children's Research Institute, Royal Children's Hospital, Victoria, Australia; Email: [sue.white@vcgs.org.au](mailto:sue.white@vcgs.org.au).

*Surveillance:* Close monitoring of growth, especially in the first year. Annual: ophthalmologic evaluation, hearing screening, blood pressure measurement, and assessment of renal function. Sonographic evaluation for renal cysts in teenage/adult years is indicated.

## Genetic counseling

FHS is inherited in an autosomal dominant manner. The majority of affected individuals have a *de novo* pathogenic variant. Each child of an individual with FHS has a 50% chance of inheriting the pathogenic variant. Prenatal diagnosis is possible for families in which the pathogenic variant has been identified.

## Diagnosis

### Suggestive Findings

Floating-Harbor syndrome (FHS) **should be suspected** in individuals with the following clinical and radiographic features.

#### Craniofacial appearance (see Figure 1)

- Triangular face
- Deep-set eyes
- Short philtrum
- Wide mouth with a thin vermilion border of the upper lip
- Long nose with a narrow bridge, broad base, broad tip, and low-hanging columella
- Low-set ears

#### Other features

- Significant delay in bone age ( $\geq -2$  SD) with normalization between ages six and 12 years
- Skeletal anomalies. Brachydactyly, broad fingertips that give the appearance of clubbing, clinodactyly, short thumbs, prominent joints, clavicular abnormalities (see Figure 2)
- Short adult stature. 140-155 cm (see Figure 3)

#### Speech and language

- Dysarthria and verbal dyspraxia with phoneme imprecision
- Hypernasality
- High-pitched voice
- Severe receptive and expressive language impairment across all domains of function

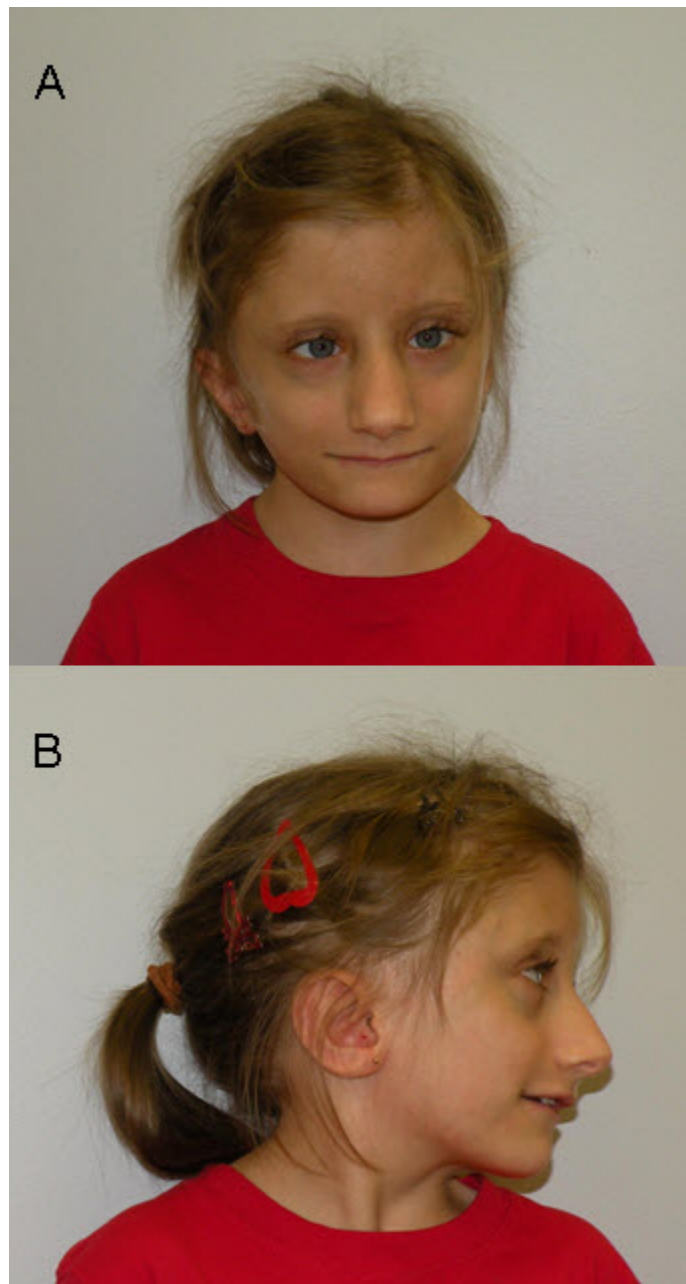
**Intellectual disability.** All individuals have some degree of intellectual impairment and/or learning disability ranging from borderline normal to moderate intellectual disability.

## Establishing the Diagnosis

The diagnosis of FHS **is established** in a proband with Suggestive Findings by identification of a heterozygous pathogenic variant in *SRCAP* on molecular genetic testing (see Table 1).

Molecular genetic testing approaches can include a combination of **gene-targeted testing** (single-gene testing, multigene panel) and **comprehensive genomic testing** (exome sequencing, genome sequencing) depending on the phenotype.

Gene-targeted testing requires that the clinician determine which gene(s) are likely involved, whereas genomic testing does not. Because the phenotype of FHS is broad, individuals with the distinctive findings described in



**Figure 1.** Facial appearance of a girl age 11 years with FHS (*SRCAP* pathogenic variant p.Arg2444Ter)

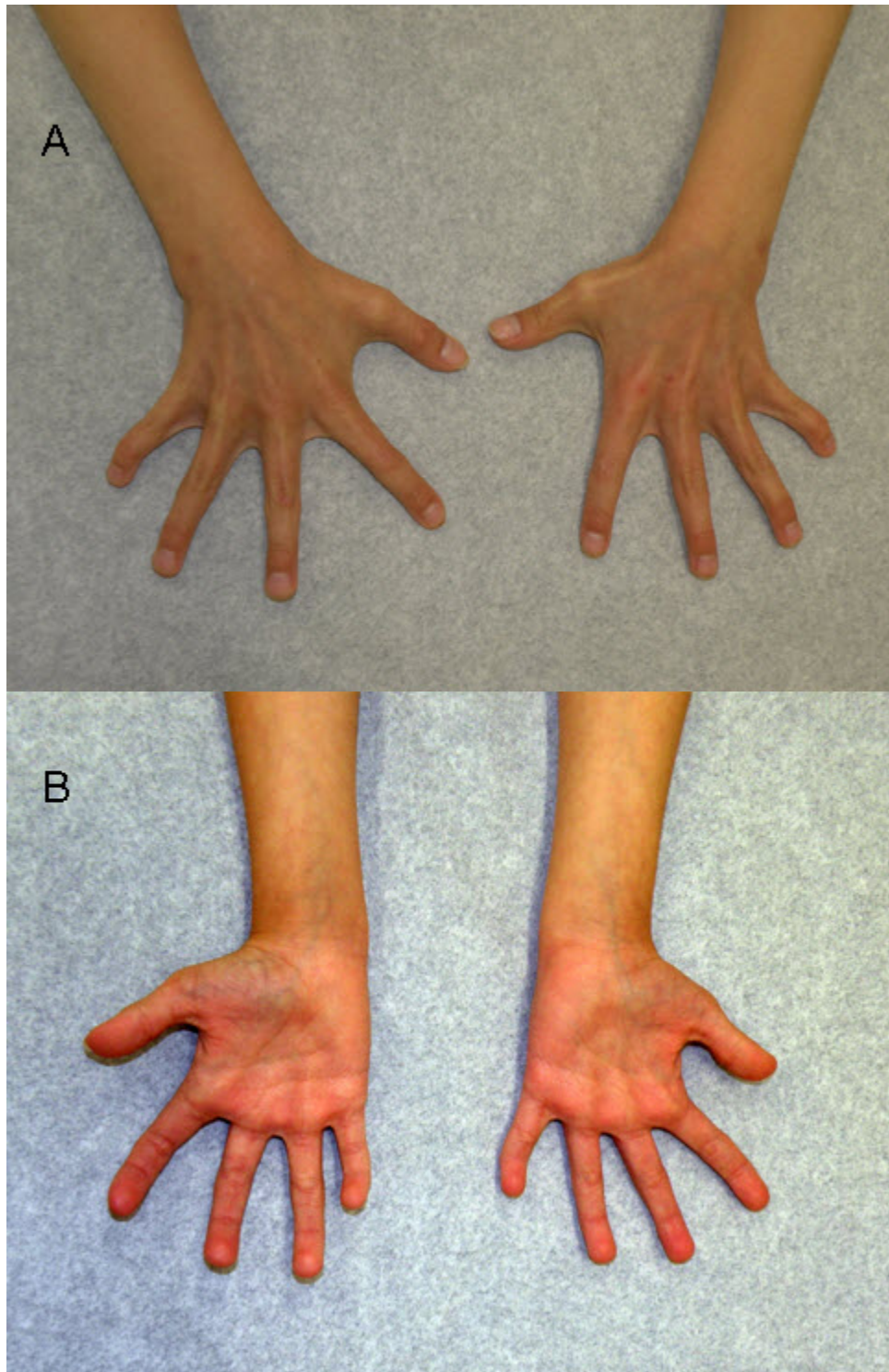
A. Note triangular face with deep-set eyes; short philtrum; long nose with narrow bridge and broad base with low-hanging columella; and thin upper lip.

B. Profile view shows low-set ears and low-hanging columella.

Suggestive Findings are likely to be diagnosed using gene-targeted testing (see Option 1), whereas those with a phenotype indistinguishable from many other inherited disorders with short stature and/or intellectual disability are more likely to be diagnosed using genomic testing (see Option 2).

### Option 1

When the phenotypic and laboratory findings suggest the diagnosis of FHS, molecular genetic testing approaches can include **single-gene testing** or use of a **multigene panel**.



**Figure 2.** Dorsal (A) and palmar (B) view of the hands of the girl in Figure 1. Note clinodactyly, widened fingertips, and prominent joints.

**Single-gene testing.** Sequence analysis of *SRCAP* detects small intragenic deletions/insertions and missense, nonsense, and splice site variants; typically, exon or whole-gene deletions/duplications are not detected. Perform sequence analysis first. If no pathogenic variant is found, perform gene-targeted deletion/duplication analysis to detect intragenic deletions or duplications.



**Figure 3.** Frontal view of the girl in Figure 1. She has proportionate short stature with height <3rd centile.

**A multigene panel** that includes *SRCAP* and other genes of interest (see Differential Diagnosis) is most likely to identify the genetic cause of the condition at the most reasonable cost while limiting identification of variants of uncertain significance and pathogenic variants in genes that do not explain the underlying phenotype. Note: (1) The genes included in the panel and the diagnostic sensitivity of the testing used for each gene vary by laboratory and are likely to change over time. (2) Some multigene panels may include genes not associated with the condition discussed in this *GeneReview*. (3) In some laboratories, panel options may include a custom laboratory-designed panel and/or custom phenotype-focused exome analysis that includes genes specified by the clinician. (4) Methods used in a panel may include sequence analysis, deletion/duplication analysis, and/or other non-sequencing-based tests.

For an introduction to multigene panels click [here](#). More detailed information for clinicians ordering genetic tests can be found [here](#).

## Option 2

When the phenotype is indistinguishable from many other inherited disorders characterized by short stature, **comprehensive genomic testing** (which does not require the clinician to determine which gene[s] are likely involved) is the best option. **Exome sequencing** is most commonly used; **genome sequencing** is also possible.

For an introduction to comprehensive genomic testing click [here](#). More detailed information for clinicians ordering genomic testing can be found [here](#).

**Table 1.** Molecular Genetic Testing Used in Floating-Harbor Syndrome

| Gene <sup>1</sup> | Method   | Proportion of Probands with a Pathogenic Variant <sup>2</sup> Detectable by Method |
|-------------------|--|--|
| SRCAP             | Sequence analysis <sup>3</sup>                           | 73/73 individuals <sup>4</sup>   |
|                   | Gene-targeted deletion/duplication analysis <sup>5</sup> | Unknown <sup>6</sup>   |

1. See Table A. Genes and Databases for chromosome locus and protein.

2. See Molecular Genetics for information on allelic variants detected in this gene.

3. Sequence analysis detects variants that are benign, likely benign, of uncertain significance, likely pathogenic, or pathogenic. Pathogenic variants may include small intragenic deletions/insertions and missense, nonsense, and splice site variants; typically, exon or whole-gene deletions/duplications are not detected. For issues to consider in interpretation of sequence analysis results, click [here](#).

4. Hood et al [2012], Le Goff et al [2013], Nikkel et al [2013], Dong et al [2014], Kehrer et al [2014], Nagasaki et al [2014], Seifert et al [2014], Amita et al [2016], Coughlin et al [2017], Singh et al [2017], Budisteanu et al [2018], Choi et al [2018], Milani et al [2018], Shields et al [2019]

5. Gene-targeted deletion/duplication analysis detects intragenic deletions or duplications. Methods used may include quantitative PCR, long-range PCR, multiplex ligation-dependent probe amplification (MLPA), and a gene-targeted microarray designed to detect single-exon deletions or duplications.

6. To date, large deletions that encompass SRCAP have not been associated with FHS phenotype [Author, personal communication] (see Genotype-Phenotype Correlations).

## Clinical Characteristics

### Clinical Description

Prior to the molecular characterization of Floating-Harbor syndrome (FHS) by Hood et al [2012], a number of reports included descriptions of individuals in whom the diagnosis of FHS could be questioned. This *GeneReview* only includes information on those 73 individuals with molecularly confirmed FHS (i.e., presence of a heterozygous SRCAP pathogenic variant) [Hood et al 2012, Le Goff et al 2013, Nikkel et al 2013, Dong et al 2014, Kehrer et al 2014, Nagasaki et al 2014, Seifert et al 2014, Amita et al 2016, Coughlin et al 2017, Singh et al 2017, Budisteanu et al 2018, Choi et al 2018, Milani et al 2018, Shields et al 2019]. The 41 females and 32 males range in age from eight months to 52 years.

FHS is frequently recognized in early childhood because of the characteristic facial features (Figure 1). Infants and younger children are often referred for assessment of poor growth or developmental (predominantly speech and language) delay.

**Craniofacial features** include triangular face, deep-set eyes, short philtrum, wide mouth with a thin vermilion border of the upper lip, long nose with a narrow bridge, broad base, broad tip, and low-hanging columella, and low-set ears.

The features become more pronounced with age, especially the length of the nose and the width of the nasal tip.

**Intellect.** Although gross motor and fine motor milestones are within normal limits, affected individuals typically have mild-to-moderate intellectual disability. A disorder of speech and language is the most severe disability. Most aspects of communication are affected; expressive language is most consistently and severely affected. Dysarthria and verbal dyspraxia with phoneme imprecision is most common, with absent speech in some individuals. Voice is described as hypernasal and high-pitched. The majority of affected children receive mainstream education with individualized educational plans. Regression of skills is not typical of FHS.

**Behavior.** Many individuals with FHS have temperament and behavior differences and difficulties: temper tantrums in infancy and attention-deficit/hyperactivity disorder spectrum with impulsivity, inattention, and restlessness at school age. Aggressive and violent outbursts can occur. Obsessive compulsive disorder and anxiety have been observed. Behavior problems are reported to improve in adulthood.

**Growth.** Short stature is a cardinal sign of FHS. The majority of individuals with FHS have low birth weight (from -3 SD to 0 SD) and normal head circumference (-2 SD to 0 SD). In the first years of life weight gain and linear growth are poor. A significant delay in bone age is reported ( $\geq -2$  SD) with normalization between ages six and 12 years. Average adult height is 140-155 cm.

**Puberty.** Early puberty has been reported; data are insufficient to determine the incidence in either gender.

**Eye.** Five of 73 individuals have been reported with hyperopia and eight of 13 with strabismus. One patient had anterior chamber abnormalities.

**Hearing.** Conductive hearing loss has been seen in eleven of 73 individuals with FHS. Cochlear abnormality has been observed in one of 73.

**Neurologic.** Seizures have been observed in seven of 73 individuals.

**Gastrointestinal.** Reflux can be severe, requiring G-tube feeding in some. Constipation and colonic strictures have been observed. One of 73 individuals had celiac disease; two had transient gluten intolerance.

**Genitourinary.** Renal and genitourinary anomalies can occur and include hypospadias and undescended testes, epididymal cysts, varicocele, and posterior urethral valves in boys. Hydronephrosis/renal pelviectasis and nephrocalcinosis, renal cysts, and renal agenesis have been observed. One adult of the 73 reported individuals developed polycystic kidney disease and end-stage renal disease.

**Orthopedic.** The body habitus is often stocky with a broad chest and short neck. Additional features include hand anomalies such as clinodactyly, brachydactyly, short thumbs, and broad fingertips that give the appearance of clubbing (Figure 2). Clavicular anomalies including pseudarthrosis and clavicular hypoplasia have been observed, as have short metacarpals, 11 pairs of ribs, kyphoscoliosis, prominent joints, dysplastic hips, and dislocated radial heads. Perthes disease has also been reported.

**Dental.** A number of individuals with FHS have dental problems (e.g., caries, microdontia, oligodontia, delayed loss of primary teeth) and orthodontic problems (e.g., maxillary retrusion, underbite).

**Cardiac.** Cardiac malformations are not usually a feature of FHS. Of 73 affected individuals one had mild aortic coarctation, one had mesocardia with persistent left superior vena cava, two had atrial septal defect, and one individual had tetralogy of Fallot.

## Genotype-Phenotype Correlations

Pathogenic variants in exons 33 and 34 of *SRCAP* that are predicted to cause truncation of the protein (removing 3 C-terminal AT-hook DNA-binding motifs while leaving the CBP-binding and ATPase domains intact) result in the FHS phenotype.

## Prevalence

The prevalence of FHS is not known. Seventy-three individuals with a heterozygous *SRCAP* pathogenic variant have been reported to date [Hood et al 2012, Le Goff et al 2013, Nikkel et al 2013, Dong et al 2014, Kehrer et al 2014, Nagasaki et al 2014, Seifert et al 2014, Amita et al 2016, Coughlin et al 2017, Singh et al 2017, Budisteanu et al 2018, Choi et al 2018, Milani et al 2018, Shields et al 2019].

The majority of individuals reported with FHS are of European origin, but FHS has also been diagnosed in individuals of Chinese, South American, South Asian, Japanese, and Korean background [Hood et al 2012, Nikkel et al 2013, Nagasaki et al 2014, Amita et al 2016, Singh et al 2017, Choi et al 2018]. Whether the occurrence of FHS is lower in nonwhite populations or the observed difference is the result of other factors is not known.

## Genetically Related (Allelic) Disorders

*SRCAP* truncating variants upstream of exon 33 and 34 have been identified in individuals with developmental and health issues, without clinical features of Floating-Harbor syndrome [Author, personal communication].

## Differential Diagnosis

The distinctive facial features, bone age delay, and characteristic speech disability that make the diagnosis of Floating-Harbor syndrome (FHS) straightforward in early childhood become less distinct with age. Table 2 lists genes and associated conditions that should be considered in children in whom the diagnosis of FHS is suspected.

**Table 2.** Other Genes of Interest in the Differential Diagnosis of Floating-Harbor Syndrome (FHS)

| Gene(s) <sup>1</sup>                        | Disorder                                   | MOI            | Clinical Features of Differential Diagnosis Disorder  |  |
|---|--|----------------|---|--|
|   |  |                | Overlapping w/FHS   | Distinguishing from FHS  |
| <i>CCDC8</i><br><i>CUL7</i><br><i>OBSL1</i> | Three M syndrome                           | AR             | <ul style="list-style-type: none"> <li>• Triangular face</li> <li>• Short 5th fingers</li> <li>• Bone age may be slightly delayed.</li> <li>• Males may have hypospadias.</li> <li>• Severe pre- &amp; postnatal growth restriction (final height 5-6 SD below mean; i.e., 120-130 cm)</li> </ul> | <ul style="list-style-type: none"> <li>• Relatively large head, hypoplastic midface, thick eyebrows, fleshy nasal tip, long philtrum, prominent mouth &amp; lips, pointed chin</li> <li>• Normal intelligence</li> <li>• Absence of language impairment</li> <li>• Characteristic radiologic findings</li> <li>• Short broad neck, prominent trapezii, deformed sternum, short thorax, square shoulders, winged scapulae, &amp; hyperlordosis, prominent heels, loose joints</li> <li>• Hypogonadism in males</li> </ul> |
| <i>CREBBP</i><br><i>EP300</i>               | Rubinstein-Taybi syndrome                  | AD             | <ul style="list-style-type: none"> <li>• Facial features (e.g., low-hanging columella)</li> <li>• Broad or angulated thumbs</li> <li>• 5th-finger clinodactyly</li> <li>• Short stature</li> </ul>  | <ul style="list-style-type: none"> <li>• Round face, downslanted palpebral fissures, small mouth opening</li> <li>• Severe intellectual disability</li> <li>• Normal bone age</li> <li>• Cardiac malformations</li> </ul>  |
| <i>FOXP2</i>                                | <i>FOXP2</i> speech and language disorders | See footnote 2 | <ul style="list-style-type: none"> <li>• Dysarthria</li> <li>• Hypernasality</li> <li>• Severe expressive &amp; receptive language &amp; literacy impairments</li> </ul>  | Absence of: <ul style="list-style-type: none"> <li>• Short stature</li> <li>• Delayed bone age</li> <li>• FHS characteristic facies</li> <li>• Aggression in childhood</li> </ul>  |



Table 2. continued from previous page.

| Gene(s) <sup>1</sup>             | Disorder                      | MOI            | Clinical Features of Differential Diagnosis Disorder  |  |
|----------------------------------|-------------------------------|----------------|---|--|
|                                  |                               |                | Overlapping w/FHS   | Distinguishing from FHS  |
| Multiple etiologies <sup>3</sup> | Silver-Russell syndrome (SRS) | See footnote 3 | <ul style="list-style-type: none"> <li>Pre- &amp; postnatal growth restriction</li> <li>Expressive language impairment (much more severe in FHS than in SRS)</li> </ul> | <ul style="list-style-type: none"> <li>Body asymmetry</li> <li>Café au lait macules</li> <li>Blue sclera</li> <li>Absence of FHS characteristic facial features &amp; thumb anomalies</li> </ul> |

AR = autosomal recessive; MOI = mode of inheritance; SRS = Silver-Russell syndrome; SD = standard deviation

1. Genes are listed in alphabetic order.

2. Recurrence risk for sibs of proband with a *FOXP2* speech and language disorder depends on the causative genetic alteration.

3. Silver-Russell syndrome (SRS) has multiple etiologies including: epigenetic changes that modify expression of genes in the imprinted region of chromosome 11p15.5, maternal UPD7, and (infrequently) autosomal dominant or autosomal recessive inheritance. When a proband has SRS as the result of paternal hypomethylation at IC1 or maternal UPD7, both parents are predicted to be unaffected, the risk to the sibs is not increased over that of the general population, and the risk to offspring is probably low.

## Management

### Evaluations Following Initial Diagnosis

To establish the extent of disease and needs in an individual diagnosed with Floating-Harbor syndrome (FHS), the evaluations summarized in Table 3 (if not performed as part of the evaluation that led to the diagnosis) are recommended.

Table 3. Recommended Evaluations Following Initial Diagnosis in Individuals with Floating-Harbor Syndrome

| System/Concern         | Evaluation  | Comment  |
|------------------------|---|--|
| <b>Constitutional</b>  | Measurement of growth & plotting of growth parameters   | Syndrome-specific charts are currently not available for children w/a <i>SRCAP</i> pathogenic variant.   |
| <b>Eyes</b>            | Ophthalmologic examination  |  |
| <b>ENT</b>             | Audiology evaluation  | (See <a href="#">Hereditary Hearing Loss and Deafness Overview</a> for details of evaluation.)   |
|                        | Dental evaluation   |  |
| <b>Genitourinary</b>   | <ul style="list-style-type: none"> <li>Renal ultrasound examination</li> <li>Blood pressure assessment</li> <li>Assessment for cryptorchidism in males</li> </ul> |  |
| <b>Musculoskeletal</b> | Orthopedic assessment   | Evaluation for hip dysplasia & clavicular anomalies  |
| <b>Other</b>           | Multidisciplinary developmental evaluation  | Incl assessment of gross & fine motor skills, speech/ language, cognitive abilities, & vocational skills w/special attention to speech delay & anomalies |
|                        | Consultation w/clinical geneticist &/or genetic counselor   |  |

### Treatment of Manifestations

Treatment includes the following:

- Early intervention programs, special education, and vocational training to address developmental disabilities

- Communication rehabilitation with sign language or alternative means of communication
- Behavior management strategies including referral to a behavioral specialist/psychologist and consideration of medication if needed
- Referral of the family to support groups and other resources
- Standard treatment for any of the following if identified:
  - Refractive errors and strabismus
  - Hearing loss
  - Seizures
  - Renal disease
  - Cryptorchidism
  - Orthopedic complications
  - Dental problems
- Referral to an endocrinologist for consideration of human growth hormone (HGH) therapy. HGH therapy with modest response has been reported in three children with FHS. Caution is indicated as limited information about HGH therapy in FHS is available.
- Investigation for celiac disease if indicated by clinical features

## Surveillance

**Table 4.** Recommended Surveillance for Individuals with Floating-Harbor Syndrome

| System/Concern        | Evaluation  | Frequency  |
|-----------------------|---|--|
| <b>Constitutional</b> | Evaluation of growth  | Close monitoring w/each visit, esp in 1st yr of life   |
|                       | <ul style="list-style-type: none"> <li>• Bone age examination</li> <li>• Evaluation for signs of early puberty</li> </ul> | Especially in individuals treated w/growth hormone   |
| <b>Eyes</b>           | Ophthalmologic evaluation   | Annual   |
| <b>ENT</b>            | Audiology evaluation  | Annual; more frequent evaluation if history of multiple episodes of otitis media                           |
| <b>Renal</b>          | Blood pressure measurement  | Annual   |
|                       | Assessment of renal function incl plasma BUN & creatinine   | Annual   |
|                       | Standard monitoring for renal anomalies   | Follow-up renal ultrasound if symptomatic  |
|                       | Sonographic evaluation for renal cysts  | In teenage/adult yrs as indicated by abnormalities on renal function tests &/or blood pressure measurement |

## Evaluation of Relatives at Risk

See Genetic Counseling for issues related to testing of at-risk relatives for genetic counseling purposes.

## Pregnancy Management

No specific pregnancy complications for the mother or the fetus have been observed in the two women with *SRCAP* pathogenic variants who had children with FHS.

## Therapies Under Investigation

Search [ClinicalTrials.gov](https://clinicaltrials.gov) in the US and [EU Clinical Trials Register](https://clinicaltrialsregister.eu) in Europe for information on clinical studies for a wide range of diseases and conditions. Note: There may not be clinical trials for this disorder.

## Genetic Counseling

*Genetic counseling is the process of providing individuals and families with information on the nature, inheritance, and implications of genetic disorders to help them make informed medical and personal decisions. The following section deals with genetic risk assessment and the use of family history and genetic testing to clarify genetic status for family members. This section is not meant to address all personal, cultural, or ethical issues that individuals may face or to substitute for consultation with a genetics professional. —ED.*

### Mode of Inheritance

Floating-Harbor syndrome (FHS) is inherited in an autosomal dominant manner.

### Risk to Family Members

#### Parents of a proband

- Most individuals with FHS have the disorder as the result of a *de novo* SRCAP pathogenic variant and therefore represent simplex cases (i.e., a single occurrence in the family).
- Transmission of an SRCAP pathogenic variant from an affected mother to her child has been reported in two families to date [Nikkel et al 2013].
- Molecular genetic testing and clinical evaluation for signs of FHS are recommended for the parents of a proband with an apparent *de novo* pathogenic variant.
- If the pathogenic variant found in the proband cannot be detected in the leukocyte DNA of either parent, the proband most likely has a *de novo* pathogenic variant; another possible explanation is germline mosaicism in a parent. Though theoretically possible, no instances of germline mosaicism have been reported.
- The family history of some individuals diagnosed with FHS may appear to be negative because of failure to recognize the disorder in a family member with a milder phenotype. Therefore, an apparently negative family history cannot be confirmed unless appropriate clinical evaluation and/or molecular genetic testing has been performed on the parents of the proband.
- An advanced paternal age effect is suggested. In their series of 13 individuals with a heterozygous SRCAP pathogenic variant, Hood et al [2012] reported a mean paternal age of 36.9 years (range 29-44 years).

**Sibs of a proband.** The risk to the sibs of the proband depends on the clinical/genetic status of the proband's parents:

- In the rare case of a parent being affected and/or known to have the pathogenic variant identified in the proband, the risk to sibs is 50%.
- If the proband has a known SRCAP pathogenic variant that cannot be detected in the leukocyte DNA of either parent, the recurrence risk to sibs is estimated to be 1% because of the theoretic possibility of parental germline mosaicism [Rahbari et al 2016].

**Offspring of a proband.** Each child of an individual with FHS has a 50% chance of inheriting the SRCAP pathogenic variant.

**Other family members.** The risk to other family members depends on the status of the proband's parents: if a parent has the FHS-causing pathogenic variant, his or her family members may be at risk.

### Related Genetic Counseling Issues

**Considerations in families with an apparent *de novo* pathogenic variant.** When neither parent of a proband with an autosomal dominant condition has the pathogenic variant identified in the proband or clinical evidence

of the disorder, the pathogenic variant is likely *de novo*. However, non-medical explanations including alternate paternity or maternity (e.g., with assisted reproduction) and undisclosed adoption could also be explored.

### Family planning

- The optimal time for determination of genetic risk and discussion of the availability of prenatal testing is before pregnancy.
- It is appropriate to offer genetic counseling (including discussion of potential risks to offspring and reproductive options) to the parents of an affected child and to young adults who are affected.

**DNA banking** is the storage of DNA (typically extracted from white blood cells) for possible future use. Because it is likely that testing methodology and our understanding of genes, allelic variants, and diseases will improve in the future, consideration should be given to banking DNA of affected individuals.

## Prenatal Testing and Preimplantation Genetic Diagnosis

Once the *SRCAP* pathogenic variant has been identified in an affected family member, prenatal testing for a pregnancy at increased risk for FHS and preimplantation genetic diagnosis are possible.

Differences in perspective may exist among medical professionals and within families regarding the use of prenatal testing, particularly if the testing is being considered for the purpose of pregnancy termination rather than early diagnosis. While most centers would consider decisions regarding prenatal testing to be the choice of the parents, discussion of these issues is appropriate.

## Resources

*GeneReviews staff has selected the following disease-specific and/or umbrella support organizations and/or registries for the benefit of individuals with this disorder and their families. GeneReviews is not responsible for the information provided by other organizations. For information on selection criteria, click [here](#).*

- **Human Growth Foundation (HGF)**

997 Glen Cove Avenue

Suite 5

Glen Head NY 11545

**Phone:** 800-451-6434 (toll-free)

**Fax:** 516-671-4055

**Email:** [hgf1@hgfound.org](mailto:hgf1@hgfound.org)

[www.hgfound.org](http://www.hgfound.org)

- **MAGIC Foundation**

4200 Cantera Drive #106

Warrenville IL 60555

**Phone:** 800-362-4423 (Toll-free Parent Help Line); 630-836-8200

**Fax:** 630-836-8181

**Email:** [contactus@magicfoundation.org](mailto:contactus@magicfoundation.org)

[www.magicfoundation.org](http://www.magicfoundation.org)

## Molecular Genetics

*Information in the Molecular Genetics and OMIM tables may differ from that elsewhere in the GeneReview: tables may contain more recent information. —ED.*

**Table A.** Floating-Harbor Syndrome: Genes and Databases

| Gene                  | Chromosome Locus        | Protein                        | Locus-Specific Databases     | HGMD                  | ClinVar               |
|-----------------------|-------------------------|--------------------------------|------------------------------|-----------------------|-----------------------|
| <a href="#">SRCAP</a> | <a href="#">16p11.2</a> | <a href="#">Helicase SRCAP</a> | <a href="#">SRCAP @ LOVD</a> | <a href="#">SRCAP</a> | <a href="#">SRCAP</a> |

Data are compiled from the following standard references: gene from [HGNC](#); chromosome locus from [OMIM](#); protein from [UniProt](#). For a description of databases (Locus Specific, HGMD, ClinVar) to which links are provided, click [here](#).

**Table B.** OMIM Entries for Floating-Harbor Syndrome ([View All in OMIM](#))

|                        |   |
|------------------------|---|
| <a href="#">136140</a> | FLOATING-HARBOR SYNDROME; FLHS            |
| <a href="#">611421</a> | SNF2-RELATED CBP ACTIVATOR PROTEIN; SRCAP |

## Molecular Pathogenesis

**Introduction.** Helicase SRCAP is a nuclear protein that mediates different intracellular signaling pathways as well as chromatin remodeling. The encoded protein is an ATPase that is necessary for the incorporation of a histone variant into nucleosomes.

SRCAP functions as a transcriptional activator for CREB and CBP-mediated transcription, along with Notch-mediated and steroid receptor-mediated transcription [Hood et al 2016]. Alteration in SRCAP has the potential for producing widespread target-gene dysregulation.

**Mechanism of disease causation.** Unknown. However, the non-random clustering of pathogenic variants (see Genotype-Phenotype Correlations) that predict truncated SRCAP strongly suggests a dominant-negative disease mechanism due to loss of one or more critical domain(s) – for instance, the three C-terminal AT-hook DNA-binding motifs (see Hood et al [2016] for details of SRCAP domains).

**Table 5.** Notable SRCAP Pathogenic Variants

| Reference Sequences         | DNA Nucleotide Change        | Predicted Protein Change     | Comment [Reference]  |
|-----------------------------|------------------------------|------------------------------|--|
| <a href="#">NM_006662.2</a> | <a href="#">c.7303C&gt;T</a> | <a href="#">p.Arg2435Ter</a> | Recurrent pathogenic variants [Hood et al 2012, Nikkel et al 2013] |
| <a href="#">NP_006653.2</a> | <a href="#">c.7330C&gt;T</a> | <a href="#">p.Arg2444Ter</a> |  |

Variants listed in the table have been provided by the authors. *GeneReviews* staff have not independently verified the classification of variants.

*GeneReviews* follows the standard naming conventions of the Human Genome Variation Society ([varnomen.hgvs.org](#)). See [Quick Reference](#) for an explanation of nomenclature.

## Cancer and Benign Tumors

The Cancer Genome Atlas summarizes somatic pathogenic variants in genes (including SRCAP) involved in chromatin remodeling which may have a role in regulating genes in human malignancies. SRCAP is frequently mutated in numerous cancers including melanomas, lung cancers, stomach adenocarcinoma, and colorectal adenocarcinoma [Chen et al 2016].

## References

### Literature Cited

Amita M, Srivastava P, Agarwal D, Phadke SR. Floating-Harbor syndrome. *Indian J Pediatr.* 2016;83:896–7. PubMed PMID: 27206688.

- Budisteanu M, Bögershausen N, Papuc SM, Moosa S, Thoenes M, Riga D, Arghir A, Wollnik B. Floating-Harbor syndrome: presentation of the first Romanian patient with a SRCAP mutation and review of the literature. *Balkan J Med Genet*. 2018;21:83–6. PubMed PMID: 30425916.
- Chen J, Herlong FH, Stroehlein JR, Mishra L. Mutations of chromatin structure regulating genes in human malignancies. *Curr Protein Pept Sci*. 2016;17:411–37. PubMed PMID: 26796307.
- Choi EM, Lee DH, Kang SJ, Shim YJ, Kim HS, Kim JS, Jeong JI, Ha JS, Jang JH. The first Korean case with Floating-Harbor syndrome with a novel SRCAP mutation diagnosed by targeted exome sequencing. *Korean J Pediatr*. 2018;61:403–6. PubMed PMID: 30304910.
- Coughlin DJ, Miller CA, Schuette AJ. Treatment of moyamoya disease and unruptured intracranial aneurysm in Floating-Harbor syndrome. *World Neurosurg*. 2017;104:1049.e1–1049.e6. PubMed PMID: 28549641.
- Dong S, Han J, Chen H, Liu T, Huen MSY, Yang Y, Guo C, Huang J. The human SRCAP chromatin remodeling complex promotes DNA-end resection. *Curr Biol*. 2014;24:2097–110. PubMed PMID: 25176633.
- Hood RL, Lines MA, Nikkel SM, Schwartzentruber J, Beaulieu C, Nowaczyk MJ, Allanson J, Kim CA, Wiczorek D, Moilanen JS, Lacombe D, Gillissen-Kaesbach G, Whiteford ML, Quaio CR, Gomy I, Bertola DR, Albrecht B, Platzer K, McGillivray G, Zou R, McLeod DR, Chudley AE, Chodirker BN, Marcadier J, Majewski J, Bulman DE, White SM, Boycott KM, et al. Mutations in SRCAP, encoding SNF2-related CREBBP activator protein, cause Floating-Harbor syndrome. *Am J Hum Genet*. 2012;90:308–13. PubMed PMID: 22265015.
- Hood RL, Schenkel LC, Nikkel SM, Ainsworth PJ, Pare G, Boycott KM, Bulman DE, Sadikovic B. The defining DNA methylation signature of Floating-Harbor syndrome. *Sci Rep*. 2016;6:38803. PubMed PMID: 27934915.
- Kehrer M, Beckmann A, Wyduba J, Finckh U, Dufke A, Gaiser U, Tzschach A. Floating-Harbor syndrome: SRCAP mutations are not restricted to exon 34. *Clin Genet*. 2014;85:498–9. PubMed PMID: 23763483.
- Le Goff C, Mahaut C, Bottani A, Doray B, Goldenberg A, Moncla A, Odent S, Nitschke P, Munnich A, Faivre L, Cormier-Daire V. Not all Floating-Harbor syndrome cases are due to mutations in exon 34 of SRCAP. *Hum Mutat*. 2013;34:88–92. PubMed PMID: 22965468.
- Milani D, Scuvera G, Gatti M, Tolva G, Bonarrigo F, Esposito S, Gervasini C. Perthes disease: A new finding in Floating-Harbor syndrome. *Am J Med Genet A*. 2018;176:703–6. PubMed PMID: 29383823.
- Nagasaki K, Asami T, Sato H, Ogawa Y, Kikuchi T, Saitoh A, Ogata T, Fukami M. Long-term follow-up study for a patient with Floating-Harbor syndrome due to a hotspot SRCAP mutation. *Am J Med Genet A*. 2014;164A:731–5. PubMed PMID: 24375913.
- Nikkel SM, Dauber A, de Munnik S, Connolly M, Hood RL, Caluseriu O, Hurst J, Kini U, Nowaczyk MJ, Afenjar A, Albrecht B, Allanson JE, Balestri P, Ben-Omran T, Brancati F, Cordeiro I, da Cunha BS, Delaney LA, Destrée A, Fitzpatrick D, Forzano F, Ghali N, Gillies G, Harwood K, Hendriks YM, Héron D, Hoischen A, Honey EM, Hoefsloot LH, Ibrahim J, Jacob CM, Kant SG, Kim CA, Kirk EP, Knoers NV, Lacombe D, Lee C, Lo IF, Lucas LS, Mari F, Mericq V, Moilanen JS, Møller ST, Moortgat S, Pilz DT, Pope K, Price S, Renieri A, Sá J, Schoots J, Silveira EL, Simon ME, Slavotinek A, Temple IK, van der Burgt I, de Vries BB, Weisfeld-Adams JD, Whiteford ML, Wiczorek D, Wit JM, Yee CF, Beaulieu CL; FORGE Canada Consortium. White SM, Bulman DE, Bongers E, Brunner H, Feingold M, Boycott KM. The phenotype of Floating-Harbor syndrome: clinical characterization of 52 individuals with mutations in exon 34 of SRCAP. *Orphanet J Rare Dis*. 2013;8:63. PubMed PMID: 23621943.
- Rahbari R, Wuster A, Lindsay SJ, Hardwick RJ, Alexandrov LB, Turki SA, Dominiczak A, Morris A, Porteous D, Smith B, Stratton MR. UK10K Consortium, Hurler ME. Timing, rates and spectra of human germline mutation. *Nat Genet*. 2016;48:126–33. PubMed PMID: 26656846.
- Seifert W, Meinecke P, Krüger G, Rossier E, Heinritz W, Wüsthof A, Horn D. Expanded spectrum of exon 33 and 34 mutations in SRCAP and follow-up in patients with Floating-Harbor syndrome. *BMC Med Genet*. 2014;15:127. PubMed PMID: 25433523.

Shields LBE, Peppas DS, Rosenberg E. Renal calculus in Floating-Harbor syndrome: a case report. *J Pediatr Health Care*. 2019;33:97–101. PubMed PMID: 30205917.

Singh A, Bhatia HP, Sood S, Sharma N, Mohan A. A novel finding of oligodontia and ankyloglossia in a 14-year-old with Floating-Harbor syndrome. *Spec Care Dentist*. 2017;37:318–21. PubMed PMID: 29210485.

## Chapter Notes

### Revision History

- 23 May 2019 (sw) Comprehensive update posted live
- 24 January 2013 (cd) Revision: prenatal testing available clinically
- 29 November 2012 (me) Review posted live
- 26 June 2012 (mjmn) Original submission

## License

GeneReviews® chapters are owned by the University of Washington. Permission is hereby granted to reproduce, distribute, and translate copies of content materials for noncommercial research purposes only, provided that (i) credit for source (<http://www.genereviews.org/>) and copyright (© 1993-2020 University of Washington) are included with each copy; (ii) a link to the original material is provided whenever the material is published elsewhere on the Web; and (iii) reproducers, distributors, and/or translators comply with the [GeneReviews® Copyright Notice and Usage Disclaimer](#). No further modifications are allowed. For clarity, excerpts of GeneReviews chapters for use in lab reports and clinic notes are a permitted use.

For more information, see the [GeneReviews® Copyright Notice and Usage Disclaimer](#).

For questions regarding permissions or whether a specified use is allowed, contact: [admasst@uw.edu](mailto:admasst@uw.edu).