



## Autosomal Dominant Robinow Syndrome

Synonym: Fetal Face Syndrome

Maian Roifman, MD,<sup>1</sup> Han Brunner, MD,<sup>2</sup> Jamie Lohr, MD,<sup>3</sup> Juliana Mazzeu, PhD,<sup>4</sup> and David Chitayat, MD<sup>5</sup>

Created: January 8, 2015; Revised: October 3, 2019.

### Summary

#### Clinical characteristics

Autosomal dominant Robinow syndrome (ADRS) is characterized by skeletal findings (short stature, mesomelic limb shortening predominantly of the upper limbs, and brachydactyly), genital abnormalities (in males: micropenis / webbed penis, hypoplastic scrotum, cryptorchidism; in females: hypoplastic clitoris and labia majora), dysmorphic facial features (widely spaced and prominent eyes, frontal bossing, anteverted nares, midface retrusion), dental abnormalities (including malocclusion, crowding, hypodontia, late eruption of permanent teeth), bilobed tongue, and occasional prenatal macrocephaly that persists postnatally. Less common findings include renal anomalies, radial head dislocation, vertebral abnormalities such as hemivertebrae and scoliosis, nail dysplasia, cardiac defects, cleft lip/palate, and (rarely) cognitive delay. When present, cardiac defects are a major cause of morbidity and mortality.

A variant of Robinow syndrome, associated with osteosclerosis and caused by a heterozygous pathogenic variant in *DVLL1*, is characterized by normal stature, persistent macrocephaly, increased bone mineral density with skull osteosclerosis, and hearing loss, in addition to the typical features described above.

#### Diagnosis/testing

The diagnosis of autosomal dominant Robinow syndrome is established in a proband with typical suggestive findings and/or by the identification of a heterozygous pathogenic variant in *DVLL1*, *DVL3*, or *WNT5A* through molecular genetic testing.

**Author Affiliations:** 1 Division of Clinical and Metabolic Genetics, Department of Paediatrics, The Hospital for Sick Children; Prenatal Diagnosis and Medical Genetics Program, Department of Obstetrics and Gynecology, Mount Sinai Hospital; University of Toronto, Toronto, Canada; Email: maian.roifman@gmail.com. 2 Department of Human Genetics, Radboud University Medical Center, Nijmegen, The Netherlands; Email: han.brunner@radboudumc.nl. 3 Division of Pediatric Cardiology, Adult Congenital and Cardiovascular Genetics Program, University of Minnesota Amplatz Children's Hospital, Minneapolis, Minnesota; Email: lohrr003@umn.edu. 4 Division of Clinical Medicine, Faculty of Medicine, University of Brasília, Brasília, Brazil; Email: julianamazzeu@pq.cnpq.br. 5 Prenatal Diagnosis and Medical Genetics Program, Department of Obstetrics and Gynecology, Mount Sinai Hospital; Division of Clinical and Metabolic Genetics, Department of Paediatrics, The Hospital for Sick Children; University of Toronto, Toronto, Canada; Email: dchitayat@mtsinai.on.ca.

## Management

*Treatment of manifestations:* Corrective surgeries as needed for cryptorchidism, abnormal penile insertion / penoscrotal position, and cleft lip/palate. Hormone therapy may be helpful for males with micropenis. Orthodontic treatment is typically required.

*Surveillance:* Measurement of head circumference regularly in infancy and throughout childhood. Developmental assessment every three months in infancy and every six months to one year thereafter, or more frequently as needed if cognitive delays are identified. Dental evaluation every six to 12 months or as recommended. Periodic hearing assessments in childhood. Regular cardiac and renal assessment as needed by respective specialists if abnormalities are identified.

*Evaluation of relatives at risk:* Evaluation of the sibs of a proband in order to identify as early as possible those who would benefit from institution of treatment and surveillance.

*Pregnancy management:* Pregnancy in affected women appears to be generally uncomplicated. For an affected fetus, cesarean section may be required for abnormal presentation and/or cephalopelvic disproportion.

## Genetic counseling

ADRS is inherited in an autosomal dominant manner. A proband may have the disorder as a result of either an inherited or *de novo* pathogenic variant. Each child of an individual with ADRS has a 50% chance of inheriting the pathogenic variant; however, the severity of the clinical manifestations cannot be predicted from the results of molecular genetic testing. Prenatal testing for pregnancies at increased risk is possible if the *DVL1*, *DVL3*, or *WNT5A* pathogenic variant has been identified in an affected family member.

## Diagnosis

### Suggestive Findings

Autosomal dominant Robinow syndrome (ADRS) **should be suspected** in individuals with the following clinical and family history findings [Mazzeu et al 2007, Person et al 2010, Beiraghi et al 2011, Roifman et al 2015].

### Clinical Findings

#### Skeletal

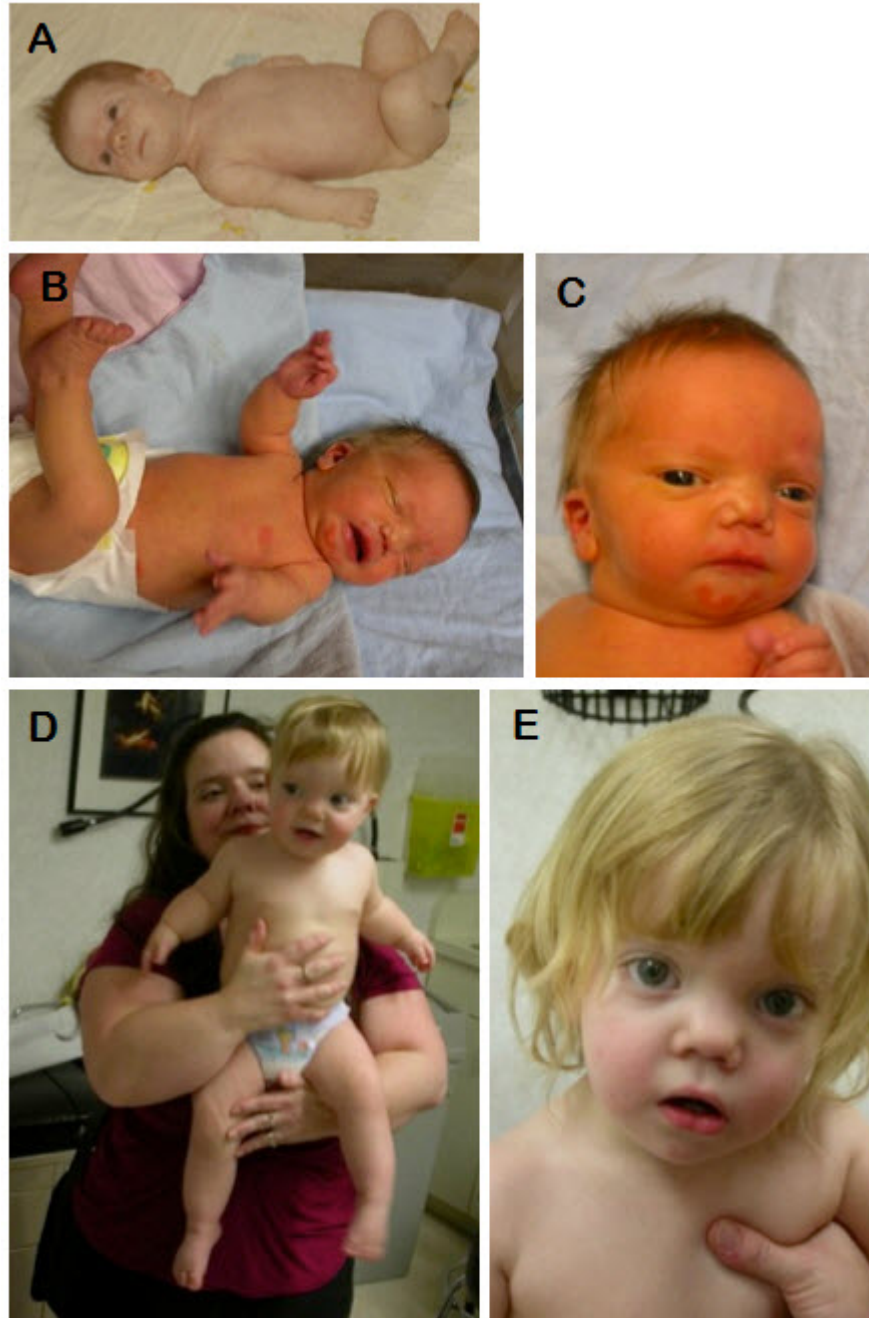
- Short stature
- Mesomelic limb shortening predominantly affecting the upper limbs
- Brachydactyly

#### Genital

- In males: micropenis / webbed penis, hypoplastic scrotum, and cryptorchidism
- In females: hypoplastic clitoris and labia majora

#### Craniofacial

- Dysmorphic facial features resembling a fetal face: widely spaced and prominent eyes, high anterior hairline, frontal bossing, depressed nasal bridge, short nose with anteverted nares, wide nasal bridge with a broad nasal tip, long philtrum, midface retrusion, and low-set ears (see Figure 1 and Figure 2)
- Dental malocclusion, dental crowding and hypodontia, late eruption of permanent teeth, wide retromolar ridge, alveolar ridge deformation, and bilobed tongue



**Figure 1.** A mother and son, both affected with *WNT5A*-associated autosomal dominant Robinow syndrome

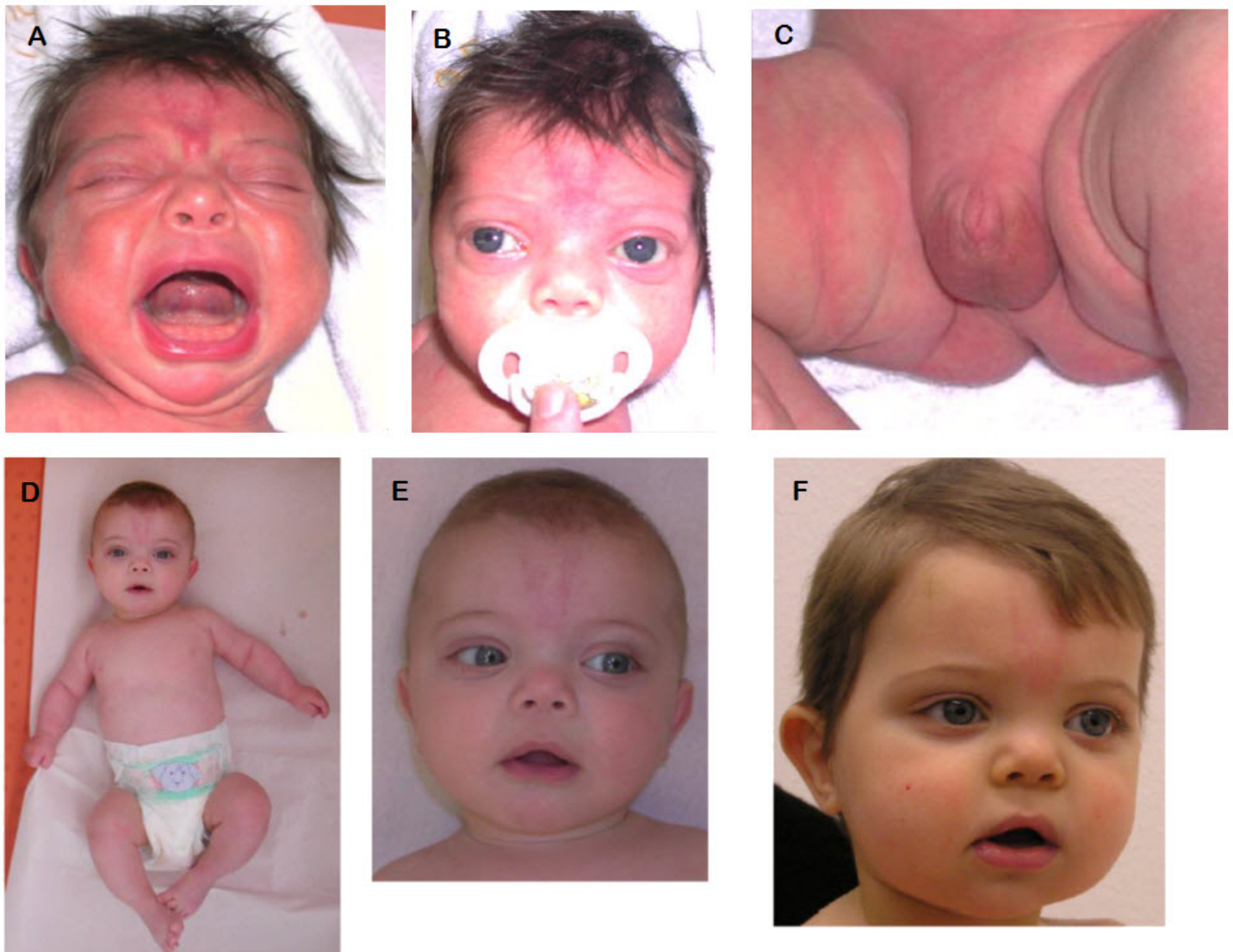A. Affected mother in infancy

B, C. Affected son at birth

D. Mother (age 39 years) and son (age 2 years)

E. Son at age three years

Note the widely spaced and prominent eyes, high anterior hairline, frontal bossing, depressed nasal bridge, short nose with anteverted nares, wide nasal bridge with a broad nasal tip, long philtrum, midface retrusion, low-set ears, and limb shortening predominantly affecting the upper limbs.



**Figure 2.** A boy with *WNT5A*-associated autosomal dominant Robinow syndrome at different ages. Note the widely spaced and prominent eyes, high anterior hairline, frontal bossing, depressed nasal bridge, short nose with anteverted nares, wide nasal bridge with a broad nasal tip, long philtrum, low-set ears (A, B, D, E, F), genital hypoplasia (C) and limb shortening predominantly affecting the upper limbs (D).

## Family History

Family history is consistent with autosomal dominant inheritance. Note: Absence of a known family history of autosomal dominant Robinow syndrome does not preclude the diagnosis.

## Establishing the Diagnosis

The diagnosis of autosomal dominant Robinow syndrome **is established** in a proband with typical suggestive findings and/or by the identification of a heterozygous pathogenic variant in *DVL1*, *DVL3*, or *WNT5A* through molecular genetic testing (see Table 1).

Note: If a heterozygous pathogenic variant is not identified in *DVL1*, *DVL3*, or *WNT5A*, it is appropriate to exclude the presence of biallelic *ROR2* or *NXN* pathogenic variants (which cause [autosomal recessive Robinow syndrome](#)) and a heterozygous pathogenic variant in *FZD2* (which causes autosomal dominant omodysplasia type 2).

Molecular genetic testing approaches can include a combination of **gene-targeted testing** (concurrent or serial single-gene testing, multigene panel) and **comprehensive genomic testing** (exome sequencing, genome sequencing):

- **Single-gene testing.** Sequence analysis detects small intragenic deletions/insertions and missense, nonsense, and splice site variants; typically, exon or whole-gene deletions/duplications are not detected. Perform sequence analysis of *DVL1* and the *DVL3* first. Sequence analysis of *WNT5A* should be considered either concurrently or as a reflex if no pathogenic variants are identified in *DLV1* or *DLV3*.  
Note: All reported disease-associated variants in *DVL1* and *DVL3* are frameshift variants located in the ultimate and penultimate exons (14 and 15).
- **A multigene panel** that includes *DVL1*, *DVL3*, *WNT5A*, *FZD2*, *ROR2*, *NXN*, and other genes of interest (see Differential Diagnosis) is most likely to identify the genetic cause of the condition at the most reasonable cost while limiting identification of variants of uncertain significance and pathogenic variants in genes that do not explain the underlying phenotype. Note: (1) The genes included in the panel and the diagnostic sensitivity of the testing used for each gene vary by laboratory and are likely to change over time. (2) Some multigene panels may include genes not associated with the condition discussed in this *GeneReview*. (3) In some laboratories, panel options may include a custom laboratory-designed panel and/or custom phenotype-focused exome analysis that includes genes specified by the clinician. (4) Methods used in a panel may include sequence analysis, deletion/duplication analysis, and/or other non-sequencing-based tests. Care should be taken that coverage of exons 14 and 15 in *DVL1* and *DVL3* are well covered in the assay (see Footnote 12 in Table 1).

For an introduction to multigene panels click [here](#). More detailed information for clinicians ordering genetic tests can be found [here](#).

- More comprehensive genomic testing (when available) including exome sequencing and genome sequencing may be considered. Such testing may provide or suggest a diagnosis not previously considered (e.g., mutation of a different gene or genes that results in a similar clinical presentation).

For an introduction to comprehensive genomic testing click [here](#). More detailed information for clinicians ordering genomic testing can be found [here](#).

**Table 1.** Molecular Genetic Testing Used in Autosomal Dominant Robinow Syndrome

Gene <sup>1, 2</sup>	Proportion of Autosomal Dominant Robinow Syndrome Attributed to Pathogenic Variants in Gene	Proportion of Pathogenic Variants <sup>3</sup> Detectable by Sequence Analysis <sup>4, 5</sup>
<i>DVL1</i>	18 probands <sup>6</sup> (unknown number of probands tested)	>99% <sup>7</sup>
<i>DVL3</i>	7 probands <sup>8</sup> (unknown number of probands tested)	>99% <sup>7</sup>
<i>WNT5A</i>	8 probands <sup>9</sup> (unknown number of probands tested)	>99%

Table 1. continued from previous page.

Gene <sup>1, 2</sup>	Proportion of Autosomal Dominant Robinow Syndrome Attributed to Pathogenic Variants in Gene	Proportion of Pathogenic Variants <sup>3</sup> Detectable by Sequence Analysis <sup>4, 5</sup>
Unknown <sup>10, 11</sup>		NA

1. Genes are listed in alphabetic order.

2. See Table A. Genes and Databases for chromosome locus and protein.

3. See Molecular Genetics for information on allelic variants detected in this gene.

4. Sequence analysis detects variants that are benign, likely benign, of uncertain significance, likely pathogenic, or pathogenic. Pathogenic variants may include small intragenic deletions/insertions and missense, nonsense, and splice site variants; typically, exon or whole-gene deletions/duplications are not detected. For issues to consider in interpretation of sequence analysis results, click [here](#).

5. Since ADRS occurs through a gain-of-function mechanism and large intragenic deletion or duplication has not been reported, testing for intragenic deletions or duplications is unlikely to identify a disease-causing variant.

6. Bunn et al [2015], White et al [2015], White et al [2016], White et al [2018]

7. All pathogenic variants identified to date are frameshift variants.

8. White et al [2016], Danyel et al [2018], White et al [2018]

9. Person et al [2010], Roifman et al [2015], Xiong et al [2016], White et al [2018]

10. Pathogenic variants in *RAC3* and *GPC4* have also been reported in single individuals who had been given a clinical diagnosis of Robinow syndrome [White et al 2018].

11. Omodysplasia type 2, caused by pathogenic variants in *FZD2*, shares many clinical features with ADRS; it is unclear if these two conditions are part of a phenotypic spectrum (see Differential Diagnosis).

## Clinical Characteristics

### Clinical Description

Autosomal dominant Robinow syndrome (ADRS) is a skeletal dysplasia in which affected individuals typically have short stature, mesomelic limb shortening (predominantly of the upper limbs), and brachydactyly. A variety of other (variably present) anomalies may also suggest the diagnosis.

**Facial.** Craniofacial features of ADRS are summarized in Suggestive Findings. These features are most recognizable at birth or in early childhood. The distinctive facial features become less apparent with age.

- In addition to macrocephaly, prominent facial features in adulthood include widely spaced eyes, wide nasal bridge, and broad nasal tip.
- Dental malocclusion becomes apparent in early childhood and persists into adulthood, affecting the permanent dentition as well. One case of persistent primary dentition requiring extraction at age 18 years has been reported [Roifman et al 2015].

**Skeletal.** Short stature is almost always present at birth and sometimes identified prenatally (on detailed fetal ultrasound) as early as age 20 weeks [Mazzeu et al 2007, Castro et al 2014, Roifman et al 2015].

- Short stature persists into adulthood but is typically not severe, with a final adult height either at or just below -2SD in most cases [Mazzeu et al 2007, Person et al 2010, Roifman et al 2015].
- Some individuals with *DVLI*-associated ADRS have a unique skeletal phenotype (see Phenotype Correlations by Gene).

**Urogenital.** Hypoplastic genitalia are apparent at birth for males and females.

- Micropenis may be present. However, in some cases, the penis may measure normally but appear small because it is webbed / embedded in the scrotal tissue or because of the abnormal insertion of penile crura inferiorly and posteriorly onto the medial aspect of the ischial tuberosity [Wilcox et al 1997]. These cases may be amenable to cosmetic reconstruction (see Management).

- Micropenis appears to be common in ADRS (and is a constant feature of [autosomal recessive Robinow syndrome](#)).
- The frequency of penoscrotal transposition in ADRS is unclear at this time.

**Puberty and fertility.** To the best of the authors' knowledge, both puberty and fertility are normal and affected females can carry pregnancies to term; delivery may need to be by cesarean section due to cephalopelvic disproportion.

**Cardiac abnormalities** occur in a minority (<25%) of individuals with ADRS.

- Cardiac defects reported in Robinow syndrome (in both dominant and recessive types) include pulmonary valve stenosis/atresia, atrial septal defect, ventricular septal defect, coarctation of the aorta, tetralogy of Fallot, and tricuspid atresia [Webber et al 1990, Al-Ata et al 1998].
- When present, cardiac defects are a major cause of morbidity and mortality.

**Hearing loss (bilateral, mixed)** has been reported in some individuals with *DVLI*-associated ADRS [Bunn et al 2015, White et al 2015].

**Umbilical hernia** has been reported in some individuals with *DVLI*-associated ADRS [White et al 2015].

**Intelligence** is usually normal; cognitive delay occurs in a minority of individuals with ADRS.

**Other features less frequently seen** (<25% of cases) [Mazzeu et al 2007, Person et al 2010, Roifman et al 2015]:

- Renal anomalies (usually hydronephrosis)
- Radial head dislocation
- Vertebral abnormalities and scoliosis
- Persistent primary teeth requiring extraction
- Nail dysplasia
- Cleft lip/palate

## Phenotype Correlations by Gene

***DVLI***. A subset of individuals with *DVLI*-associated ADRS exhibit a final stature in the low-normal range, increased bone mineral density with osteosclerosis of the skull, and macrocephaly (ranging from +2.5SD to > +6SD) [Bunn et al 2015, White et al 2015].

***DVL3***. Three out of four individuals with *DVL3*-associated ADRS had cardiac abnormalities; osteosclerosis has not been reported.

***WNT5A***. Five families with *WNT5A*-associated ADRS harbor domain-specific pathogenic variants in the *WNT5A* protein and may represent a clinical phenotype with classic ADRS features (with characteristic face, short stature, mesomelic limb shortening, and genital hypoplasia) [Roifman et al 2015].

## Genotype-Phenotype Correlations

No clear genotype-phenotype correlation is known.

## Prevalence

ADRS is very rare. The exact prevalence of the disorder is unknown. Fewer than 80 families with ADRS have been described in the literature.

## Genetically Related (Allelic) Disorders

No phenotypes other than those discussed in this *GeneReview* are known to be associated with pathogenic variants in *DVL1*, *DVL3*, or *WNT5A*.

## Differential Diagnosis

**ROR2-related Robinow syndrome** is an autosomal recessive skeletal dysplasia caused by biallelic pathogenic variants in *ROR2*. Features similar to those of ADRS include the distinctive fetal face features, short stature, mesomelic limb shortening, and genital hypoplasia. *ROR2*-related Robinow syndrome appears to be more severe than ADRS, with renal anomalies, congenital heart defects, vertebral defects, rib fusions, scoliosis, and cognitive delay occurring more frequently than in ADRS. A distinguishing feature of *ROR2*-related Robinow syndrome is clefting of the distal phalanges, mainly of the thumbs.

**NXN-related Robinow syndrome** (OMIM 618529), also inherited in an autosomal recessive manner, was described in three individuals with biallelic *NXN* pathogenic variants from two unrelated families. All three had classic clinical findings of Robinow syndrome including typical craniofacial features, mesomelic shortening, and brachydactyly [White et al 2018]. One individual, born to consanguineous parents, was homozygous for a nonsense *NXN* variant; the two affected sibs in the other family had compound heterozygous *NXN* pathogenic variants.

Note: The *NXN* protein is a relevant partner in the *WNT5A* signaling pathway that is intimately involved in Robinow syndrome causation. *ROR2* binds to *WNT5A* and interacts with *FZD2*. The effect of this interaction is routed to disheveled proteins (*DVL1*, *DVL3*) that are further stabilized by *NXN*. This complex activates JNK signaling responsible for cytoskeletal reorganization and cell polarity.

**Aarskog syndrome** (OMIM 305400) is an X-linked disorder caused by mutation of *FGD1*. Facial features (high anterior hairline, frontal bossing, widely spaced eyes, and anteverted nares) are similar to those of ADRS. Pulmonary valve stenosis has been reported. Genital hypoplasia in males with Aarskog syndrome is characterized by a shawl scrotum in contrast to the wider spectrum of genital hypoplasia found in ADRS. Other distinguishing features include widow's peak and ligamentous laxity. The vertebral abnormalities and delayed teeth eruption of ADRS are not observed in Aarskog syndrome. Typical limb abnormalities in Aarskog syndrome include brachydactyly, syndactyly, and fifth-finger clinodactyly.

**Autosomal dominant Opitz G/BBB syndrome (ADOS)** and **X-linked Opitz G/BBB syndrome (XLOS)** are associated with deletion in 22q11.2 and mutation of *MIDI1*, respectively. Similarities with ADRS include facial features (high anterior hairline, frontal bossing, widely spaced eyes, wide nasal bridge, anteverted nares) and genitourinary abnormalities (hypospadias, cryptorchidism, hypoplastic/bifid scrotum). XLOS is also characterized by laryngotracheoesophageal defects (not found in ADRS) and brain abnormalities, developmental delay, and cleft lip and/or palate (much more common in ADOS and XLOS [50% of affected individuals] than ADRS). ADOS and XLOS are not usually associated with short stature or mesomelic limb shortening.

**Achondroplasia** is an autosomal dominant disorder caused by mutation of *FGFR3*. Facial features characteristic of achondroplasia are similar to those of ADRS (macrocephaly, high anterior hairline and frontal bossing, depressed nasal bridge, pointed nose, and midface retrusion). Individuals with achondroplasia have a larger head circumference than those with ADRS, continued macrocephaly throughout life, and an increased incidence of hydrocephalus. Distinctive skeletal features in achondroplasia include trident appearance of the fingers, lumbar gibbus and hypotonia in infancy, hyperlordosis, bowing of the legs later in childhood, and more severe shortening of all long bones. Widely spaced eyes are not a feature of achondroplasia.



**Omodysplasia type 2** (OMIM 164745) is a rare autosomal dominant disorder characterized by skeletal findings, hypoplastic male genitalia (including micropenis, hypospadias, and cryptorchidism), and dysmorphic facial features. Distinct features include normal stature, rhizomelic upper-limb shortening, shortened first metacarpals, and shortened humeri with hypoplastic condyles. The legs are normal. Facial features include frontal bossing, depressed nasal bridge with bifid nasal tip, and a long philtrum. Individuals with omodysplasia type 2 do not have widely spaced eyes. A heterozygous pathogenic variant in *FZD2* was found in four families with omodysplasia type 2 [White et al 2018]. Given the phenotypic overlap between omodysplasia type 2 and Robinow syndrome, some have postulated that this may actually fall into the clinical spectrum of Robinow syndrome with predominant short humeri and radial head dislocation.

## Management

### Evaluations Following Initial Diagnosis

To establish the extent of disease and needs in an individual diagnosed with autosomal dominant Robinow syndrome (ADRS), the evaluations summarized in Table 2 (if not performed as part of the evaluation that led to the diagnosis) are recommended.

**Table 2.** Recommended Evaluations Following Initial Diagnosis in Individuals with Autosomal Dominant Robinow Syndrome

System/Concern	Evaluation	Comment
<b>Craniofacial</b>	Clinical assessment for presence of orofacial clefting	Consider referral to craniofacial team
	Orthodontics consultation	For misaligned teeth or persistent primary dentition
<b>Ears</b>	Hearing assessment	
<b>Cardiovascular</b>	Echocardiogram	To evaluate for congenital heart defect
<b>Genitourinary</b>	Renal ultrasound	To assess for renal anomalies & hydronephrosis
	Females: pelvic ultrasound	To evaluate for müllerian anomalies
	Males: assessment for abnormal penile insertion / penoscrotal position & cryptorchidism	Urology consultation, as appropriate
		If micropenis present, consider consultation w/ endocrinologist for possible hormone therapy
<b>Musculoskeletal</b>	Radiographs of limbs, chest, vertebrae, & skull	To establish the extent of skeletal involvement
<b>Neurologic</b>	Assessment for developmental delay	Referral for formal neuropsychiatric/cognitive testing if present
<b>Other</b>	Consultation w/clinical geneticist &/or genetic counselor	

### Treatment of Manifestations

**Table 3.** Treatment of Manifestations in Individuals with Autosomal Dominant Robinow Syndrome

Manifestation/Concern	Treatment	Considerations/Other
Cleft lip/palate	Surgical correction	Management by multidisciplinary craniofacial team recommended
Misaligned teeth or persistent primary dentition	Standard orthodontic treatment	
Hearing loss	Standard treatment	See <a href="#">Hereditary Hearing Loss and Deafness Overview</a> .

Table 3. continued from previous page.

Manifestation/Concern	Treatment	Considerations/Other
Congenital heart defects	Standard treatment per cardiologist &/or cardiothoracic surgery	
Cryptorchidism	Orchidopexy	
Abnormal penile insertion / penoscrotal position	Referral to urologist	Discussion of potential surgical correction
Micropenis	Consideration of hormonal therapy <sup>1</sup>	Referral to endocrinologist

1. Injection of human chorionic gonadotropin and testosterone improved penile length and testicular volume in three boys with severe micropenis [Soliman et al 1998].

## Surveillance

Table 4. Recommended Surveillance for Individuals with Autosomal Dominant Robinow Syndrome

System/Concern	Evaluation	Frequency
<b>Craniofacial</b>	Dental evaluation	Every 6 months to 1 year or per dental professional
<b>Ears</b>	Hearing assessment	In childhood
<b>Cardiovascular</b>	Standard monitoring in those w/cardiac involvement	Per cardiologist
<b>Genitourinary</b>	Standard monitoring in those w/renal involvement	Per urologist
<b>Neurologic</b>	Assessment of developmental progress	At each visit in childhood/adolescence

## Evaluation of Relatives at Risk

It is appropriate to evaluate the sibs of a proband in order to identify as early as possible those who would benefit from institution of treatment and surveillance. If the *DVL1*, *DVL3*, or *WNT5A* pathogenic variant in the family is known, molecular genetic testing can be used to clarify the genetic status of at-risk sibs.

See Genetic Counseling for issues related to testing of at-risk relatives for genetic counseling purposes.

## Pregnancy Management

Pregnancy in affected women appears to be generally uncomplicated. For an affected fetus, cesarean section may be required for abnormal presentation and/or cephalopelvic disproportion. Breech presentation requiring cesarean section has been reported in one case of ADRS [Roifman et al 2015].

## Therapies Under Investigation

Search [ClinicalTrials.gov](https://clinicaltrials.gov) in the US and [EU Clinical Trials Register](https://clinicaltrialsregister.eu) in Europe for information on clinical studies for a wide range of diseases and conditions. Note: There may not be clinical trials for this disorder.

## Genetic Counseling

*Genetic counseling is the process of providing individuals and families with information on the nature, inheritance, and implications of genetic disorders to help them make informed medical and personal decisions. The following section deals with genetic risk assessment and the use of family history and genetic testing to clarify genetic status for family members. This section is not meant to address all personal, cultural, or ethical issues that individuals may face or to substitute for consultation with a genetics professional. —ED.*

## Mode of Inheritance

Robinow syndrome caused by pathogenic variants in *DVLI*, *DVL3*, or *WNT5A* is inherited in an autosomal dominant manner.

## Risk to Family Members

### Parents of a proband

- Some individuals diagnosed with autosomal dominant Robinow syndrome (ADRS) have an affected parent.
- A proband with ADRS may have the disorder as a result of a *de novo* pathogenic variant. The proportion of cases caused by a *de novo* pathogenic variant is unknown.
- Recommendations for the evaluation of parents of a proband with an apparent *de novo* *DVLI*, *DVL3*, or *WNT5A* pathogenic variant include complete physical examination for associated clinical features and testing for the pathogenic variant identified in the proband.
- If the *DVLI*, *DVL3*, or *WNT5A* pathogenic variant found in the proband cannot be detected in the leukocyte DNA of either parent and/or neither parent has clinical evidence of the disorder, the pathogenic variant likely occurred *de novo*. Alternatively, a proband with ADRS may have the disorder as a result of germline mosaicism in one of the parents.
- Evaluation of the parents may determine that one is affected but has escaped previous diagnosis because of a milder phenotypic presentation. Therefore, an apparently negative family history cannot be confirmed until appropriate evaluations have been performed.
- Note: If the parent is the individual in whom the pathogenic variant first occurred s/he may have somatic mosaicism for the variant and may be mildly/minimally affected [White et al 2018].

**Sibs of a proband.** The risk to the sibs of a proband depends on the genetic status of the proband's parents:

- If a parent of the proband is affected, the risk to the sibs is 50%. However, the severity of the clinical manifestations cannot be predicted from the results of molecular genetic testing.
- When the parents are clinically unaffected, the risk to the sibs of a proband appears to be low.
- If the *DVLI*, *DVL3*, or *WNT5A* pathogenic variant found in the proband cannot be detected in the leukocyte DNA of either parent, the risk to sibs is presumed to be slightly greater than that of the general population (though still <1%) because of the theoretic possibility of parental germline mosaicism.

**Offspring of a proband.** Each child of an individual with ADRS has a 50% chance of inheriting the pathogenic variant; however, the severity of the clinical manifestations cannot be predicted from the results of molecular genetic testing.

**Other family members.** The risk to other family members depends on the status of the proband's parents: if a parent is affected, his or her family members may be at risk.

## Related Genetic Counseling Issues

See Management, Evaluation of Relatives at Risk for information on evaluating at-risk relatives for the purpose of early diagnosis and treatment.

**Considerations in families with an apparent *de novo* pathogenic variant.** When neither parent of a proband with an autosomal dominant condition has the pathogenic variant or clinical evidence of the disorder, the pathogenic variant likely occurred *de novo*. However, non-medical explanations including alternate paternity or maternity (e.g., with assisted reproduction) and undisclosed adoption could also be explored.

### Family planning

- The optimal time for determination of genetic risk and discussion of the availability of prenatal testing is before pregnancy.
- It is appropriate to offer genetic counseling (including discussion of potential risks to offspring and reproductive options) to young adults who are affected.

**DNA banking** is the storage of DNA (typically extracted from white blood cells) for possible future use. Because it is likely that testing methodology and our understanding of genes, allelic variants, and diseases will improve in the future, consideration should be given to banking DNA of affected individuals.

## Prenatal Testing and Preimplantation Genetic Diagnosis

**Molecular genetic testing.** Once the *DVL1*, *DVL3*, or *WNT5A* pathogenic variant has been identified in an affected family member, prenatal testing for a pregnancy at increased risk and preimplantation genetic diagnosis are possible. However, the severity of clinical manifestations cannot be predicted from the results of molecular genetic testing.

**Fetal ultrasound evaluation.** Short long bones (measuring -2SD), macrocephaly, and typical facial features (widely spaced eyes, broad nasal bridge, and flattened frontal bone) can be detected by fetal ultrasound evaluation at approximately 20 weeks' gestation [Castro et al 2014, Roifman et al 2015].

## Resources

*GeneReviews staff has selected the following disease-specific and/or umbrella support organizations and/or registries for the benefit of individuals with this disorder and their families. GeneReviews is not responsible for the information provided by other organizations. For information on selection criteria, click [here](#).*

- **Human Growth Foundation (HGF)**  
997 Glen Cove Avenue  
Suite 5  
Glen Head NY 11545  
**Phone:** 800-451-6434 (toll-free)  
**Fax:** 516-671-4055  
**Email:** [hgf1@hgfound.org](mailto:hgf1@hgfound.org)  
[www.hgfound.org](http://www.hgfound.org)
- **Little People of America, Inc. (LPA)**  
250 El Camino Real  
Suite 201  
Tustin CA 92780  
**Phone:** 888-572-2001 (toll-free); 714-368-3689  
**Fax:** 714-368-3367  
**Email:** [info@lpaonline.org](mailto:info@lpaonline.org)  
[www.lpaonline.org](http://www.lpaonline.org)
- **MAGIC Foundation**  
4200 Cantera Drive #106  
Warrenville IL 60555  
**Phone:** 800-362-4423 (Toll-free Parent Help Line); 630-836-8200  
**Fax:** 630-836-8181  
**Email:** [contactus@magicfoundation.org](mailto:contactus@magicfoundation.org)  
[www.magicfoundation.org](http://www.magicfoundation.org)

- **Restricted Growth Association (RGA)**

PO Box 15755

Solihull B93 3FY

United Kingdom

**Phone:** +44 0300 111 1970**Fax:** +44 0300 111 2454**Email:** [office@restrictedgrowth.co.uk](mailto:office@restrictedgrowth.co.uk)[www.restrictedgrowth.co.uk](http://www.restrictedgrowth.co.uk)

## Molecular Genetics

Information in the Molecular Genetics and OMIM tables may differ from that elsewhere in the GeneReview: tables may contain more recent information. —ED.

**Table A.** Autosomal Dominant Robinow Syndrome: Genes and Databases

Gene	Chromosome Locus	Protein	HGMD	ClinVar
<i>DVL1</i>	1p36.33	Segment polarity protein dishevelled homolog DVL-1	DVL1	DVL1
<i>DVL3</i>	3q27.1	Segment polarity protein dishevelled homolog DVL-3	DVL3	DVL3
<i>WNT5A</i>	3p14.3	Protein Wnt-5a	WNT5A	WNT5A

Data are compiled from the following standard references: gene from [HGNC](#); chromosome locus from [OMIM](#); protein from [UniProt](#). For a description of databases (Locus Specific, HGMD, ClinVar) to which links are provided, click [here](#).

**Table B.** OMIM Entries for Autosomal Dominant Robinow Syndrome ([View All in OMIM](#))

164975	WINGLESS-TYPE MMTV INTEGRATION SITE FAMILY, MEMBER 5A; WNT5A
180700	ROBINOW SYNDROME, AUTOSOMAL DOMINANT 1; DRS1
601365	DISHEVELLED 1; DVL1
601368	DISHEVELLED 3; DVL3
616331	ROBINOW SYNDROME, AUTOSOMAL DOMINANT 2; DRS2
616894	ROBINOW SYNDROME, AUTOSOMAL DOMINANT 3; DRS3

## Molecular Pathogenesis

The Wnt family of proteins regulates critical morphogenic events, including embryonic patterning, and cell differentiation, growth, and migration. Wnt signaling pathways fall into two categories: canonic, which involve  $\beta$ -catenin, and non-canonic, which are independent of  $\beta$ -catenin.

WNT5A, which functions in the both the canonic and non-canonic pathways, is a Wnt family member critical for developmental processes requiring cell migration (reviewed in Nishita et al [2010]). WNT5A is a known coreceptor of the orphan tyrosine kinase receptor, ROR2 [Oishi et al 2003, Mikels & Nusse 2006, Schambony & Wedlich 2007], which would explain the overlap in clinical phenotype of WNT5A- and ROR2-associated Robinow syndrome.

*DVL1* and *DVL3* encode segment polarity protein disheveled homolog DVL-1 (DVL1) and DVL-3, respectively, which are essential downstream mediators of Wnt signaling – specifically, the Wnt5a-ROR2 non-canonic pathway [White et al 2015, White et al 2016].

## DVL1

**Gene structure.** *DVL1* comprises 15 exons.

**Pathogenic variants.** Thus far, all variants associated with ADRS are frameshift variants in exons 14 and 15 (see examples in Table 5) [Bunn et al 2015, White et al 2015, White et al 2016]. The proposed gain-of-function mechanism (see **Abnormal gene product**) suggests that these variants, located in the ultimate and penultimate exons, produce truncated transcripts that escape nonsense-mediated decay.

**Table 5.** *DVL1* Selected Pathogenic Variants

DNA Nucleotide Change	Predicted Protein Change	Reference Sequences
c.1505_1517del13	p.His502ProfsTer143	NM_004421.2 NP_004412.2
c.1508delC	p.Pro503ArgfsTer146	
c.1519delT	p.Trp507GlyfsTer142	
c.1529delG	p.Gly510ValfsTer139	
c.1562delC	p.Pro521HisfsTer128	
c.1570_1571delinsC	p.Phe524ProfsTer125	
c.1576_1583delinsG	p.Pro526AlafsTer121	
c.1615delA	p.Ser539AlafsTer110	

Variants listed in the table have been provided by the authors. *GeneReviews* staff have not independently verified the classification of variants.

*GeneReviews* follows the standard naming conventions of the Human Genome Variation Society ([varnomen.hgvs.org](http://varnomen.hgvs.org)). See [Quick Reference](#) for an explanation of nomenclature.

**Normal gene product.** *DVL1* is a member of the disheveled family of intracellular scaffolding proteins, located downstream of the Wnt receptor. *DVL1* plays a role in transducing both canonical and non-canonical Wnt signaling (OMIM 601365).

**Abnormal gene product.** The abnormal gene product resulting from a frameshift in exons 14 and 15 is thought to impair Wnt signaling via a gain-of-function or dominant-negative mechanism, which may explain the unique skeletal phenotype of normal stature, macrocephaly, and increased bone density [White et al 2015].

## DVL3

**Gene structure.** *DVL3* comprises 15 exons.

**Pathogenic variants.** Similar to *DVL1*, the majority of variants associated with ADRS are frameshift variants in exons 14 and 15 (see examples in Table 6) [White et al 2015, White et al 2016]. Splice site variants at the intron 14 acceptor site have also been reported [White et al 2016]. The proposed gain-of-function mechanism (see **Abnormal gene product**) suggests that these variants, located in the ultimate and penultimate exons, produce truncated transcripts that escape nonsense-mediated decay.

**Table 6.** *DVL3* Selected Pathogenic Variants

DNA Nucleotide Change	Predicted Protein Change	Reference Sequences
c.1585delG	p.Ala592ProfsTer139	NM_004423.3 NP_004414.3
c.1617delG	p.Gln539HisfsTer129	
c.1715-2A>G	p.?	
c.1715-1G>A	p.?	
c.1716delC	p.Ser573ValfsTer95	
c.1749delC	p.Ser583ArgfsTer85	

Variants listed in the table have been provided by the authors. *GeneReviews* staff have not independently verified the classification of variants.

*GeneReviews* follows the standard naming conventions of the Human Genome Variation Society ([varnomen.hgvs.org](http://varnomen.hgvs.org)). See [Quick Reference](#) for an explanation of nomenclature.

**Normal gene product.** *DVL3* is a member of the disheveled family of intracellular scaffolding proteins, located downstream of the Wnt receptor. *DVL3* plays a role in transducing both canonic and non-canonic Wnt signaling.

**Abnormal gene product.** The abnormal gene product resulting from a frameshift in exons 14 and 15 is thought to impair Wnt signaling via a gain-of-function or dominant-negative mechanism, which may explain the unique skeletal phenotype of normal stature, macrocephaly, and increased bone density [White et al 2015].

## WNT5A

**Gene structure.** *WNT5A* comprises five exons. Alternate splicing results in multiple transcript variants. For a detailed summary of gene and protein information, see Table A, **Gene**.

**Pathogenic variants.** Pathogenic missense variants (Table 7) as well as an in-frame duplication and an in-frame deletion/duplication have been identified in five families with autosomal dominant Robinow syndrome [Person et al 2010, Roifman et al 2015, White et al 2018].

**Table 7.** *WNT5A* Selected Pathogenic Variants

DNA Nucleotide Change (Alias <sup>1</sup> )	Predicted Protein Change (Alias <sup>1</sup> )	Reference Sequences
c.206G>A	p.Cys69Tyr	NM_003392.4 NP_003383.2
c.248G>C	p.Cys83Ser	
c.257A>G <sup>2</sup>	p.Tyr86Cys	
c.544_545delinsTC (544-545CT>TC)	p.Cys182Ser (Cys182Arg)	

Variants listed in the table have been provided by the authors. *GeneReviews* staff have not independently verified the classification of variants.

*GeneReviews* follows the standard naming conventions of the Human Genome Variation Society ([varnomen.hgvs.org](http://varnomen.hgvs.org)). See [Quick Reference](#) for an explanation of nomenclature.

1. Variant designation that does not conform to current naming conventions
2. Two families had this variant.

**Normal gene product.** *WNT5A* is critical for developmental processes requiring cell migration [reviewed in Nishita et al 2010]. The three-dimensional structure of the *WNT5A* protein is still unknown.

The *WNT5A* signaling gradient in the limb bud has been shown to control limb elongation [Gao et al 2011]. The murine ortholog of *WNT5A* was also shown to control several steps in gonadal development of mice models [Tevosian 2012].

**Abnormal gene product.** Based on a *WNT5A* homology model using the experimentally solved structure of *WNT8*, Roifman et al [2015] showed that pathogenic variants found in all individuals with *WNT5A*-associated ADRS appear to be located on one side of the protein and may affect interactions with other proteins in the Wnt pathway by disrupting normal complex formation and/or intra-protein bonds. Although the mechanism of *WNT5A*-related disease is not known, the reports of disease-associated missense or in-frame variants clustering in specific locations of the protein could indicate altered protein function as a disease mechanism.

## References

### Literature Cited

- Al-Ata J, Paquet M, Teebi AS. Congenital heart disease in Robinow syndrome. *Am J Med Genet.* 1998;77:332–3. PubMed PMID: 9600746.
- Beiraghi S, Leon-Salazar V, Larson BE, John MT, Cunningham ML, Petryk A, Lohr JL. Craniofacial and intraoral phenotype of Robinow syndrome forms. *Clin Genet.* 2011;80:15–24. PubMed PMID: 21496006.
- Bunn KJ, Daniel P, Rosken HS, O'Neill AC, Cameron-Christie SR, Morgan T, Brunner HG, Lai A, Kunst HPM, Markie DM, Robertson SP. Mutations in *DVL1* cause an osteosclerotic form of Robinow syndrome. *Am J Hum Genet.* 2015;96:623–30. PubMed PMID: 25817014.
- Castro S, Peraza E, Barraza A, Zapata M. Prenatal diagnosis of Robinow syndrome: a case report. *J Clin Ultrasound.* 2014;42:297–300. PubMed PMID: 24151023.
- Danyel M, Kortüm F, Dathe K, Kutsche K, Horn D. Autosomal dominant Robinow syndrome associated with a novel *DVL3* splice mutation. *Am J Med Genet A.* 2018;176:992–6. PubMed PMID: 29575616.
- Gao B, Song H, Bishop K, Elliot G, Garrett L, English MA, Andre P, Robinson J, Sood R, Minami Y, Economides AN, Yang Y. Wnt signaling gradients establish planar cell polarity by inducing *Vangl2* phosphorylation through *Ror2*. *Dev Cell.* 2011;20:163–76. PubMed PMID: 21316585.
- Mazzeu JF, Pardono E, Vianna-Morgante AM, Richieri-Costa A, Ae Kim C, Brunoni D, Martelli L, de Andrade CE, Colin G, Otto PA. Clinical characterization of autosomal dominant and recessive variants of Robinow syndrome. *Am J Med Genet A.* 2007;143:320–5. PubMed PMID: 17256787.
- Mikels AJ, Nusse R. Purified *Wnt5a* protein activates or inhibits beta-catenin-TCF signaling depending on receptor context. *PLoS Biol.* 2006;4:e115. PubMed PMID: 16602827.
- Nishita M, Enomoto M, Yamagata K, Minami Y. Cell/tissue-tropic functions of *Wnt5a* signaling in normal and cancer cells. *Trends Cell Biol.* 2010;20:346–54. PubMed PMID: 20359892.
- Oishi I, Suzuki H, Onishi N, Takada R, Kani S, Ohkawara B, Koshida I, Suzuki K, Yamada G, Schwabe GC, Mundlos S, Shibuya H, Takada S, Minami Y. The receptor tyrosine kinase *Ror2* is involved in non-canonical *Wnt5a*/JNK signalling pathway. *Genes Cells.* 2003;8:645–54. PubMed PMID: 12839624.
- Person AD, Beiraghi S, Sieben CM, Hermanson S, Neumann AN, Robu ME, Schleiffarth JR, Billington CJ Jr, van Bokhoven H, Hoogeboom JM, Mazzeu JF, Petryk A, Schimmenti LA, Brunner HG, Ekker SC, Lohr JL. *WNT5A* mutations in patients with autosomal dominant Robinow syndrome. *Dev Dyn.* 2010;239:327–37. PubMed PMID: 19918918.
- Roifman M, Marcelis CL, Paton T, Marshall C, Silver R, Lohr JL, Yntema HG, Venselaar H, Kayserili H, van Bon B, Seaward G, Brunner HG, Chitayat D, et al. De novo *WNT5A*-associated autosomal dominant Robinow syndrome suggests specificity of genotype and phenotype. *Clin Genet.* 2015;87:34–41. PubMed PMID: 24716670.



- Schambony A, Wedlich D. Wnt-5A/Ror2 regulate expression of XPAPC through an alternative noncanonical signaling pathway. *Dev Cell*. 2007;12:779–92. PubMed PMID: 17488628.
- Soliman AT, Rajab A, Alsalmi I, Bedair SM. Recessive Robinow syndrome: with emphasis on endocrine functions. *Metabolism*. 1998;47:1337–43. PubMed PMID: 9826209.
- Tevosian SG. Gone without the WNT: a requirement for WNT5A in germ cell migration and testis development. *Biol Reprod*. 2012;86:1–2. PubMed PMID: 21957192.
- Webber SA, Wargowski DS, Chitayat D, Sandor GG. Congenital heart disease and Robinow syndrome: coincidence or an additional component of the syndrome? *Am J Med Genet*. 1990;37:519–21. PubMed PMID: 2260599.
- White J, Mazzeu JF, Hoischen A, Jhangiani SN, Gambin T, Calijorne Alcino M, Penney S, Saraiva JM, Hove H, Skovby F, Kayserili H, Estrella E, Vulto-van Silfhout A, Steehouwer M, Muzny DM, Sutton VR, Gibbs RA, Lupski JR, Brunner HG, van Bon BWM, Carvalho CMB, et al. CVL1 frameshift mutations clustering in the penultimate exon cause autosomal-dominant Robinow syndrome. *Am J Hum Genet*. 2015;96:612–22. PubMed PMID: 25817016.
- White JJ, Mazzeu JF, Coban-Akdemir Z, Bayram Y, Bahrambeigi V, Hoischen A, van Bon BWM, Gezdirici A, Gulec EY, Ramond F, Touraine R, Thevenon J, Shinawi M, Beaver E, Heeley J, Hoover-Fong J, Durmaz CD, Karabulut HG, Marzioglu-Ozdemir E, Cayir A, Duz MB, Seven M, Price S, Ferreira BM, Vianna-Morgante AM, Ellard S, Parrish A, Stals K, Flores-Daboub J, Jhangiani SN, Gibbs RA, Brunner HG, Sutton VR, Lupski JR, Carvalho CMB, et al. WNT signaling perturbations underlie the genetic heterogeneity of Robinow syndrome. *Am J Hum Genet*. 2018;102:27–43. PubMed PMID: 29276006.
- White JJ, Mazzeu JF, Hoischen A, Bayram Y, Withers M, Gezdirici A, Kimonis V, Steehouwer M, Jhangiani SN, Muzny DM, Gibbs RA, van Bon BWM, Sutton VR, Lupski JR, Brunner HG, Carvalho CMB, et al. DVL3 alleles resulting in a -1 frameshift of the last exon mediate autosomal-dominant Robinow syndrome. *Am J Hum Genet*. 2016;98:553–61. PubMed PMID: 26924530.
- Wilcox DT, Quinn FM, Ng CS, Dicks-Mireaux C, Mouriquand PD. Redefining the genital abnormality in the Robinow syndrome. *J Urol*. 1997;157:2312–4. PubMed PMID: 9146662.
- Xiong S, Chitayat D, Wei X, Zhu J, Lu W, Sun LM, Chopra M. A novel de-novo WNT5A mutation in a Chinese patient with Robinow syndrome. *Clin Dysmorphol*. 2016;25:186–9. PubMed PMID: 27092434.

## Chapter Notes

### Revision History

- 3 October 2019 (aa) Revision: *NXN* added to Differential Diagnosis
- 9 August 2018 (ma) Comprehensive update posted live
- 30 July 2015 (aa) Revision: *DVL1* and related citations added
- 8 January 2015 (me) Review posted live
- 18 June 2014 (mr) Original submission

## License

GeneReviews® chapters are owned by the University of Washington. Permission is hereby granted to reproduce, distribute, and translate copies of content materials for noncommercial research purposes only, provided that (i) credit for source (<http://www.genereviews.org/>) and copyright (© 1993-2020 University of Washington) are included with each copy; (ii) a link to the original material is provided whenever the material is published elsewhere on the Web; and (iii) reproducers, distributors, and/or translators comply with the [GeneReviews® Copyright Notice and Usage Disclaimer](#). No further modifications are allowed. For clarity, excerpts of GeneReviews chapters for use in lab reports and clinic notes are a permitted use.

For more information, see the [GeneReviews® Copyright Notice and Usage Disclaimer](#).

For questions regarding permissions or whether a specified use is allowed, contact: [admasst@uw.edu](mailto:admasst@uw.edu).