

Immunodeficiency in cartilage-hair hypoplasia: Pathogenesis, clinical course and management

Svetlana Vakkilainen^{1,2,3}  | Mervi Taskinen¹ | Outi Mäkitie^{1,2,3,4,5}

¹Pediatric Research Center, Children's Hospital, University of Helsinki and Helsinki University Hospital, Helsinki, Finland

²Folkhälsan Research Center, Institute of Genetics, Helsinki, Finland

³Research Program for Clinical and Molecular Metabolism, Faculty of Medicine, University of Helsinki, Helsinki, Finland

⁴Department of Molecular Medicine and Surgery and Center for Molecular Medicine, Karolinska Institutet, Stockholm, Sweden

⁵Department of Clinical Genetics, Karolinska University Hospital, Stockholm, Sweden

Correspondence

Svetlana Vakkilainen, Children's Hospital, Pediatric Research Center, University of Helsinki and Helsinki University Hospital, Stenbäckinkatu 9, PL 347, 00029 HUS, Helsinki, Finland
Email: svetlana.vakkilainen@helsinki.fi

Funding information

This work was supported by the Sigrid Jusélius Foundation (OM), the Academy of Finland (OM), the Folkhälsan Research Foundation (OM), the Novo Nordisk Foundation (OM), the Helsinki University Hospital Research Funds (MT, OM), the Swedish Childhood Cancer Foundation (OM) and the Foundation for Pediatric Research (MT, OM).

Abstract

Cartilage-hair hypoplasia (CHH) is an autosomal recessive syndromic immunodeficiency with skeletal dysplasia, short stature, hypotrichosis, variable degree of immune dysfunction and increased incidence of anaemia, Hirschsprung disease and malignancy. CHH is caused by variants in the *RMRP* gene, encoding the untranslated RNA molecule of the mitochondrial RNA-processing endoribonuclease, which participates in for example cell cycle regulation and telomere maintenance. Recent studies have expanded our understanding of the complex pathogenesis of CHH. Immune dysfunction has a major impact on clinical course and prognosis. Clinical features of immune dysfunction are highly variable, progressive and include infections, lung disease, immune dysregulation and malignancy. Mortality is increased compared with the general population, due to infections, malignancy and pulmonary disease. Several risk factors for early mortality have been reported in the Finnish CHH cohort and can be used to guide management. Newborn screening for severe combined immunodeficiency can possibly be of prognostic value in CHH. Regular follow-up by a multidisciplinary team should be implemented to address immune dysfunction in all patients with CHH, also in asymptomatic cases. Haematopoietic stem cell transplantation can cure immune dysfunction, but its benefits in mildly symptomatic patients with CHH remain debatable. Further research is needed to understand the mechanisms behind the variability of clinical features, to search for potential molecular treatment targets, to examine and validate risk factors for early mortality outside the Finnish CHH cohort and to develop management guidelines. This review focuses on the pathogenesis, clinical course and management of CHH.

This is an open access article under the terms of the Creative Commons Attribution License, which permits use, distribution and reproduction in any medium, provided the original work is properly cited.

© 2020 The Authors. *Scandinavian Journal of Immunology* published by John Wiley & Sons Ltd on behalf of The Scandinavian Foundation for Immunology

1 | INTRODUCTION

Cartilage-hair hypoplasia (CHH, OMIM # 250250) is a rare form of skeletal dysplasia, but also a syndromic primary immunodeficiency disorder. The first reports of patients with CHH date back to the 1960s and describe the main clinical features of metaphyseal dysplasia, short-limbed short stature, sparse and fine hair, Hirschsprung disease and unusual infections, for example, fatal varicella.^{1,2} In 1990s, additional patient series demonstrated that the majority of subjects with CHH had defective immunity and increased susceptibility to infections.^{3,4} The associated growth failure leads to severe disproportionate short stature, adult heights ranging on average from 110 to 140 cm.⁴ Other clinical features, such as anaemia and high incidence of malignancy, particularly lymphoma, contributing significantly to overall mortality, have been reported in 2000s.⁵⁻⁷

This autosomal recessive condition is caused by variants in the non-coding RNA gene *RMRP* (RNA component of the mitochondrial RNA-processing endoribonuclease, RNase MRP).⁸ CHH is enriched in the Amish and Finnish populations, with respective incidence of 1 in 1340 and 1 in 23 000 births.³ Although the pathogenesis of CHH remains incompletely understood, the defective *RMRP* functioning ultimately impairs cell proliferation and differentiation.^{9,10} Here, we review current knowledge and recent advances in understanding the disease pathogenesis, clinical course and management of CHH.

2 | THE PATHOGENESIS OF IMMUNODEFICIENCY IN CHH

2.1 | The impact of *RMRP* variants

The human RNase MRP complex, which includes the RNA component *RMRP* and ten associated proteins, is a ubiquitously expressed endoribonuclease (Figure 1).^{11,12} Distinct regions of the RNA component are involved in the interactions with protein subunits and various *RMRP* variants selectively reduce the efficacy of RNA-to-protein binding.¹³ The *RMRP* gene (OMIM 157660) is located at chromosome 9p13.3, and the transcript contains approximately 265 nucleotides. Over 130 variants in *RMRP* have been reported in patients with CHH.¹⁴ While n.71A > G (NCBI reference sequence: NR_003051.3, previously known as n.70A > G) is the founder variant in the Amish and Finnish CHH populations and the most common disease-causing variant in several other populations, it has not been reported in Brazilian or Japanese cohorts of patients with CHH.¹⁵⁻¹⁷ Most of the CHH-associated variants locate to the transcribed region but several variants and deletions and duplications in the promoter region have also been reported.¹²

Duplications in the promoter region, but also variants in the transcribed region, lead to the reduced (but not absent) expression levels of *RMRP*.^{11,18} While variants in the promoter region can directly reduce RNA expression levels, variants in the transcribed region lead to RNA instability, probably impair the secondary structure of *RMRP* itself or RNase MRP complex, reducing its enzymatic activity (Figure 1).^{12,18,19} Homozygous variants in the promoter region have only rarely been described, suggesting the incompatibility of *RMRP* absence with life.¹²

Genotype does not correlate with clinical severity in CHH, and highly variable phenotype has been described in siblings with identical *RMRP* variants.^{4,20} This variability can be explained by epigenetic factors or allelic differences. Interestingly, variants in *POPI*, encoding one of the proteins in the RNase MRP complex (hPOP1, Figure 1), have been described in patients with skeletal dysplasia and decreased peripheral blood mononuclear cell proliferation ability.²¹ Furthermore, variants in *NEPRO*, encoding nucleolus and neural progenitor protein known to interact with multiple subunits of the RNase MRP complex, have been recently described in a patient with skeletal dysplasia and hair hypoplasia.²² Further studies are needed to test the hypothesis of whether allelic differences in *POPI* and genes encoding other proteins of the RNase MRP complex or interacting proteins can be responsible for the variability in CHH clinical phenotype.

2.2 | Genetic and cellular effects of defective RNase MRP function

Transcriptome has been examined in various cell types with *RMRP* variants. In peripheral blood leucocytes, 99 up-regulated and 38 down-regulated genes have been described.¹¹ Of these genes, the majority play a role in the immune system, cell cycle regulation, apoptosis or signal transduction. Recently, transcriptome analysis of fibroblasts from patients with CHH demonstrated 35 up- and 130 down-regulated genes. These genes are involved in chromosome organization, DNA packaging and binding, DNA replication and cell cycle pathways, as well as in PI3K-Akt signalling pathway.¹⁰ Experiments in HEK293 cells have revealed that *RMRP* can act as a reservoir for the production of small silencing RNAs that have been named RMRP-S1 and RMRP-S2.²³ These RNAs up- and down-regulate over 900 genes that are related to bone growth and development, haematopoiesis and cancer. Specific *RMRP* variants can impair the biogenesis of these silencing RNAs through alterations of secondary RNA structure, possibly explaining the variable clinical phenotype and disease severity in CHH.

Defective cell proliferation in CHH has been demonstrated in fibroblasts,¹⁰ granulocyte-macrophage progenitors from the bone marrow,²⁴ as well as in the peripheral blood

T lymphocytes.²⁵ The analysis of cell cycle in T lymphocytes from patients with CHH has demonstrated a higher proportion of cells in the G2/M phase, consistent with the reduced number of cell divisions and the impaired T-cell proliferation reported in CHH.²⁵ T cells from patients with CHH also showed an increased activation-induced apoptosis. Fibroblasts from patients with CHH show slower growth in culture, as well as prolonged cell cycle due to the delay in progression from G2 to G1, whereas the duration of mitosis is normal.¹⁰

The transfection of human fibroblasts with the *RMRP* construct carrying the n.71A > G variant results in severe impairment of cyclin B2 mRNA cleavage, explaining the delay in cell cycle progression.^{9,25} The degree of this cyclin mRNA processing defect has in turn been linked to the severity of immunodeficiency and haematologic abnormalities in CHH.⁹ Cyclin-dependent kinase (CDK) 2 mRNA levels are lower in fibroblasts from patients with CHH, as are levels of regulators of CDK1 target phosphorylation such as CDC25C and MAST-L.¹⁰ In addition, mRNA for the potent CDK inhibitor CDKN1A is up-regulated. These alterations are consistent

with malfunctioning of the main CDKs promoting progression through G2 phase.

In addition to the direct effects on the cell cycle, ribosome biogenesis is altered in CHH. The impaired *RMRP* functioning leads to cellular accumulation of rRNA precursors, consistent with a defective pre-rRNA processing.²⁶ The degree of rRNA cleavage impairment has been linked to the severity of bone dysplasia in CHH.⁹

These results suggest that *RMRP* variants interfere with normal cell cycle through pleiotropic effects including altered gene regulation, inadequate functioning of silencing RNAs and defective ribosome biogenesis. The impact of the *RMRP* variants on the functioning of other long non-coding RNAs and micro RNAs is yet to be discovered.

2.3 | Defective telomere maintenance

Telomeres are structures found at the ends of human chromosomes. Telomeres shorten with repetitive cell divisions and are then elongated by telomerase to maintain genomic

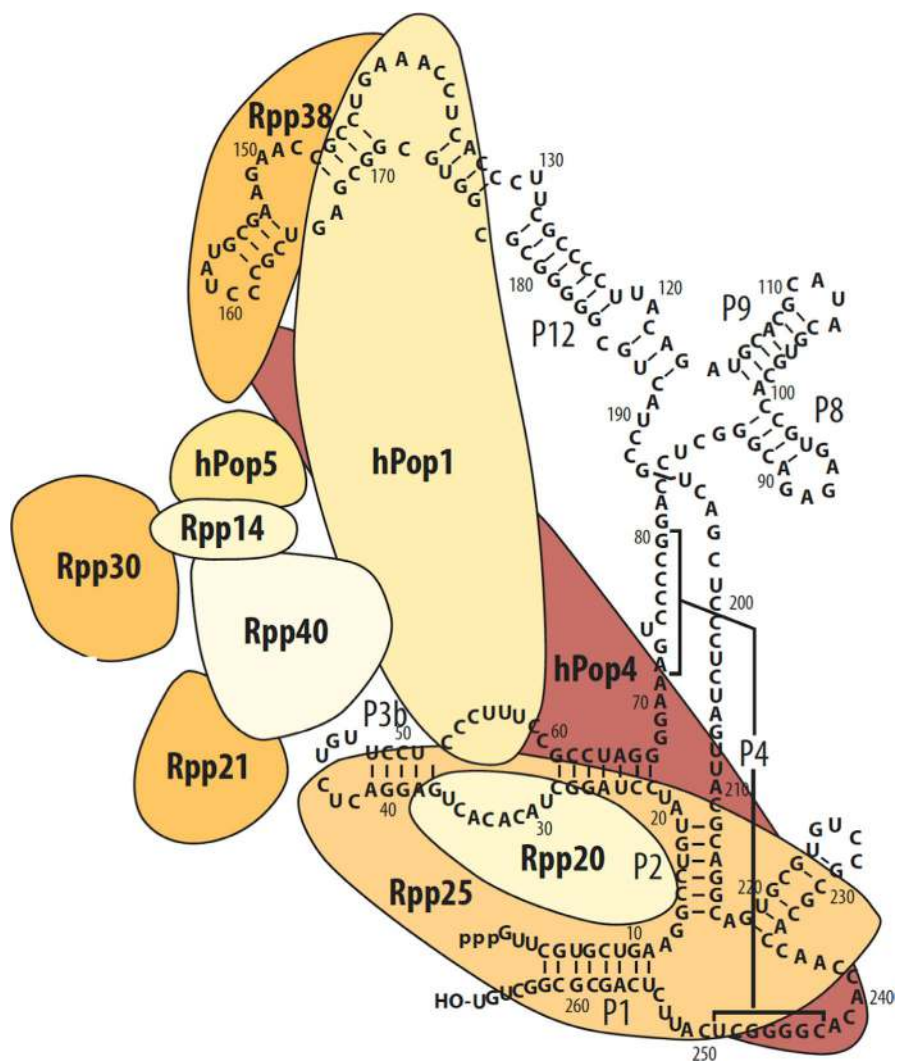


FIGURE 1 The structure of human mitochondrial RNA-processing ribonuclease, showing ten protein subunits and the secondary structure of the RNA component RMRP. Reproduced with permission from Taskinen et al¹⁸

integrity.^{27,28} The telomerase complex includes a non-coding RNA component *TERC*, a catalytic reverse transcriptase TERT and other proteins.²⁹ *RMRP* can form a ribonucleoprotein complex with TERT, producing double-stranded RNAs that serve as precursors to siRNA and regulate *RMRP* expression by a negative feedback mechanism.³⁰

Patients with CHH have shorter telomeres in the peripheral blood cells, measured by qPCR or by FISH.^{31,32} Telomere length is decreased in granulocytes and lymphocytes, particularly CD45RA+CD57+ mature natural killer or T lymphocytes, the furthest differentiated lymphocyte subset.³² Telomere length can therefore be decreased as a consequence of intensified proliferative activity of limited numbers of immune cells. However, telomerase activity is also impaired in CHH.³² In addition, many of the clinical features of CHH (short stature, bone marrow failure leading to anaemia and immunodeficiency, increased risk of malignancy) closely resemble other disorders of telomere maintenance, such as dyskeratosis congenita.^{33,34} Relative telomere length measured from peripheral blood DNA by qPCR was significantly shorter in children with CHH, but not in adults, compared with healthy controls.³¹ A similar trend—less pronounced deviation from normal in affected adults than in affected children—has been observed also in patients with pathogenic variants in telomere machinery genes.³⁵ These findings probably reflect the survival advantage of adult patients included in these studies.

Shortening of telomeres can trigger the activation of DNA damage response, which can explain the increased apoptosis of lymphocytes in CHH.^{25,35} Patients with short telomere syndromes can present with T-cell immunodeficiency in the absence of bone marrow failure, similar to patients with CHH.³⁵ Moreover, T-cell abnormalities in individuals with telomeropathies consist of depletion of naive T cells and accumulation of effector memory CD8+ cells, echoing the typical pattern of T-cell pathology in CHH.³⁶

Taken together, these findings suggest the pathogenetic role of impaired telomere maintenance in the development of immunologic abnormalities in CHH.

2.4 | Animal models of CHH

Attempts to generate a mouse model of CHH have failed due to the essential function of *RMRP* in early mouse development.³⁷ The insertion of DNA vectors upstream *RMRP* promoter to knockdown *RMRP* resulted in the early embryonic mouse lethality, supporting the hypothesis that *RMRP* depletion is incompatible with life. With the advances of gene-editing technologies, further studies could attempt introducing single CHH variants into mouse genome rather than aiming at complete knockdown of *RMRP*.

Recently, an *RMRP* knockout zebrafish created with the CRISP/Cas9 technology has been described, with the focus

on mechanisms leading to chondrodysplasia.¹⁴ The absence of *RMRP* expression was detrimental also in zebrafish as mutants survived only for 12–14 days; however, early developmental stages could be examined. This model demonstrated impaired chondrogenesis and bone ossification, inhibited cell proliferation, as well as increased apoptosis due to dysregulation of genes related to cell cycle and apoptosis. The abnormalities in chondrogenesis and bone ossification included upregulation of Wnt/ β -catenin pathway, and the inhibition of Wnt signalling partially alleviated the chondrodysplasia in mutant larvae. Further studies of the pathogenesis of immunodeficiency in CHH could benefit from the zebrafish model.

3 | CLINICAL MANIFESTATIONS OF IMMUNODEFICIENCY IN CHH

3.1 | Infections

Table 1 reviews the types, aetiology and frequency of infections in patients with CHH. Typically, infections include recurrent episodes of otitis media, sinusitis and pneumonia, caused by common pathogens like *Haemophilus influenzae*, *Moraxella catarrhalis* and *Streptococcus pneumoniae*.^{38,39} In severe cases, infections with *Pneumocystis jirovecii*, *Aspergillus spp*, herpes viruses (particularly varicella-zoster virus) have been described. Interestingly, not all patients experience recurrent or severe infections despite clearly impaired cellular immunity illustrated by low counts of lymphocyte subsets, as well as abnormal lymphocyte proliferation.^{4,25}

3.2 | Lung disease

Patients with CHH can develop a range of pulmonary manifestations, including recurrent respiratory tract infections and bronchiectasis, asthma and interstitial pneumonitis.^{40,41} The prevalence of bronchiectasis in a random cohort of 34 Finnish individuals with CHH is as high as 29%,⁴⁰ and even higher (43%–52%) in more severely affected patient groups.^{41,42} Interestingly, CHH patients with bronchiectasis have higher counts of T cells and higher levels of immunoglobulin G.⁴⁰ This can be explained by increased age, smoking, chronic infections or inflammation in the respiratory tract or by bronchiectasis-induced systemic immune response.⁴³ Apart from bronchiectasis, high rates (18%) of fibrosis-like lung changes, as well as fatal cases of lung emphysema, have been reported in patients with CHH.^{40,44}

In the Finnish CHH population, almost one third of patients are diagnosed with asthma,⁴⁰ compared to the prevalence of 6% in the general Finnish adult population.⁴⁵ This raises the possibility of incorrect diagnosis, given the absence of spirometry reference values for short-statured patients. Incorrect asthma

TABLE 1 Infectious complications of immunodeficiency in patients with cartilage-hair hypoplasia

Publication (reference)	N	Patient age, years	Increased susceptibility to infections		
			Definition	Prevalence, N (%)	Types of infections
Mäkitie 1993 ⁴	108	0.8-52	>6 uncomplicated URTI or ≥ 3 OM or Sin in the preceding year	58/103 (56)	OM, Pn, sepsis, severe varicella, Sin, URTI
Mäkitie 1998 ⁶²	35	0.1-55	>6 uncomplicated URTI or ≥ 3 OM, Sin or Pn per year	11/35 (11)	OM, Pn, Sin, URTI
Mäkitie 2000 ⁶³	20	1.7-16	>6 uncomplicated URTI or ≥ 3 OM, Sin or Pn in the preceding year	10/20 (50)	RTI
Hermanns 2006 ⁷¹	27	0.6-32	Inf incidence significantly above average in age-matched controls	12/22 (55)	RTI or other
Kavadas 2008 ²⁰	12	0.2-6, 44	Inf suggestive of immune deficiency	8/12 (67)	OM, Pn (Aspergillus, CMV, PJ), thrush
Rider 2009 ⁶¹	25	0.8-21	Life-threatening inf prior to age 2 years or > 2 bact inf/ year during the first 2 years of life	8/25 (32)	Disseminated HSV, parvovirus; meningitis (Haemophilus influenzae); OM; Pn (bact, CMV); sepsis; Sin; thrush
Bordon 2010 ⁴²	16	0.7-19	All patients required HSCT	16/16 (100)	Adeno enteritis and hepatitis; disseminated CMV, EBV, HSV; OM; Pn (bact, varicella-zoster virus); severe varicella
de la Fuente 2011 ²⁵	18	1-21	Severe and/or recurrent inf, not further defined	11/18 (61)	EBV-LP, molluscum, parvovirus, Pn (Aspergillus, CMV), sepsis, URTI
Ip 2015 ⁶⁰	13	0-9	All patients required HSCT	13/13 (100)	Disseminated adeno, CMV, EBV, HHV-6; EBV-LP; enteritis (adeno, HHV-6); OM; RTI; severe varicella
Kostjukovits 2017 ³⁷	56	0.7-68	OM and/or Sin requiring surgical interventions, sepsis, Pn, severe warts, recurrent and/or severe herpes virus inf	15/56 (27)	Boils, mucocutaneous HSV, OM, Pn, sepsis, severe varicella, severe warts, Sin

Abbreviations: Adeno, adenovirus; bact, bacterial; CMV, cytomegalovirus; EBV, Epstein-Barr virus; EBV-LP, EBV-related lymphoproliferation; HHV-6, human herpes virus 6; HSCT, haematopoietic stem cell transplantation; HSV, herpes simplex virus; inf, infection; N, number of patients; OM, otitis media; PJ, *Pneumocystis jirovecii*; Pn, pneumonia; Sin, sinusitis; URTI, upper respiratory tract infection.

diagnosis should be avoided, as inhaled corticosteroids in adults with bronchiectasis increase the risk of lung infections.⁴⁶ Therefore, pulmonary imaging is crucial in CHH patients with chronic respiratory symptoms to detect bronchiectasis and other pulmonary changes. Radiation exposure is an important issue in immunodeficient individuals prone to malignancies. Lung high-resolution computed tomography is considered the gold standard for diagnosing bronchiectasis; however, lung magnetic resonance imaging has demonstrated good performance in evaluation of bronchiectasis in patients with CHH.⁴⁰

Given the high prevalence of clinically relevant pulmonary changes in CHH, the reliable performance and safety of lung magnetic resonance imaging, scheduled lung imaging, should be performed in all adults and in symptomatic children with CHH. For asymptomatic patients, lung magnetic resonance imaging at baseline can be performed as early as possible beginning from the age when patients are able to undergo this diagnostic procedure without the need for general anaesthesia. The interval for repeated lung imaging should be

derived individually based on the patient clinical course and respiratory symptoms.

3.3 | Autoimmunity and immune dysregulation

Up to 11% of patients with CHH develop autoimmune diseases, with a large spectrum of manifestations, such as enteropathy, haemolytic anaemia, hypoparathyroidism, hypo- or hyperthyroidism, idiopathic thrombocytopenic purpura, juvenile rheumatoid arthritis, multifocal motor axonal neuropathy, narcolepsy, neutropenia and psoriasis.⁴⁷ Autoimmunity in adulthood correlates with recurrent pneumonia and sepsis episodes and is an independent risk factor for mortality in CHH, possibly reflecting the more profound immunodeficiency.^{44,47}

Immune dysregulation in CHH can also present with hepatosplenomegaly, severe eczema and inflammatory

granulomatous skin lesions.^{41,48,49} Granulomas in CHH may be positive for vaccine-strain rubella virus⁴⁹ and may be extremely difficult to treat.⁴⁸ Importantly, skin granulomas in individuals with CHH can also represent an EBV-associated lymphomatoid granulomatosis or T-cell lymphoproliferative disorder.^{50,51}

Persistent or recurrent diarrhoea can be another feature of immune dysregulation in CHH, seen in up to 22% of patients.⁴⁷ Some patients demonstrate concomitant duodenal villous atrophy despite negative coeliac screen.^{47,48} Further studies are needed to identify the underlying pathology and to establish optimal therapy in individuals with CHH suffering from chronic diarrhoea to prevent malnutrition and malignant transformation.

The mechanisms behind autoimmunity in CHH remain obscure. Although the protein microarray demonstrates broad IgG autoantibody multireactivity in serum samples of CHH patients compared to healthy controls, no clinical correlates have been established.⁵² However, these findings suggest that B-cell dysregulation may contribute to the autoimmune manifestations of CHH. A single patient with CHH and the absence of FOXP3 + T cells in the thymus has been described, underscoring the role of regulatory T cells in pathogenesis of immune dysregulation in CHH.⁵³ Thymic biopsy from this patient showed marked depletion of thymocytes, loss of corticomedullary demarcation and lack of Hassall corpuscles, suggesting that thymic abnormalities can explain the clinical features of Omenn syndrome seen in this subject with CHH.⁵³ The numbers of regulatory T cells are normal in peripheral blood in patients with CHH, including subjects with autoimmunity³⁶; however, the function of regulatory T cells has not been explored in CHH.

3.4 | Malignancy

Patients with CHH are at increased risk of malignancy, particularly lymphoma and basal cell carcinoma. Standardized incidence ratio (SIR) for any malignancy in Finnish patients with CHH is 7.0 compared to the general Finnish population, and up to 41% of surviving CHH patients can be estimated to have cancer diagnosis by the age of 65 years.⁷ The most frequent malignancy is non-Hodgkin lymphoma with SIR of 90. Median age at lymphoma diagnosis is 33 years, and SIR for non-Hodgkin lymphoma is 130 in the age group of 15-29 years.⁷ Skin cancer is also common in CHH, with SIR of 33 for basal cell carcinoma.⁷ The distribution of skin cancer in individuals with CHH (face, head and upper limbs) implies sun exposure as the main pathogenic mechanism.⁴⁴

The pathogenesis of malignancy in CHH is multifactorial, as patients with no clinical symptoms of immunodeficiency can develop malignancy during follow-up.⁴⁴ Lymphoproliferative disorders in subjects with CHH have

been reported to be Epstein-Barr virus-driven in some, but not all cases.^{50,51,54} Hence, not only impaired viral suppression, but other mechanisms, such as impaired telomere biology or chromosomal instability, may contribute to the increased risk of malignancies in CHH.^{55,56}

The impaired control of human papillomavirus (HPV) infection can play an important role in the pathogenesis of certain malignancies in CHH. Recent studies have reported 1) high rates (8/18, 44%) of cervical HPV positivity in women with CHH, and 2) correlation of warts with the development of skin cancer in individuals with CHH.^{44,57} Regular gynaecological and dermatological evaluation, as well as vaccination against HPV, should be a standard of care for patients with CHH.

Patients with CHH can develop malignancy without any previous clinical symptoms of immunodeficiency,⁴⁴ which calls for regular follow-up of mildly symptomatic patients with CHH. Early diagnosis of lymphoma either during a scheduled screening or through the thorough evaluation for non-specific mild symptoms improves survival.⁴⁴ Fatal lymphoma in CHH has been described as early as at the age of six years; therefore, screening (clinical, laboratory and by imaging, especially for prolonged or unusual symptoms) should be considered early in childhood.⁵⁸

3.5 | Laboratory features of immunodeficiency in CHH

Table 2 demonstrates the variability of blood immunologic parameters in patients with CHH. The most uniform laboratory immunologic feature is the decreased lymphocyte proliferation responses, demonstrated in the majority of patients (69%-100%). Other consistent findings include significant reduction of recent thymic emigrants, naive T and B cells, low or absent T-cell receptor excision circles (TREC) and restricted T-cell repertoire.^{20,36,59} Also, specific antibody deficiency has been reported in the majority of evaluated patients with CHH (7/8, 88%) and can be a marker of a more severe disease course.³⁶

Lower counts of total CD3 + T lymphocytes and of recent thymic immigrants in patients with more profound immunodeficiency have been observed.³⁶ However, reduced recent thymic immigrants can be seen in patients without significant clinical immunodeficiency.²⁵ Equivocal associations have also been reported between the severity of CHH and lymphocyte proliferative responses and other routine immunological laboratory indices.^{20,25,60-62}

To further complicate the interpretation of immunologic laboratory results in patients with CHH, consideration should be given to the fact that laboratory parameters can fluctuate significantly with time.^{20,63} This poses challenges to both management decisions and studies searching for prognostic correlates.

TABLE 2 Laboratory immunologic features in patients with cartilage-hair hypoplasia

Publication (reference)	N	Patient age, years	Immunoglobulin levels, N (%)	Cell counts, N (%)	Abnormal Ly responses to PHA, N (%)
Mäkitie 1993 ⁴	108	0.8-52	NA	Ly ↓ 51/79 (65)	53/60 (88)
Mäkitie 1998 ⁶²	35	0.1-55	Normal 16/16 (100)	Ly ↓ 12/33 (36) CD4+ ↓ 17/30 (57) CD8+ ↓ 8/30 (27) ↑ 1/30 (3) CD19+ ↓ 2/23 (9) ↑ 2/23 (9)	22/32 (69)
Mäkitie 2000 ⁶³	20	1.7-16	IgG ↓ 0/20 (0) ↑ 5/20 (25) IgM normal 20/20 (100) IgA deficiency 2/20 (10)	NA	NA
Hermanns 2006 ⁷¹	27	0.6-32	Ig-s ↓ 2/5 (40)	CD3+ ↓ 6/9 (67)	2/2 (100)
Kavadas 2008 ²⁰	12	0.2-6, 44	IgG ↓ 3/11 (27) ↑ 7/11 (64) IgM ↓ 1/11 (9) IgA deficiency 3/11 (27)	Ly ↓ 10/12 (83) CD3+ ↓ 12/12 (100) CD4+ ↓ 11/12 (92) CD8+ ↓ 12/12 (100) CD19+ ↓ 6/12 (50) NK ↓ 2/12 (17) TREC ↓ 4/5 (80)	11/11 (100)
Rider 2009 ⁶¹	25	0.8-21	IgG ↓ or ↑ in some IgM ↓ in some IgA deficiency 3/25 (12)	Ly ↓ in the majority	In most
Bordon 2010 ⁴²	16	0.7-19	IgG ↓ 5/16 (31) IgM ↓ 5/16 (31) IgA ↓ 8/16 (50)	Ly ↓ 15/16 (94) CD3+ ↓ 15/16 (94) CD4+ ↓ 15/16 (94) CD8+ ↓ 15/16 (94) CD19+ ↓ 12/16 (75) NK ↓ 2/13 (15)	14/15 (93)
de la Fuente 2011 ²⁵	18	1-21	Normal Ig-s 11/14 (79)	CD3+ ↓ 10/18 (56) CD4+ ↓ 18/18 (100) CD8+ ↓ 13/18 (72) CD19+ ↓ 8/18 (44) RTE ↓ 18/18 (100)	11/13 (85)
Ip 2015 ⁶⁰	13	0-9	IgG ↓ 4/12 (33) ↑ 2/12 (17) IgA ↓ 7/12 (58) IgM ↓ 5/12 (42)	CD4+ ↓ 13/13 (100) CD8+ ↓ 9/13 (69) CD19+ ↓ 5/13 (38) TREC ↓ 9/9 (100)	9/11 (82)
Kostjukovits 2017 ³⁷	56	0.7-68	IgG ↓ 1/50 (2) ↑ 2/50 (4) IgA ↓ 2/55 (4) IgM ↓ 7/55 (13)	Ly ↓ 31/56 (55) CD3+ ↓ 25/55 (45) ↑ 2/55 (4) CD4+ ↓ 24/55 (44) CD8+ ↓ 25/55 (45) ↑ 2/55 (4) CD19+ ↓ 37/55 (67) NK ↓ 4/55 (7) RTE ↓ 27/52 (52)	NA

Note: CD cluster of differentiation, CD19+ B cells, CD+ T cells, CD4+ helper T cells, CD8+ effector T cells, Ig immunoglobulin, Ly lymphocytes, N number of patients, NA not available, NK natural killer cells, PHA phytohemagglutinin, TREC T-cell receptor excision circles, ↓ decreased, ↑ increased.

3.6 | Disease course and mortality

Mortality rates are higher in patients with CHH compared with the general population. Standardized mortality rates of 7.0-9.3 in Finnish patients with CHH have been reported.^{5,44} The main causes of deaths include infections in childhood, malignancy in young adulthood and lung disease in adulthood.^{5,44}

Patients with variants other than n.71A > G may have a more severe immunologic phenotype, but this correlation has not been straightforward.^{20,36} Compound heterozygous duplications and triplications of *RMRP* have been correlated with the milder growth failure in CHH.^{20,58} However, even these patients with less severe short stature can exhibit severe immunodeficiency, and therefore, mild growth failure

should not provide a false sense of mild disease. On the other hand, severe short stature at birth (<-4.0 standard deviation) clearly correlates with early mortality in CHH.⁴⁴

Apart from severe short stature at birth, several other clinical features have been described as risk factors for mortality in CHH.⁴⁴ Severe disease course has been demonstrated in CHH patients with Hirschsprung disease, pneumonia in the first year of life or repeatedly in adulthood and autoimmune diseases in adulthood.^{44,64,65}

While immunological laboratory indices correlate poorly with clinical disease severity and prognosis in patients with CHH, categorization of subjects based on clinical features of immunodeficiency has been successfully implemented in the assessment of mortality risk in Finnish CHH cohort.⁴⁴ Patients can be categorized as follows: (a) asymptomatic group with no increased susceptibility to infections, (b) subjects with symptoms typical for humoral immunodeficiency (recurrent respiratory tract infections and/or sepsis), and (c) patients with clinical symptoms of combined immunodeficiency such as autoimmunity or opportunistic infections. During long-term follow-up, those belonging to the combined immunodeficiency group demonstrate significantly higher mortality, suggesting that a more aggressive treatment approach is justified in these patients. Validation of the reported clinical risk factors for mortality is needed to determine, whether they can be used to guide management decisions in patients outside the original Finnish cohort.

Immunodeficiency is progressive in CHH. A 30-year follow-up demonstrated that in 22% of patients, (17/79) clinical symptoms of immunodeficiency progressed with time.⁴⁴ These data highlight the importance of regular follow-up of asymptomatic or mildly symptomatic patients with CHH.

Variants in *RMRP* have also been described to cause a somewhat controversial disease entity—metaphyseal dysplasia without hypotrichosis (MDWH, OMIM #250460).⁶⁶ MDWH is characterized by the metaphyseal dysplasia identical to CHH, but in the absence of extra-skeletal manifestations like hypotrichosis or immunodeficiency. Recently, late-onset immunodeficiency and development of malignancies in adulthood have been demonstrated in patients with *RMRP* variants and MDWH features in childhood.⁶⁷ Interestingly, these subjects had less profound growth failure at birth. These findings suggest that MDWH represent cases of CHH with risk of late-onset complications and call for regular and careful follow-up of individuals with *RMRP* variants and isolated skeletal features.

4 | MANAGEMENT OF IMMUNODEFICIENCY IN CHH

All patients with CHH should be regularly assessed for the symptoms and signs of immunodeficiency. Management of

recurrent respiratory infections in CHH does not differ from other primary immunodeficiency disorders and includes prevention by immunizations (including pneumococcal and annual influenza vaccines), antibiotic prophylaxis or immunoglobulin replacement therapy in selected cases.

Given the high prevalence of pulmonary issues in CHH, regular lung function assessment and lung imaging should be considered, especially in symptomatic patients. Bronchiectasis should be diagnosed promptly and managed aggressively to prevent end-organ lung damage, which contributes significantly to mortality in adults with CHH. Treatment options for bronchiectasis include pulmonary rehabilitation and physiotherapy, as well as antibiotics, particularly macrolides.⁴⁶ Prolonged treatment with clarithromycin has resulted in the improvement of bronchiectasis in one child with CHH and lung disease.³⁸

Prevention of malignancy is crucial in CHH and should include common recommendations, such as sun protection, advice against smoking, minimizing radiation exposure from radiologic imaging, as well as encouragement of HPV immunizations. Screening for malignancy should be a routine in patients with CHH, including regular dermatologic examination for skin cancer, gynaecologic assessment and cervical cancer screening, as well as proper clinical, laboratory (at least complete blood count and sedimentation rate) and radiologic (abdominal ultrasound and other imaging as needed) evaluation for lymphoma.

Over 40 patients with CHH who had required haematopoietic stem cell transplantation (HSCT) have been reported, with follow-up of 0.75–20 years and with combined survival rate of 76% post-transplant.⁶⁵ Deaths are attributed mostly to infectious complications, but also to severe graft-versus-host disease.^{41,59,68} The majority of HSCT survivors restore normal immunity.^{41,59} HSCT can stabilize or improve pulmonary function and halt the progression of pre-existing bronchiectasis in CHH.⁴¹ HSCT can also correct the immune dysregulation, such as autoimmunity or inflammatory skin lesions.^{41,48} Also, in patients with primary immunodeficiency disorders, HSCT decreases the risk of malignancies, which is an important consideration in CHH.⁶⁹

While HSCT is a straightforward choice in CHH patients with severe combined immunodeficiency or persistent transfusion-dependent anaemia, in the remaining majority of subjects, the indications for HSCT are not so clear-cut. HSCT should be considered on an individual basis in CHH, and ideally should be performed before the development of severe opportunistic infections, significant organ damage or malignancy. Laboratory parameters correlate poorly with the disease course in CHH^{36,44}; therefore, with the exception of individuals fulfilling the criteria for severe combined immunodeficiency, the selection of patients who would benefit from HSCT based solely on routinely available laboratory parameters is

problematic. However, newborn screening for severe combined immunodeficiency identifies patients with CHH and may guide early management. TREC counts measured in the newborn screening have been previously assessed in patients with CHH of various age and shown to be low or absent in all evaluated subjects.^{20,59} Recently, in a small study, TREC counts obtained via newborn screening in eight CHH patients correlated with clinical severity and various immunologic laboratory parameters.⁶⁵ If these findings are confirmed in larger studies with longer follow-up period, TREC counts may become the most important prognostic indicator in CHH.

Patients with CHH can present with variable clinical features, and the spectrum of manifestations include orthopaedic, infectious, haematologic, pulmonary, gastrointestinal, endocrinologic, gynaecologic, as well as rehabilitation issues. Therefore, a multidisciplinary team should provide care for patients with CHH, to ensure timely and accurate evaluation, therapy and follow-up.

5 | CONCLUSIONS AND FUTURE PROSPECTS

Cartilage-hair hypoplasia is a syndromic primary immunodeficiency disorder with complex pathogenesis and variable clinical course. Recent advances have shed light on the mechanisms underlying immunodeficiency in CHH, such as cell cycle disturbances, impaired telomere maintenance and altered gene regulation. However, further research is needed to explain the variability of clinical and laboratory features, as well as differences in the clinical course and mortality among patients with CHH. With the rapid development of small-molecule therapeutics and gene-editing technologies, potential molecular targets and the possibility of gene therapy should be explored in CHH. Clinical guidelines for the management of CHH should be developed to optimize patient care.

CONFLICT OF INTEREST

The authors have no conflict of interest to declare.

AUTHOR CONTRIBUTIONS

SV performed literature search and drafted the manuscript, SV, MT and OM finalized the review.

ORCID

Svetlana Vakkilainen  <https://orcid.org/0000-0002-4573-3297>

REFERENCES

1. Maroteaux SP, Savart P, Lefebvre J, et al. Les formes partielles de la dysostose metaphysaire. *Presse Med.* 1983;1963(30):1523-1526.
2. McKusick VA, Eldridge R, Hostetler JA, et al. DWARFISM IN THE AMISH. II. CARTILAGE-HAIR HYPOPLASIA. *Bull Johns Hopkins Hosp.* 1965;116:285-326.
3. Makitie O. Cartilage-hair hypoplasia in Finland: epidemiological and genetic aspects of 107 patients. *J Med Genet.* 1992;29(9):652-655.
4. Makitie O, Kaitila I. Cartilage-hair hypoplasia—clinical manifestations in 108 Finnish patients. *Eur J Pediatr.* 1993;152(3):211-217.
5. Makitie O, Pukkala E, Kaitila I. Increased mortality in cartilage-hair hypoplasia. *Arch Dis Child.* 2001;84(1):65-67.
6. Williams MS, Ettinger RS, Hermanns P, et al. The natural history of severe anemia in cartilage-hair hypoplasia. *Am J Med Genet A.* 2005;138(1):35-40.
7. Taskinen M, Ranki A, Pukkala E, et al. Extended follow-up of the Finnish cartilage-hair hypoplasia cohort confirms high incidence of non-Hodgkin lymphoma and basal cell carcinoma. *Am J Med Genet A.* 2008;146a(18):2370-2375.
8. Ridanpaa M, van Eenennaam H, Pelin K, et al. Mutations in the RNA component of RNase MRP cause a pleiotropic human disease, cartilage-hair hypoplasia. *Cell.* 2001;104(2):195-203.
9. Thiel CT, Horn D, Zabel B, et al. Severely incapacitating mutations in patients with extreme short stature identify RNA-processing endoribonuclease RMRP as an essential cell growth regulator. *Am J Hum Genet.* 2005;77(5):795-806.
10. Vakkilainen S, Skoog T, Einarsdottir E, et al. The human long non-coding RNA gene RMRP has pleiotropic effects and regulates cell-cycle progression at G2. *Sci Rep.* 2019;9(1):13758.
11. Hermanns P, Bertuch AA, Bertin TK, et al. Consequences of mutations in the non-coding RMRP RNA in cartilage-hair hypoplasia. *Hum Mol Genet.* 2005;14(23):3723-3740.
12. Mattijssen S, Welting TJ, Pruijn GJ. RNase MRP and disease. *Wiley interdiscip rev.* 2010;1(1):102-116.
13. Welting TJ, van Venrooij WJ, Pruijn GJ. Mutual interactions between subunits of the human RNase MRP ribonucleoprotein complex. *Nucleic Acids Res.* 2004;32(7):2138-2146.
14. Sun X, Zhang R, Liu M, et al. Rmrp mutation disrupts chondrogenesis and bone ossification in zebrafish model of cartilage-hair hypoplasia via enhanced Wnt/ β -catenin signaling. *J Bone Miner Res.* 2019;34(11):2101-2116.
15. Ridanpaa M, Sistonen P, Rockas S, et al. Worldwide mutation spectrum in cartilage-hair hypoplasia: ancient founder origin of the major 70A→G mutation of the untranslated RMRP. *Eur J Hum Genet.* 2002;10(7):439-447.
16. Hirose Y, Nakashima E, Ohashi H, et al. Identification of novel RMRP mutations and specific founder haplotypes in Japanese patients with cartilage-hair hypoplasia. *J Hum Genet.* 2006;51(8):706-710.
17. Gomes ME, Calatrava Paternostro L, Moura VR, et al. Identification of novel and recurrent RMRP variants in a series of Brazilian patients with cartilage-hair hypoplasia: McKusick Syndrome. *Mol Syndromol.* 2020;10(5):255-263.
18. Taskinen M, Mäkitie O. Cartilage-hair hypoplasia—much more than growth problem. *Duodecim.* 2011;127(3):273-279.
19. Nakashima E, Tran JR, Welting TJ, et al. Cartilage hair hypoplasia mutations that lead to RMRP promoter inefficiency or RNA transcript instability. *Am J Med Genet A.* 2007;143a(22):2675-2681.
20. Welting TJ, Mattijssen S, Peters FM, et al. Cartilage-hair hypoplasia-associated mutations in the RNase MRP P3 domain affect RNA folding and ribonucleoprotein assembly. *Biochim Biophys Acta.* 2008;1783(3):455-466.

21. Kavadas FD, Giliiani S, Gu Y, et al. Variability of clinical and laboratory features among patients with ribonuclease mitochondrial RNA processing endoribonuclease gene mutations. *J Allergy Clin Immunol.* 2008;122(6):1178-1184.
22. Glazov EA, Zankl A, Donskoi M, et al. Whole-exome re-sequencing in a family quartet identifies POP1 mutations as the cause of a novel skeletal dysplasia. *PLoS Genet.* 2011;7(3):e1002027.
23. Narayanan DL, Shukla A, Kausthubham N, et al. An emerging ribosomopathy affecting the skeleton due to biallelic variations in NEPRO. *Am J Med Genet A.* 2019;179(9):1709-1717.
24. Rogler LE, Kosmyrna B, Moskowitz D, et al. Small RNAs derived from lncRNA RNase MRP have gene-silencing activity relevant to human cartilage-hair hypoplasia. *Hum Mol Genet.* 2014;23(2):368-382.
25. Juvonen E, Makitie O, Makiperna A, et al. Defective in-vitro colony formation of haematopoietic progenitors in patients with cartilage-hair hypoplasia and history of anaemia. *Eur J Pediatr.* 1995;154(1):30-34.
26. de la Fuente MA, Recher M, Rider NL, et al. Reduced thymic output, cell cycle abnormalities, and increased apoptosis of T lymphocytes in patients with cartilage-hair hypoplasia. *J Allergy Clin Immunol.* 2011;128(1):139-146.
27. Goldfarb KC, Cech TR. Targeted CRISPR disruption reveals a role for RNase MRP RNA in human preribosomal RNA processing. *Genes Dev.* 2017;31(1):59-71.
28. Harley CB, Futcher AB, Greider CW. Telomeres shorten during ageing of human fibroblasts. *Nature.* 1990;345(6274):458-460.
29. Morin GB. The human telomere terminal transferase enzyme is a ribonucleoprotein that synthesizes TTAGGG repeats. *Cell.* 1989;59(3):521-529.
30. Bertuch AA. The molecular genetics of the telomere biology disorders. *RNA Biol.* 2016;13(8):696-706.
31. Maida Y, Yasukawa M, Furuuchi M, et al. An RNA-dependent RNA polymerase formed by TERT and the RMRP RNA. *Nature.* 2009;461(7261):230-235.
32. Kostjukovits S, Degerman S, Pekkinen M, et al. Decreased telomere length in children with cartilage-hair hypoplasia. *J Med Genet.* 2017;54(5):365-370.
33. Aubert G, Strauss KA, Lansdorp PM, et al. Defects in lymphocyte telomere homeostasis contribute to cellular immune phenotype in patients with cartilage-hair hypoplasia. *J Allergy Clin Immunol.* 2017;140(4):1120-1129.e1121.
34. Vulliamy T, Marrone A, Goldman F, et al. The RNA component of telomerase is mutated in autosomal dominant dyskeratosis congenita. *Nature.* 2001;413(6854):432-435.
35. Savage SA. Dyskeratosis congenita. In: Adam MP, Ardinger HH, Pagon RA, et al., *GeneReviews((R))*. Seattle, WA: University of Washington, Seattle. GeneReviews is a registered trademark of the University of Washington, Seattle. All rights reserved; 1993.
36. Alder JK, Hanumanthu VS, Strong MA, et al. Diagnostic utility of telomere length testing in a hospital-based setting. *Proc Natl Acad Sci USA.* 2018;115(10):E2358-E2365.
37. Wagner CL, Hanumanthu VS, Talbot CC Jr, et al. Short telomere syndromes cause a primary T cell immunodeficiency. *J Clin Invest.* 2018;128(12):5222-5234.
38. Kostjukovits S, Klemetti P, Valta H, et al. Analysis of clinical and immunologic phenotype in a large cohort of children and adults with cartilage-hair hypoplasia. *J Allergy Clin Immunol.* 2017;140(2):612-614.e615.
39. Rosenbluh J, Nijhawan D, Chen Z, et al. RMRP is a non-coding RNA essential for early murine development. *PLoS One.* 2011;6(10):e26270.
40. Bailly-Botuha C, Jaubert F, Taam RA, et al. Diffuse lymphoplasmacytic bronchiolitis in cartilage-hair hypoplasia. *J Pediatr.* 2008;152(3):429-433.
41. Horn J, Schlesier M, Warnatz K, et al. Fatal adult-onset antibody deficiency syndrome in a patient with cartilage hair hypoplasia. *Hum Immunol.* 2010;71(9):916-919.
42. Kostjukovits S, Klemetti P, Fohr A, et al. High prevalence of bronchiectasis in patients with cartilage-hair hypoplasia. *J Allergy Clin Immunol.* 2017;139(1):375-378.
43. Bordon V, Gennery AR, Slatter MA, et al. Clinical and immunologic outcome of patients with cartilage hair hypoplasia after hematopoietic stem cell transplantation. *Blood.* 2010;116(1):27-35.
44. Toiviainen-Salo S, Kajosaari M, Piilonen A, et al. Patients with cartilage-hair hypoplasia have an increased risk for bronchiectasis. *J Pediatr.* 2008;152(3):422-428.
45. Daheshia M, Pahl JD, Carmichael JJ, et al. The immune response and its therapeutic modulation in bronchiectasis. *Pulm Med.* 2012;2012:1-7.
46. Vakkilainen S, Taskinen M, Klemetti P, et al. A 30-year prospective follow-up study reveals risk factors for early death in cartilage-hair hypoplasia. *Front Immunol.* 2019;10:1581.
47. Kotaniemi JT, Pallasaho P, Sovijarvi AR, et al. Respiratory symptoms and asthma in relation to cold climate, inhaled allergens, and irritants: a comparison between northern and southern Finland. *J Asthma.* 2002;39(7):649-658.
48. Chang AB, Bush A, Grimwood K. Bronchiectasis in children: diagnosis and treatment. *Lancet (London, England).* 2018;392(10150):866-879.
49. Vakkilainen S, Makitie R, Klemetti P, et al. A wide spectrum of autoimmune manifestations and other symptoms suggesting immune dysregulation in patients with cartilage-hair hypoplasia. *Front Immunol.* 2018;9:2468.
50. Moshous D, Meyts I, Fraitag S, et al. Granulomatous inflammation in cartilage-hair hypoplasia: risks and benefits of anti-TNF-alpha mAbs. *J Allergy Clin Immunol.* 2011;128(4):847-853.
51. Buchbinder D, Hauck F, Albert MH, et al. Rubella virus-associated cutaneous granulomatous disease: a unique complication in immune-deficient patients, not limited to DNA repair disorders. *J Clin Immunol.* 2019;39(1):81-89.
52. Taskinen M, Jeskanen L, Karjalainen-Lindsberg ML, et al. Combating cancer predisposition in association with idiopathic immune deficiency: a recurrent nodal and cutaneous T-cell lymphoproliferative disease in a patient with cartilage-hair hypoplasia. *Clin Lymph Myelom Leuk.* 2013;13(1):73-76.
53. Sathishkumar D, Gach JE, Ogboli M, et al. Cartilage hair hypoplasia with cutaneous lymphomatoid granulomatosis. *Clin Exp Dermatol.* 2018;43(6):713-717.
54. Biggs CM, Kostjukovits S, Dobbs K, et al. Diverse autoantibody reactivity in cartilage-hair hypoplasia. *J Clin Immunol.* 2017;37(6):508-510.
55. Poliani PL, Facchetti F, Ravanini M, et al. Early defects in human T-cell development severely affect distribution and maturation of thymic stromal cells: possible implications for the pathophysiology of Omenn syndrome. *Blood.* 2009;114(1):105-108.
56. Nguyen A, Martin Silva N, de Boysson H, et al. Diffuse large B-cell lymphoma chemotherapy reveals a combined

- immunodeficiency syndrome in cartilage hair hypoplasia. *Swiss Med Wkly*. 2018;148:w14606.
57. Hauck F, Voss R, Urban C, et al. Intrinsic and extrinsic causes of malignancies in patients with primary immunodeficiency disorders. *J Allergy Clin Immunol*. 2018;141(1):59-68.e54.
58. Verhoeven D, Stoppelenburg AJ, Meyer-Wentrup F, et al. Increased risk of hematologic malignancies in primary immunodeficiency disorders: opportunities for immunotherapy. *Clin Immunol (Orlando, Fla)*. 2018;190:22-31.
59. Holopainen E, Vakkilainen S, Mäkitie O. Gynecologic assessment of 19 adult females with cartilage-hair hypoplasia - high rate of HPV positivity. *Orphanet J Rare Dis*. 2018;13(1):207.
60. Klemetti P, Valta H, Kostjukovits S, et al. Cartilage-hair hypoplasia with normal height in childhood-4 patients with a unique genotype. *Clin Genet*. 2017;92(2):204-207.
61. Ip W, Gaspar HB, Kleta R, et al. Variable phenotype of severe immunodeficiencies associated with RMRP gene mutations. *J Clin Immunol*. 2015;35(2):147-157.
62. Rider NL, Morton DH, Puffenberger E, et al. Immunologic and clinical features of 25 Amish patients with RMRP 70 A->G cartilage hair hypoplasia. *Clin Immunol (Orlando, Fla)*. 2009;131(1):119-128.
63. Mäkitie O, Kaitila I, Savilahti E. Susceptibility to infections and in vitro immune functions in cartilage-hair hypoplasia. *Eur J Pediatr*. 1998;157(10):816-820.
64. Mäkitie O, Kaitila I, Savilahti E. Deficiency of humoral immunity in cartilage-hair hypoplasia. *J Pediatr*. 2000;137(4):487-492.
65. Kainulainen L, Lassila O, Ruuskanen O. Cartilage-hair hypoplasia: follow-up of immunodeficiency in two patients. *J Clin Immunol*. 2014;34(2):256-259.
66. Mäkitie O, Heikkinen M, Kaitila I, et al. Hirschsprung's disease in cartilage-hair hypoplasia has poor prognosis. *J Pediatr Surg*. 2002;37(11):1585-1588.
67. Scott EM, Chandra S, Li J, et al. Abnormal Newborn screening follow-up for severe combined immunodeficiency in an amish cohort with cartilage-hair hypoplasia. *J Clin Immunol*. 2020;40(2):321-328.
68. Bonafe L, Schmitt K, Eich G, et al. RMRP gene sequence analysis confirms a cartilage-hair hypoplasia variant with only skeletal manifestations and reveals a high density of single-nucleotide polymorphisms. *Clin Genet*. 2002;61(2):146-151.
69. Vakkilainen S, Costantini A, Taskinen M, et al. 'Metaphyseal dysplasia without hypotrichosis' can present with late-onset extraskel-etal manifestations. *J Med Genet*. 2020;57(1):18-22.
70. Faitelson Y, Manson D. Cartilage-hair hypoplasia: a spectrum of clinical and radiological findings. *LymphoSign J*. 2015;2(3):157-164.
71. Kamani NR, Kumar S, Hassebroek A, et al. Malignancies after hematopoietic cell transplantation for primary immune deficiencies: a report from the Center for International Blood and Marrow Transplant Research. *Biol Blood Marrow Transplant*. 2011;17(12):1783-1789.
72. Hermanns P, Tran A, Munivez E, et al. RMRP mutations in cartilage-hair hypoplasia. *Am J Med Genet A*. 2006;140(19):2121-2130.

How to cite this article: Vakkilainen S, Taskinen M, Mäkitie O. Immunodeficiency in cartilage-hair hypoplasia: Pathogenesis, clinical course and management. *Scand J Immunol*. 2020;92:e12913. <https://doi.org/10.1111/sji.12913>